

Ultrasound-Assisted Endoscopic Removal of Pretibial Cysts Related to Biointerference Screw Degradation



Eirik Solheim, M.D., Ph.D., and Eivind Inderhaug, M.D., Ph.D.

Abstract: We report on the treatment of cases of painful subcutaneous pretibial cyst due to broken and displaced materials of only partly absorbed bioabsorbable interference screws used for anterior cruciate ligament reconstruction. Ultrasound examination was used to both make the definite diagnosis and determine the exact localization of dislodged screw parts. The broken and loose bioabsorbable screw parts and surrounding cyst-like structure were removed endoscopically by a soft-tissue resector.

The use of bioabsorbable interference screw fixation is well established in anterior cruciate ligament reconstruction (ACLR). It offers potential benefits over metallic interference screws by degradation and replacement by bone.¹ Further, in postoperative magnetic resonance imaging (MRI) scans, metallic artifacts are eliminated. Finally, revision surgery can ideally be performed without any hardware removal.² However, reports dispute that (complete) bony integration is generally taking place.^{3,4} Further, cases of painful pretibial cysts have been reported.⁵

Such cysts typically are diagnosed by MRI scans, and the cyst and screw remnants are traditionally removed by open extirpation.³ We report on the use of ultrasound (US) examination for diagnosing painful late tibial cyst formation, the precise perioperative localization of screw remnants by US, and the endoscopic removal of the screw remnants along with the surrounding cyst (by ordinary arthroscopic equipment).

From the Department of Orthopedics, Aleris Nestun Hospital; and Department of Clinical Medicine, Faculty of Medicine and Dentistry, University of Bergen, Bergen, Norway.

The authors report that they have no conflicts of interest in the authorship and publication of this article. Full ICMJE author disclosure forms are available for this article online, as [supplementary material](#).

Received November 17, 2020; accepted January 29, 2021.

Address correspondence to Eivind Inderhaug, M.D., Ph.D., Department of Orthopaedics, Deaconess University Hospital, Haralds plass, NO 5009 Bergen, Norway. E-mail: eivind.inderhaug@gmail.com

© 2021 by the Arthroscopy Association of North America. Published by Elsevier. This is an open access article under the CC BY-NC-ND license (<http://creativecommons.org/licenses/by-nc-nd/4.0/>).

2212-6287/201868

<https://doi.org/10.1016/j.eats.2021.01.027>

Technical Note

Indications, Patient Evaluation, and Imaging

Recently, we have seen 2 female patients in their late forties who previously had undergone an ACLR using a hamstring autograft. The autograft had been fixed by an ENDOBUTTON in the femur and a (9 × 30-mm) BIOSURE HA interference screw (Smith & Nephew Inc, Andover, MA) in the tibia. The material of the screw consists of 75% poly-L-lactic acid (PLLA) and 25% hydroxyapatite (HA). The rehabilitation was non-eventful, and the patients were satisfied with the outcome. However, 3 to 5 years after ACLR surgery, both patients observed a painful swelling below the knee, particularly bothersome when kneeling/resting on the knee. Radiographic examinations ordered by their family physicians were inconclusive. The patients were referred to us.

Clinical examination showed normal range of movement, negative Lachman test, and negative pivot shift test. US examination with a high-resolution linear array transducer revealed that the PLLA-HA tibial screw was largely unresorbed and broken/fractured, and that parts of the screw were dislodged out of the tunnel and had provoked a surrounding cyst communicating with the canal (Figs 1-2). We then proceeded to remove the cyst and loose screw remnants with an endoscopic technique as described herein.

Surgical Technique (With Video Illustration)

The localization of the broken screw remnants and surrounding cyst is determined by US examination with a high-resolution linear array transducer and marked on the skin by a waterproof marker (Fig 3). For even more improved guiding for the endoscopy, a needle can

be temporarily placed into the center of the cyst (during the US examination). The incision for the (4-mm, 30°) arthroscope is made 2 to 3 cm below the screw head, and the incision for the soft-tissue resector (3.5-mm DYONICS INCISOR; Smith & Nephew) 2 to 3 cm laterally, easing triangulation technique (Fig 3).

A cautious minimal subcutaneous debridement is made with the resector (in oscillation mode) toward the cyst wall (Video 1). In the soft tissue surrounding the cyst wall, countless powder-like polymer particles are found and should be removed as completely as possible with use of the resector (Fig 4). To avoid harming the dermis, the shaver blade opening should be facing downwards most of the time.

The cyst wall (capsule) is seen as a fluctuating yellowish structure bulging above the surrounding bone surface and wider than the underlying bone canal (Fig 5). The cyst is opened by penetrating the cyst wall by the shaver. The cyst sack is checked for content, i.e., fluid and partly absorbed/fragmented screw remnants (Fig 6). The fluid and smaller particles will be rapidly drawn into the shaver. Thus, it is wise to move slowly and having the shaver handle partly closed (for fluid inflow) to get a full overview of the situation, especially if planning to capture arthroscopic images.

The thick-walled cyst is then gradually removed by the oscillating shaver, starting from the top and moving gradually toward the base (Fig 7, Video 1). Alternatively, a large basket punch, e.g., the ACUFEX oval punch (Smith & Nephew), may be used for removing the cyst wall. Larger pieces, especially inside the tunnel,

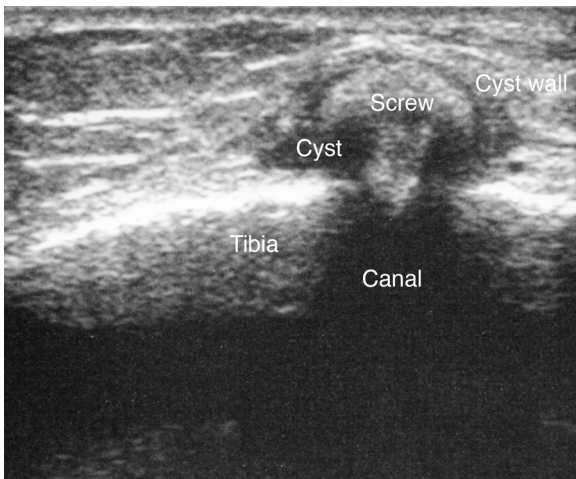


Fig 1. Ultrasound image of the proximal tibia in a patient approximately 3 years after an anterior cruciate ligament reconstruction using a hamstrings graft fixed distally with a bioabsorbable interference screw (BIOSURE, 9 × 30 mm) in the bone canal. The transducer is placed vertically on tibia, centred on the painful swelling. The head of the bioabsorbable interference screw (BIOSURE, 9 × 30 mm) has broken off of the rest of screw and been dislodged out of the canal. The head is situated inside a cyst-like structure.

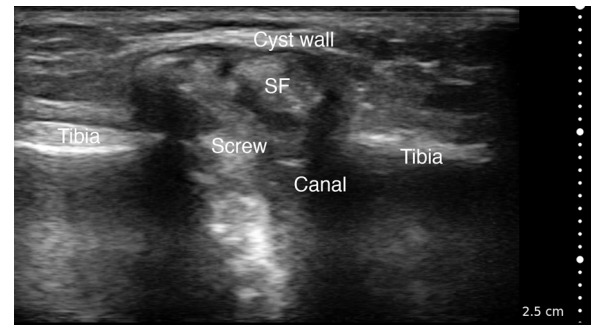


Fig 2. Ultrasound image of the proximal tibia in another patient having undergone the same procedure as the patient in Figure 1, only 5 years earlier (using the same implant, a BIOSURE 9 × 30 mm). The transducer is placed vertically on tibia, centred on the painful swelling. The bioabsorbable interference screw (Screw) is partly absorbed and broken into at least 4 screw fragments (SF). The head outside the canal is surrounded by a cyst-like structure with a well-defined cyst wall.

will generally stay in place during the cyst removal, even if partly fractured/dislodged.

It may be tempting to introduce a (straight Kocher's toothed) clamp to remove larger pieces, e.g., a fractured screwhead (Fig 8). However, the material (of a partly absorbed PLLA-HA screw) is very brittle, and the piece tends to burst into many smaller pieces if grasped with a clamp (Fig 9, Video 1). Thus, while generally not suitable for removing pieces, this type of instrument may be used for making larger pieces smaller and easier to remove by the shaver.

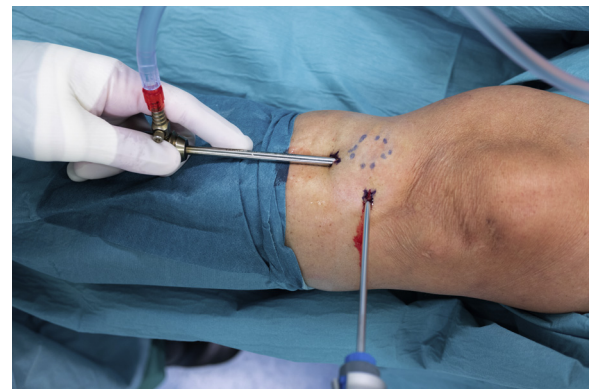

Fig 3. Perioperative image of the left knee of a patient about to undergo an endoscopic removal of a tibial cyst and the contained resorbable screw remnants. The localization of the broken head and the surrounding cyst has been determined by ultrasound examination. The cyst has been marked on the skin by a waterproof marker (dotted line circle). The broken screw head is situated in the center of the marked circle. The arthroscope cannula enters the cyst area from a small incision 2-3 centimetres below the screw head. The 3.5-mm soft-tissue resector enters the same area from an incision 2-3 cm laterally to the screw head.

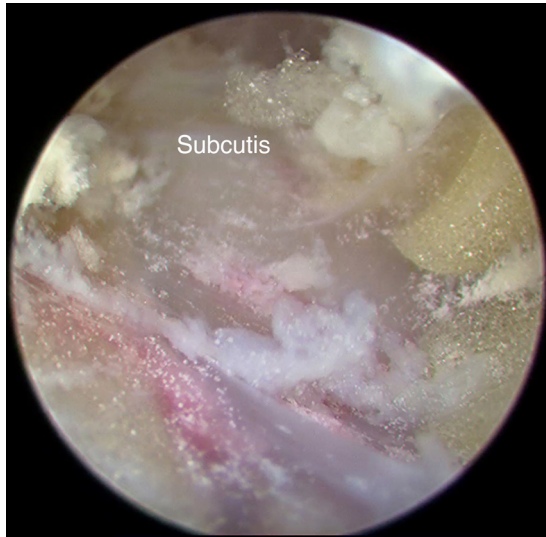

Fig 4. Endoscopic image of the subcutis overlying and surrounding a tibial cyst caused by a partly absorbed interference screw made of poly-L-lactic acid and hydroxyapatite. Myriads of small, whiteish powder-like particles of the partly absorbed interference screw are seen in the soft tissue.

The softness and fragility of the material of the partly absorbed interference screw make it easy to remove the loose pieces with an aggressive soft-tissue resector. When the cyst and contained screw fragment have been removed, the canal should be examined for loose screw fragments (Fig 10). Loose fragments within the canal are removed by the soft tissue resector placed into the canal (Fig 11). Be prepared to move the resector out of the canal to get a visualization of the effect every few

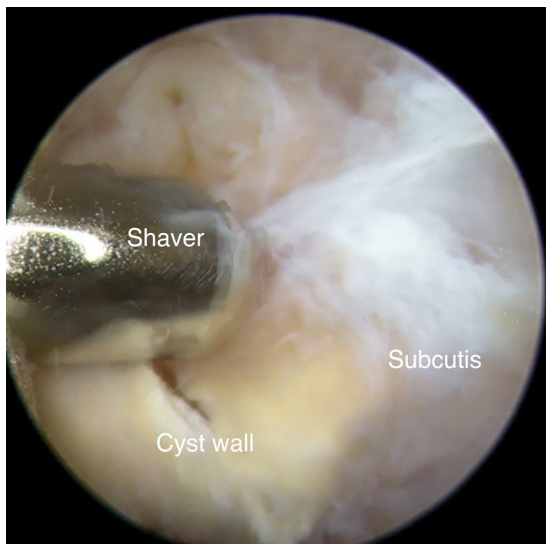


Fig 5. A 3.5-mm soft-tissue resector (Shaver) is used to dissect through the subcutis toward the tibial cyst. The cyst wall (capsule) is seen as a fluctuating yellowish structure bulging above the surrounding bone surface and is wider than the underlying bone canal.

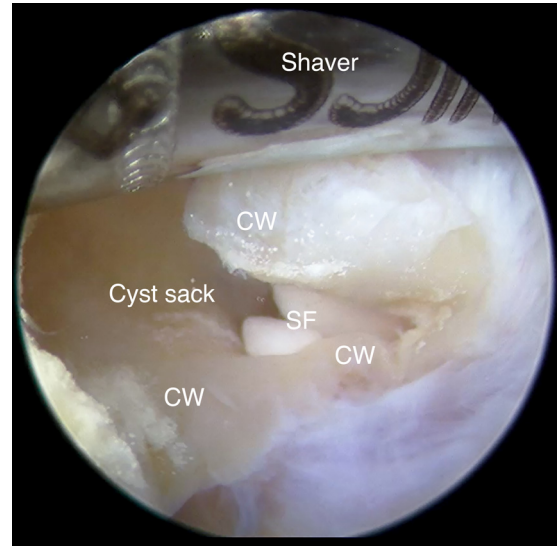


Fig 6. The cyst is opened by penetrating the cyst wall (CW) with the oscillating shaver. The cyst sack is checked for content, i.e., fluid and screw fragments (SF). The fluid and smaller particles/fragments will be rapidly drawn into the shaver and the shaver should be turned off during the first inspection of the cyst.

seconds (as the shaver will effectively block the vision to the inside).

We recommend removing all loose fragments, but not to remove larger deeper parts of the screw that seem relatively intact and still fixed/stuck inside the canal. The inside of the canal is covered with a thin layer of soft tissue and we have not observed sign of bony ingrowth into the screw (remnants) (Fig 12).

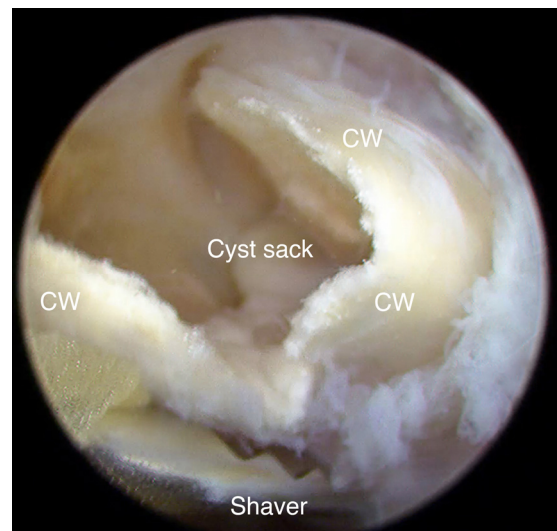


Fig 7. The cyst wall (CW) is thick, but easily removed with a 3.5-mm (aggressive) shaver starting from the top and moving gradually toward the base of the cyst. For best effect of the shaver, the cyst wall is trapped against the underlying bone by a light pressure (downwards) while the shaver oscillates.

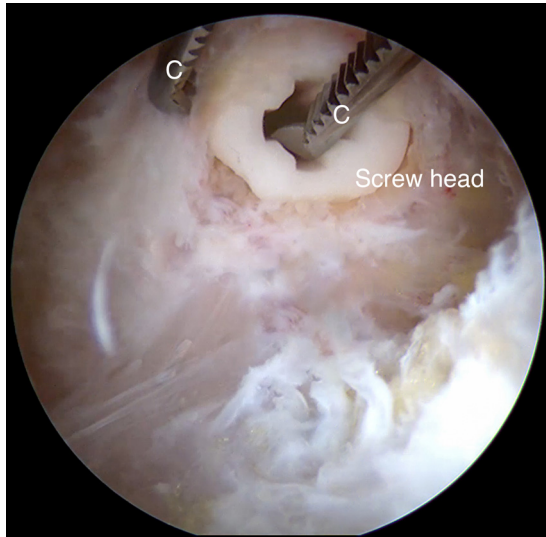


Fig 8. The capsule surrounding the fractured and dislodged screw head of a 9 × 30-mm BIOSURE interference screw has been removed by a small tissue resector. A straight Kocher's toothed clamp (C) has been introduced with the intent to remove the loose screw head in one piece. However, the material is brittle and fragile and tends to fracture as seen in the next figure (Fig 9).

Discussion

US examination is ideal for diagnosing cysts⁶ and localizing radiolucent foreign bodies⁷ and was used both diagnostically and as a perioperative aid for localizing screw remnants in the present cases. We have found that both the cyst and remaining soft biomaterial parts are easily removed endoscopically by a shaver,

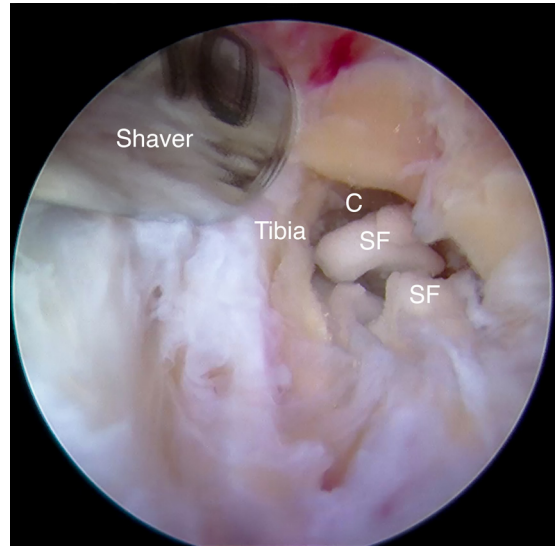


Fig 10. The cyst and contained screw head fragments have been removed, and the canal (C) is examined for loose screw fragments (SF).

similarly as in the technique used for prepatellar chronic bursitis.⁸

Bioabsorbable implants, including PLLA-HA interference screws used in ACLR, are oftentimes marketed as being absorbed and replaced by bone tissue within a few years after insertion into bone. However, often this does not happen,⁴ and cases of breakage, migration, and cyst formation have been reported.⁹ Although generally considered biocompatible, some studies have

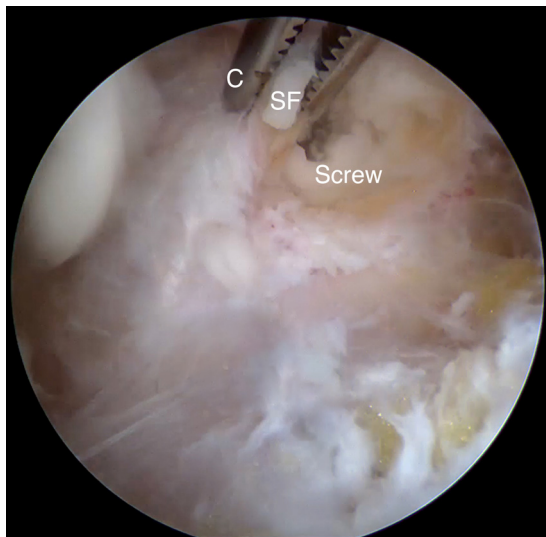


Fig 9. Endoscopic image captured within 2 seconds of that in the previous Figure 8. As the Kocher clamp (C) grasps the screw head it bursts (in an explosive manner) into many small screw fragments (SF). The smaller pieces were later removed with a small (3.5 mm) soft-tissue resector.

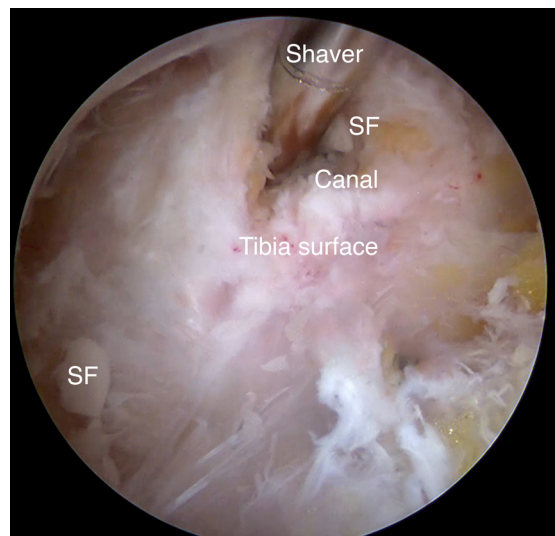


Fig 11. A small (3.5-mm) soft-tissue resector (shaver) is used for removing all loose screw fragments (SF) within the canal. The image shows the shaver tip inside the tunnel. For best visualization, the shaver should be pulled out of the canal every few seconds as the shaver blocks most of the vision to the inside of the canal.

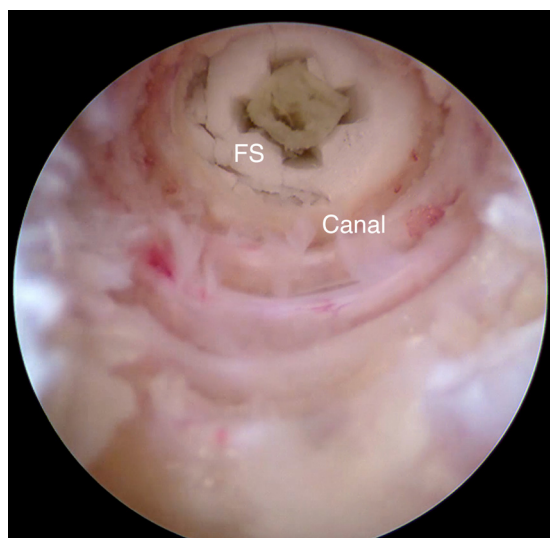


Fig 12. Endoscopic image into the canal after most fractured and partly absorbed screw material has been removed with the shaver. The remaining part of the screw seen in the end of the canal is fractured (FS) but otherwise largely intact and stable. The wall of the tunnel is covered with fibrous tissue and probably includes the distal end of the anterior cruciate ligament graft. There is no sign of bony ingrowth.

found chronic inflammation with foreign-body reaction, aseptic cysts and sinuses, and inhibition of bone formation by poly-(lactic acid).¹⁰

Thompson et al.¹¹ followed the natural history of PLLA biodegradable screws by serial MRI scans in a group of 10 patients up to 16 years after ACLR. Although they were claimed to be absorbed and replaced by bone within 2 years, the authors found that the process was much slower. Although bone formation was reported in the majority of patients, it was only evident from the 7-year follow-up and onwards. Three of 10 patients experienced cyst formation, 2 of which resolved at the 10-year follow-up, whereas the final persisted until the 16-year follow-up. Sprowson et al.¹² performed a similar repeat MRI study in 10 patients up to 10 years after ACLR. They found no signs

Table 1. Advantages and Disadvantages

Advantages	Disadvantages
US show translucent objects not visible on radiographs and may be used in the operating theater, even during surgery if draped sterilely	Not all orthopaedic surgeons are proficient in using US
US is ideal for diagnosing and locating foreign bodies and cysts in real time	Contrary to MRI, US is less ideal for diagnosing intraarticular pathology
Endoscopic removal of cyst and foreign body is less invasive than an open procedure	It is more technical demanding and a possibly more costly procedure

MRI, magnetic resonance imaging; US, ultrasound.

Table 2. Pearls and Pitfalls

Pearls	Pitfalls
US allows exact localization of cyst and contained screw remnants and marking it on the skin	The endoscopic procedure should take place in the same degree of flexion so that the marked position does not shift
Endoscopic debridement with a shaver is ideal for removing both small powder-like particles and larger particles	Aggressive debridement without good visualization, especially if the shaver blade mouth is fazing upwards may harm the skin (cutis)
A surgical clamp (e.g., a Kocher) may be used for crushing larger pieces into smaller that are more easily removed by the shaver	A clamp should be used cautiously for removing larger pieces, as they are brittle and tend to burst into many small ones that may be difficult to find

US, ultrasound.

of resorption at the 4-year follow-up but a complete resorption at the final follow-up. No pretibial cysts were found, but graft tunnel fluid formation (often late) was seen in more than one half of patients. Recently, Sundaraj et al. reported in 20 patients in whom that the PLLA-HA screws (in the tibia) were largely resorbed by 13 years (but not at 5 years) and that the canal volume remained unchanged (and not replaced by bone).⁴

A Cochrane report from Debieux et al.¹³ compared results after ACLR across 12 randomized trials comparing bioabsorbable screws with metallic interference screws. Treatment failure was reported as either implant breakage during surgery or post-operative complications such as implant failure, graft failure, foreign body reaction, effusion, or arthrofibrosis. The study suggested a lower failure rate (relative risk 1.94) with metallic screws but no significant difference in activity level between groups at 12 and 24 months after surgery. Only 1 of 12 studies reported on cyst formation (in 1 of 197 patients), making it a rare event.

In conclusion, we have found US examination to be convenient and precise both for making the definite diagnosis of tibial cyst formation after the use of resorbable interference screw in ACLR and for exact perioperative localization of dislodged screw parts (and surrounding cyst). Further, the broken and loose bioabsorbable screw remnants and surrounding cyst may be endoscopically removed in a precise way with little tissue trauma. The most important advantages and disadvantages, and pearls and pitfalls are described in Tables 1 and 2, respectively.

References

1. Radford MJ, Noakes J, Read J, Wood DG. The natural history of a bioabsorbable interference screw used for anterior cruciate ligament reconstruction with a

- 4-strand hamstring technique. *Arthroscopy* 2005;21:707-710.
2. Osti L, Buda M, Osti R, Massari L, Maffulli N. Preoperative planning for ACL revision surgery. *Sports Med Arthrosc Rev* 2017;25:19-29.
 3. Chevallier R, Klouche S, Gerometta A, Bohu Y, Herman S, Lefevre N. Bioabsorbable screws, whatever the composition, can result in symptomatic intra-osseous tibial tunnel cysts after ACL reconstruction. *Knee Surg Sports Traumatol Arthrosc* 2019;27:76-85.
 4. Sundaraj K, Salmon LJ, Heath EL, et al. Bioabsorbable versus titanium screws in anterior cruciate ligament reconstruction using hamstring autograft: A prospective, randomized controlled trial with 13-year follow-up. *Am J Sports Med* 2020;48:1316-1326.
 5. Shen MX, Sathappan SS. Painful pretibial pseudocyst at bioabsorbable interference screw aperture two years after anterior cruciate ligament reconstruction. *Singapore Med J* 2013;54:e211-e214.
 6. Sconfienza LM, Albano D, Allen G, et al. Clinical indications for musculoskeletal ultrasound updated in 2017 by European Society of Musculoskeletal Radiology (ESSR) consensus. *Eur Radiol* 2018;28:5338-5351.
 7. Tantray MD, Rather A, Manaam Q, Andleeb I, Mohammad M, Gull Y. Role of ultrasound in detection of radiolucent foreign bodies in extremities. *Strategies Trauma Limb Reconstr* 2018;13:81-85.
 8. Ogilvie-Harris DJ, Gilbert M. Endoscopic bursal resection: The olecranon bursa and prepatellar bursa. *Arthroscopy* 2000;16:249-253.
 9. Pereira HMD, Correlo VM, Silva-Correia J, Oliveira JM, Reis Ceng RL, Espregueira-Mendes J. Migration of "bioabsorbable" screws in ACL repair. How much do we know? A systematic review. *Knee Surg Sports Traumatol Arthrosc* 2013;21:986-994.
 10. Solheim E, Sudmann B, Bang G, Sudmann E. Biocompatibility and effect on osteogenesis of poly(ortho ester) compared to poly(DL-lactic acid). *J Biomed Mater Res* 2000;49:257-263.
 11. Thompson SM, Fung S, Wood DG. The natural history of biointerference screw cyst and new bone formation in anterior cruciate ligament reconstruction: 16-year follow-up. *Am J Sports Med* 2016;44:113-117.
 12. Sprowson AP, Aldridge SE, Noakes J, Read JW, Wood DG. Bio-interference screw cyst formation in anterior cruciate ligament reconstruction—10-year follow up. *Knee* 2012;19:644-647.
 13. Debieux P, Franciozi CES, Lenza M, et al. Bioabsorbable versus metallic interference screws for graft fixation in anterior cruciate ligament reconstruction. *Cochrane Database Syst Rev* 2016;7:CD009772.