



CASE REPORT

REVISED Case Report: Polyvinylpyrrolidone deposition disease from repeated injection of opioid substitution drugs: report of a case with a fatal outcome [version 2; peer review: 2 approved]

Ida Viken Stalund ^{1,2}, Gro Nygard Riise³, Friedemann Leh¹, Tormod Karlsen Bjånes ⁴, Lars Riise⁵, Einar Svarstad², Sabine Leh ^{1,2}

¹Department of Pathology, Haukeland University Hospital, Post box 1, 5021 Bergen, Norway

²Department of Clinical Medicine, University of Bergen, Jonas Lies vei 87, 5021 Bergen, Norway

³Department of Medicine, Haukeland University Hospital, Post box 1, 5021 Bergen, Norway

⁴Department of Medical Biochemistry and Pharmacology, Haukeland University Hospital, Post box 1, 5021 Bergen, Norway

⁵Kvam Municipality, Grovagelet 16, 5600 Norheimsund, Norway

V2 First published: 19 Apr 2021, 10:300
<https://doi.org/10.12688/f1000research.51927.1>

Latest published: 07 Jul 2021, 10:300
<https://doi.org/10.12688/f1000research.51927.2>

Abstract

Background: Intravenous injection of oral opioid substitution drugs (OSD) is widespread among injecting drug users. Several OSDs contain the polymer polyvinylpyrrolidone (PVP) as an excipient. Parenterally administered PVP of high molecular weight may accumulate in tissues and organs. This phenomenon was first described in the 1950s, when PVP was utilised in medication for parenteral use. We report a case of an opioid-addicted patient with extensive PVP-deposition caused by repeated injections of OSDs.

Case presentation: A 30-year-old male drug addicted patient in opioid substitution therapy (OST) was repeatedly referred to his local hospital in a poor general condition. Work-up revealed severe normocytic anaemia, renal insufficiency, pancreas insufficiency and pathological fractures. Biopsies from fractured bones, bone marrow and gastric mucosa showed extensive infiltrates of histiocytes with intracytoplasmic vacuoles. Vacuole content stained slightly bluish in hematoxylin and eosin stain, red in Congo red stain and black in periodic acid methenamine silver stain. The morphological appearance and staining properties were in accordance with the diagnosis of PVP deposition. The patient had been injecting both buprenorphine tablets and a specific methadone syrup for several years. The methadone syrup contained large amounts of high molecular weight PVP, making it the most likely cause of the deposition. His health quickly deteriorated and he died, impaired by multi-organ failure and cachexia, five years after the first diagnosis of

Open Peer Review

Reviewer Status

Invited Reviewers

1

2

version 2

(revision)
07 Jul 2021



report



version 1

19 Apr 2021



report



report

1. **Maïke Büttner-Herold** , Friedrich-Alexander University Erlangen-Nuremberg (FAU), Erlangen, Germany

2. **Robert Barnes Colvin**, Massachusetts General Hospital, Boston, USA

Any reports and responses or comments on the article can be found at the end of the article.

PVP-deposition. The autopsy revealed extensive PVP-deposition in all sampled organs and tissues.

Conclusions: Histological investigation and the correct identification of PVP in the biopsies led to the discovery of a severe adverse effect from long-standing misuse of a drug. The disseminated PVP deposition likely contributed to multi-organ dysfunction and cachexia with a fatal outcome. The deposited PVP likely originated from repeated injections of a certain methadone syrup.

Keywords

Polyvinylpyrrolidone, PVP, povidone, opioid substitution therapy, opioid substitution drugs, methadone, adverse effect, case report

Corresponding author: Ida Viken Stalund (ida.viken.stalund@helse-bergen.no)

Author roles: **Stalund IV:** Investigation, Visualization, Writing – Original Draft Preparation; **Riise GN:** Conceptualization, Investigation, Writing – Original Draft Preparation; **Leh F:** Conceptualization, Investigation, Writing – Review & Editing; **Bjånes TK:** Investigation, Writing – Review & Editing; **Riise L:** Investigation, Writing – Review & Editing; **Svarstad E:** Conceptualization, Writing – Review & Editing; **Leh S:** Conceptualization, Funding Acquisition, Investigation, Supervision, Writing – Review & Editing

Competing interests: No competing interests were disclosed.

Grant information: Ida Viken Stalund was funded by The Western Norway Health Authority [grant number 912001].
The funders had no role in study design, data collection and analysis, decision to publish, or preparation of the manuscript.

Copyright: © 2021 Stalund IV *et al.* This is an open access article distributed under the terms of the [Creative Commons Attribution License](#), which permits unrestricted use, distribution, and reproduction in any medium, provided the original work is properly cited.

How to cite this article: Stalund IV, Riise GN, Leh F *et al.* **Case Report: Polyvinylpyrrolidone deposition disease from repeated injection of opioid substitution drugs: report of a case with a fatal outcome [version 2; peer review: 2 approved]** F1000Research 2021, 10:300 <https://doi.org/10.12688/f1000research.51927.2>

First published: 19 Apr 2021, 10:300 <https://doi.org/10.12688/f1000research.51927.1>

REVISED Amendments from Version 1

Based on the review reports from the reviewers, we have revised sections of the text and added a reference.

Key words: Case report removed. Foreign material and histiocytic storage added.

Result section:

Under the sub-heading "Biopsy findings": We have added "in Congo red stain or any other stain." to the last sentence.

Under the sub-heading "Further development": We have added a sentence about thrombocytopenia and leukocytopenia.

Under the subheading "Autopsy findings": We have added a sentence about the absence of symptoms of cardiac dysfunction. Sentences about findings in the pancreatic tissue altered for clarification. Sentence added about glomerular findings. Sentence added about signs of acute inflammation. For clarification, we have made a minor revision to the legend for Figure 4.

Discussion section:

In the second paragraph of the discussion: We have added a sentence about differentiating PVP deposits from deposits of crosopovidone. New reference added: Ganesan S, Felo J, Saldana M, Kalasinsky VF, Lewin-Smith MR, Tomaszewski JF, Jr. (2003) Embolized crosopovidone (poly[N-vinyl-2-pyrrolidone]) in the lungs of intravenous drug users. *Mod Pathol* 16(4):286-92. <https://doi.org/10.1097/01.mp.0000062653.65441.da>

Any further responses from the reviewers can be found at the end of the article

Background

Injection of oral opioid substitution drugs (OSD) is a concern in the treatment of opioid dependency. An Australian study found that 7–13% of clients in opioid substitution therapy (OST) injected their medication weekly or more often.¹ The OSDs may also be sold on the illegal drug market, and 26.6% of out-of-treatment intravenous drug users in a Norwegian study reported having injected methadone during the past 4 weeks.² Injection of oral or sublingual drug formulations may lead to vascular and soft tissue damage with a range of secondary complications.³

Several OSDs contain the excipient polyvinylpyrrolidone (PVP),⁴ a water-soluble polymer with a wide variety of applications in the pharmaceutical industry.⁵ When orally ingested, PVP is not absorbed, and causes no harm.^{6,7} When injected, PVP is not metabolized, and the only way of excretion is via glomerular filtration.⁶ While low molecular weight (MW) PVP is freely filtered by the glomerulus, PVP with moderate or high MW will be partly or completely retained in the body.^{6,8} In the middle part of the last century, PVP was utilized as a plasma expander⁹ and as a retarding agent in hormone preparations for injection.¹⁰ Reports from this time described storage in multiple tissues following repeated parenteral administrations of PVP-containing preparations.^{9–11}

We report a case of extensive PVP-deposition disease with a fatal outcome following long-term injection of PVP-containing OSDs.

Case presentation**First admission**

A male, 30-year-old drug addicted patient in OST was admitted to the local hospital. He was hepatitis C positive and had a history of hospitalisations for skin infection. At admittance, he was in a poor general condition with nausea, vomiting, abdominal pain and muscle aches. Physical examination revealed a diffusely tender abdomen and poor dental status. Laboratory investigations disclosed non-specific inflammatory signs with an increased erythrocyte sedimentation rate (83 mm/h) and C-reactive protein (CRP, 90 mg/L), severe normocytic anaemia with a haemoglobin of 7.8 g/dL and renal insufficiency (serum creatinine 133 µmol/L, estimated glomerular filtration rate 60.1 mL/min/1.73m²) with microalbuminuria. Blood cultures were negative. Radiological examinations of the thorax and abdomen showed splenomegaly and a pancreatic cyst, but otherwise no radiologic signs of infection, malignancy or kidney pathology. His CRP and serum creatinine levels fell spontaneously, and he left the hospital against the doctor's advice after four days.

Second admission

Two months later, the patient fractured his right clavicle. After a two-week delay, he was admitted to hospital with a fever and a swollen and erythematous clavicular region. His general condition and nutritional status had worsened, nausea and vomiting persisted and anaemia and renal insufficiency had relapsed. Blood cultures were positive for *Staphylococcus aureus*, and antibiotic treatment against suspected osteomyelitis was initiated. Magnetic resonance imaging (MRI) of the clavicular region and the upper arm showed mottled signal changes with a high signal intensity in the lateral clavicle, the humeral bone and the acromion (Figure 1a). The diagnoses considered at this time were osteomyelitis or malignancy. Biopsies from the fractured bone, bone marrow and gastric mucosa were performed in the work-up of this complex symptomatology.

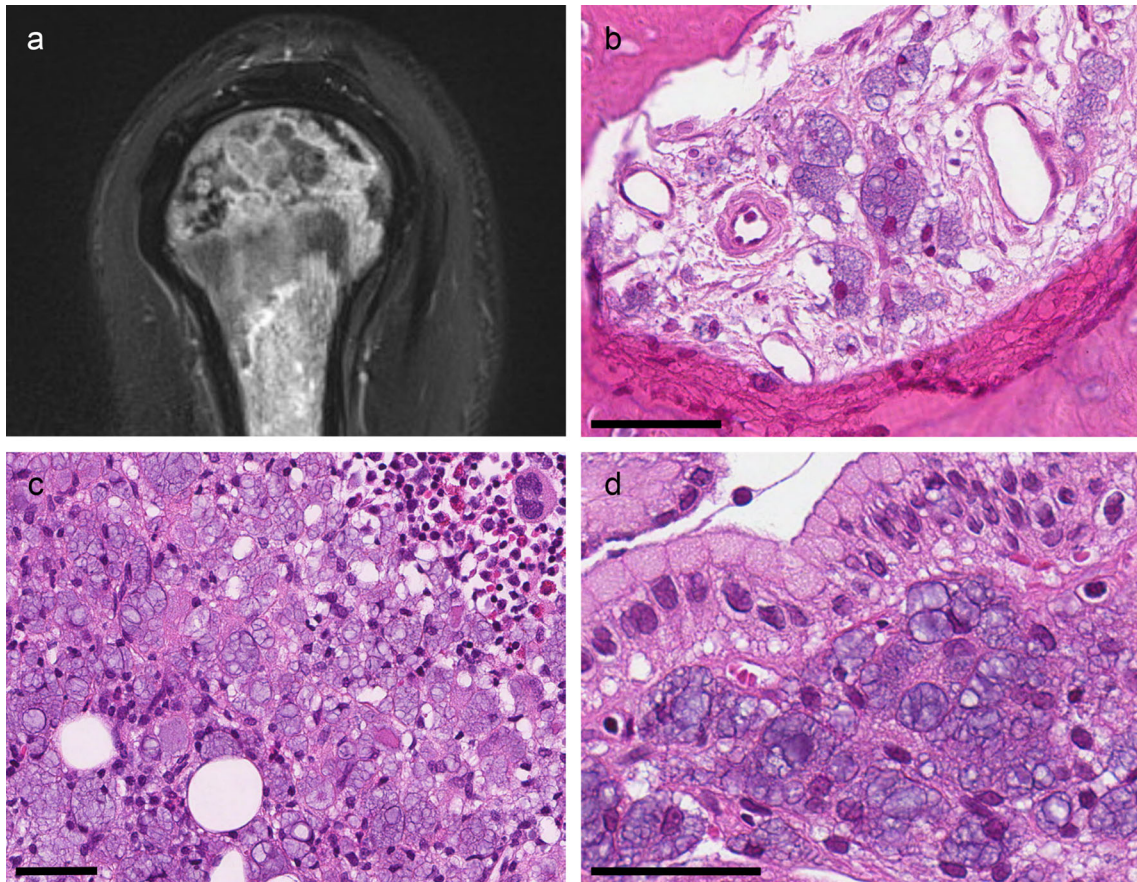


Figure 1. Radiological and biopsy findings. (a) MRI (T2-blade-sag-FS) of the right humerus showing mottled signal changes. (b) Clavicular bone (H&E): The marrow space is infiltrated by histiocytes with bluish transparent bubbles. (c) Bone marrow (H&E): Massive infiltration of histiocytes and scarce remaining hematopoietic tissue. (d) Gastric mucosa (H&E): Infiltration of vacuolated histiocytes in an extended lamina propria. All scale-bars 50 μ m.

Biopsy findings

The biopsies all showed similar infiltrates of histiocytes with a cytoplasm extended by vacuoles of different sizes (Figure 1b–d) and eccentrically located nuclei.

Biopsies from the fractured bone revealed reactive changes with ongoing fibrosis. The fibrotic tissue contained the multivacuolated histiocytes as singular cells, small groups or sheets of cells (Figure 1b). The bone marrow biopsy showed massive histiocytic infiltrates (Figure 1c). There was reduced fat cell content, and there was almost no visible hematopoietic tissue. The gastric biopsy showed antrum mucosa with elongated gastric pits and aggregates of multivacuolated histiocytes in both the superficial and deep lamina propria (Figure 1d). A gastric biopsy taken two years previously was re-examined. It showed the same histiocytic infiltrates; however, the findings did not lead to the correct diagnosis at the time.

In the hematoxylin and eosin (H&E) stain, the vacuoles had distinct membranes and a bluish, transparent looking content. Vacuole content did not stain in the periodic acid Schiff (PAS), Prussian blue or Alcian blue stain. The cells were positive for CD68/PGM1 confirming the histiocytic nature (Figure 2a). The vacuoles stained red in Congo red stain and black in the periodic acid methenamine silver (PASM) stain (Figure 2b and c). The vacuoles did not show birefringence in Congo red stain or other stains.

Interpretation

The microscopic appearance of the vacuolated histiocytes and the histochemical staining properties were consistent with PVP deposition.^{12,13} At that time, several of the OSDs marketed in Norway contained PVP.⁴ Our patient had injected both buprenorphine tablets and methadone syrup regularly over several years. The buprenorphine tablets contained PVP K30 (MW 44–54 kDa). The specific methadone syrup he had been injecting contained large amounts of PVP K90 (MW 1 000–1 500 kDa).¹⁴ While much of the PVP K30 is expected to be excreted within weeks, PVP K90 will not be excreted and

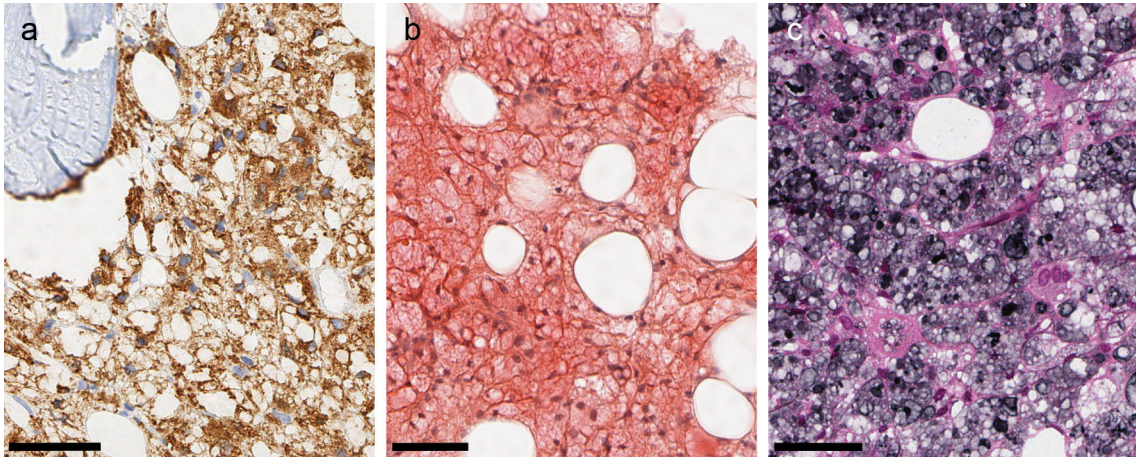


Figure 2. Staining properties. All micrographs are from the same bone marrow biopsy. (a) CD 68/PGM1: The vacuolated cells are CD68-positive histiocytes. (b) Congo red stain: Vacuole content stains faintly red. (c) PASM: Vacuole content stains grey or black. All scale bars 50 µm.

consequently accumulates in the body.⁶ It is therefore plausible that injections of the PVP K90-containing methadone syrup were the cause of the PVP-deposition disease in this patient. Based on the history of this patient and other similar cases,^{15,16} the European Medicines Agency suspended this methadone syrup in 2014.¹⁴

Further development

After the diagnosis was made, the patient's health gradually declined, in part due to his poor self-care and underlying chronic drug addiction. There is no specific treatment for PVP deposition disease. His persistent anaemia was treated with regular blood transfusions and erythropoietin-stimulating agents with limited effect. He had short episodes of mild thrombocytopenia and leukocytopenia, and, in general, his leukocyte response to infection was weak. The kidney failure was managed by supportive treatment, and serum creatinine levels fluctuated between 150 and 450 µmol/L.

Within the first year of the diagnosis, the patient suffered a left sided pathological femoral neck fracture with impaired fracture healing, complicated by chronic osteomyelitis. In the right hip, he developed severe bone destruction of the acetabulum with dislocation of the femoral head and a subsequent femoral neck fracture (Figure 3a). MRI scans of both hips and the pelvis (not shown) revealed the same changes as those detected in the shoulder region. Biopsies from the

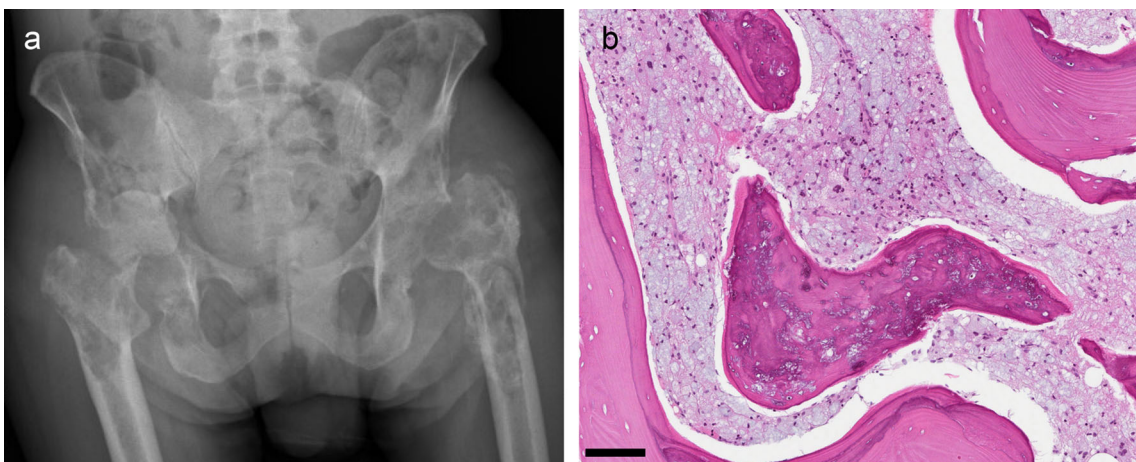


Figure 3. Pathological fractures and bone destruction: radiological and biopsy findings. (a) Pelvic radiograph. Left hip: The hip prosthesis has been removed due to loosening and replaced by a Girdlestone hip. Right hip: Extensive lytic and sclerotic changes in the proximal femur and acetabulum leading to medial dislocation of the femoral head. (b) Biopsy from the right greater trochanter (H&E): The marrow space is filled with histiocytes with the bluish vacuoles characteristic of PVP-deposition. The bone trabecula has empty lacunar spaces and contains a bluish material. Scale bar 50 µm.

greater trochanter region showed extensive histiocytic infiltrates (Figure 3b). Surgical treatments were unsuccessful. Henceforth his mobility deteriorated to such a degree that he needed a wheelchair and required daily activity support and care in a palliative care centre. Furthermore, he developed endocrine pancreas insufficiency with insulin-dependent diabetes mellitus. He had a gradual weight loss of 22 kg during four years despite adequate food intake. Malabsorption due to exocrine pancreas insufficiency was suspected, but supplementation of pancreas enzymes had little effect on the weight loss.

Five years after the diagnosis of PVP deposition disease, the patient died, impaired by multi-organ failure and advanced cachexia with a body mass index below 15 kg/m².

Autopsy

The autopsy concluded that the immediate cause of death was multi organ failure due to PVP deposition disease, which in turn was a consequence of the patient's illicit substance abuse. The following organs and tissues were sampled during the autopsy: the pericardium and myocardium, the pleura and lungs, kidneys, liver, pancreas, gastric mucosa, adrenal glands, peritoneum and abdominal adipose tissue, the spleen, lymph nodes, and femoral bone and bone marrow. Microscopically, we observed PVP-deposition in all sampled organs and tissues (Figure 4). The PVP-containing histiocytes were partly scattered in the interstitium, e.g. in the myocardium (Figure 4a), and partly organised like larger, nodular lesions, e.g. in the pleura (Figure 4b). Peri- and intra-neural distribution was seen in several organs including the heart. However, there were no clinical, echocardiographic or electrocardiographic evidence of impaired cardiac output or arrhythmias prior to his death. Autopsy findings corresponded well with the clinically observed pancreas and kidney insufficiency. There was little preserved exocrine and endocrine pancreas parenchyma. The pancreatic tissue was dominated by dense fibrosis interspersed by heavy infiltrations of histiocytes (Figure 4c). The kidney showed moderate to severe interstitial fibrosis and tubular atrophy, and only minor glomerular changes. There were infiltrates of PVP-containing histiocytes in the interstitium, mostly in atrophic areas (Figure 4d). In glomeruli, we observed a slightly increased number of histiocytes and occasional PVP-containing vacuoles. There were no amyloid depositions or signs of

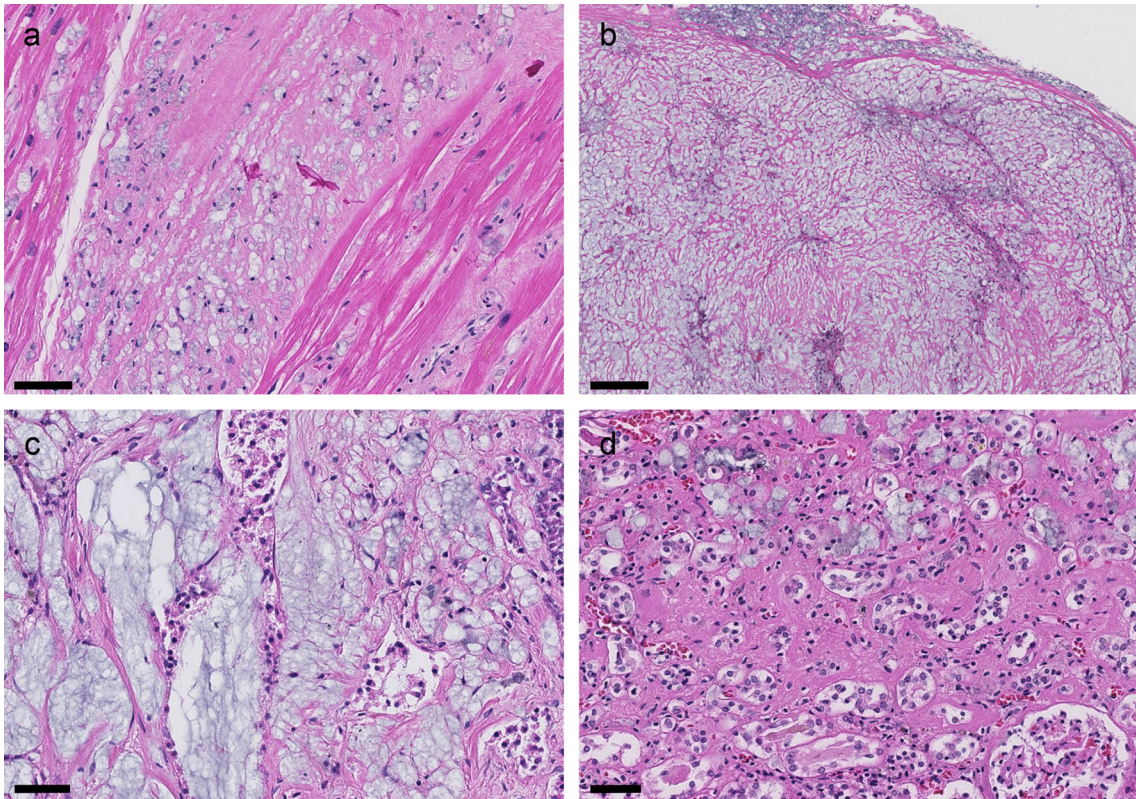


Figure 4. Autopsy findings (H&E). Infiltrates of histiocytes with the bluish vacuoles characteristic of PVP in all organs. (a) Myocardium: Interstitial fibrosis and histiocytic infiltrates. Scale bar 50 μ m. (b) Pleura: Nodular lesion composed of fibrotic tissue and histiocytes. We found similar lesions in the pericardium and peritoneum. These were macroscopically visible. Scale bar 200 μ m. (c) Pancreas: Pronounced fibrosis with histiocytic infiltrates. Poorly preserved ductal structures. Scale bar 50 μ m. (d) Kidney: Cortical tissue showing interstitial fibrosis, tubular atrophy, and an infiltrate of histiocytes in the extended interstitium. Scale bar 50 μ m.

other renal diseases. The autopsy revealed no evidence of infection besides minor foci of acute inflammation in the pancreas.

Discussion

We present the case of a drug-addicted patient with widespread PVP-deposition disease. We describe the patient's clinical course from the first diagnosis of PVP-deposition to his death five years later and present biopsy and autopsy findings. The PVP deposition disease in this patient was likely caused by repeated intravenous injections of a methadone syrup containing high MW PVP.

The characteristic appearance and staining properties of PVP in tissue samples are well known.¹⁷ Positivity for Congo red and PASM and negativity for PAS distinguishes PVP deposits from those seen in hereditary storage diseases. The histiocytic nature of the cells and the PAS negativity rule out metastatic signet ring cell carcinoma as a differential diagnosis.¹⁷ PVPs light blue color in H&E and the typical localization of the deposits differentiates it from the non-water soluble variant of PVP, crospovidone.¹⁸ Furthermore, PVP is not birefringent, unlike most other foreign materials commonly observed in tissue samples from injecting drug users.¹⁹ Hence, making the diagnosis of PVP deposition is straightforward if this option is considered.

Whether PVP deposition causes disease was controversial for a long time. The first reports of PVP- deposition described storage in the tissue that persisted years after the administration of PVP, but disputed whether the storage was harmful to the functioning of the target organs.²⁰ Later reports described clinically relevant adverse effects. Those most frequently reported were cytopenias, bone destruction, polyneuropathy and granulomatous lesions of the skin.^{17,21–24} PVP deposition in internal organs such as the liver, kidneys, pancreas and the gastrointestinal tract has also been described, but the adverse effect of the deposition in these organs is less well known.^{25,26}

Our patient experienced a complex clinical syndrome and rapidly deteriorating health. The reason for his health decline was multifactorial, and his continued drug addiction likely aggravated the clinical course. Many of the clinical conditions associated with the fatal outcome correspond to findings in biopsies and the autopsy showing extensive PVP deposition. We believe that the extensive PVP deposition contributed to his health decline through several mechanisms. The widespread PVP deposition in bone and bone marrow was likely the main reason for the patient's anaemia, pathological fractures and impaired fracture healing, fitting well with previous reports.^{21,23,24} The impaired mobility and chronic osteomyelitis that resulted from these fractures gravely affected his health and quality of life. Furthermore, progressive cachexia was an important part of his health decline. The reason for the weight loss was not established during his lifetime, but his continued drug use likely contributed. Other possible contributing factors were pancreas insufficiency, progressive kidney failure, malabsorption, chronic infections and continued problems with vomiting, all likely related to the extensive PVP deposition. In summary, the PVP deposition probably played a major role in causing the patients' multiple organ dysfunction ultimately leading to the fatal outcome.

Injection of oral OSDs is common among injecting drug users and has long been a concern in the treatment of opioid addiction.² As an attempt to prevent injections, the previously mentioned methadone syrup was made highly viscous.¹⁴ However, the increased viscosity did not prevent such unintended use. As a consequence, the choice of high MW PVP as thickener caused further severe adverse effects from injection.

Conclusions

This case revealed an unanticipated explanation for anaemia and pathological fractures in a drug-addicted patient. The correct identification of the observed foreign material as PVP revealed that injection of a certain methadone syrup containing PVP probably caused the patient's deposition disease. Based on the clinical history, biopsy and autopsy findings, we conclude that the widespread PVP deposition likely contributed to the patient's severe morbidity and death.

List of abbreviations

PVP: Polyvinylpyrrolidone

OSD: Opioid substitution drug

OST: Opioid substitution therapy

H&E: Hematoxylin and eosin stain

PASM: Periodic acid methenamine silver stain

PAS: Periodic acid Schiff stain

CRP: C-reactive protein

MRI: Magnetic resonance imaging

MW: Molecular weight

Data availability

All data underlying the results are available as part of the article and no additional source data are required.

Reporting guidelines

Zenodo: CARE checklist for “Polyvinylpyrrolidone deposition disease from repeated injection of opioid substitution drugs: report of a case with a fatal outcome”. <https://doi.org/10.5281/zenodo.4667989>.²⁷

Data are available under the terms of the [Creative Commons Zero “No rights reserved” data waiver \(CC0 1.0 Universal\)](#).

Consent for publication

Written informed consent for publication of the patient’s clinical details and clinical images was obtained from the patient prior to his death and from the closest relative.

Acknowledgements

We appreciate the contributions of the patient and his family in allowing us to discuss his care and findings. We thank Ingrid Vallevik and Stine Kristoffersen for performing the autopsy and Anna Emilia Kozak for valuable comments on the radiologic images.

References

- Degenhardt L, Larance BK, Bell JR, *et al.*: **Injection of medications used in opioid substitution treatment in Australia after the introduction of a mixed partial agonist-antagonist formulation.** *Med J Aust.* 2009; **191**(3): 161–165. [PubMed Abstract](#) | [Publisher Full Text](#)
- Bretteville-Jensen AL, Lillehagen M, Gjersing L, *et al.*: **Illicit use of opioid substitution drugs: prevalence, user characteristics, and the association with non-fatal overdoses.** *Drug Alcohol Depend.* 2015; **147**: 89–96. [PubMed Abstract](#) | [Publisher Full Text](#)
- Yeo AK, Chan CY, Chia KH: **Complications relating to intravenous buprenorphine abuse: a single institution case series.** *Ann Acad Med Singap.* 2006; **35**(7): 487–91. [PubMed Abstract](#)
- European Medicines Agency: **Methadone medicinal products for oral use containing povidone.** 2014 [Reference Source](#) Accessed 07.11.2015.
- Buehler V: *Polyvinylpyrrolidone Excipients for Pharmaceuticals: Povidone, Crospovidone and Copovidone.* Berlin: Springer; 2005.
- Robinson BV, Sullivan FM, Borzelleca JF, *et al.*: *PVP - A Critical Review of the Kinetics and Toxicology of Polyvinylpyrrolidone (Povidone).* Michigan: Lewis Publishers; 1990.
- Siber GR, Mayer RJ, Levin MJ: **Increased gastrointestinal absorption of large molecules in patients after 5-fluorouracil therapy for metastatic colon carcinoma.** *Cancer Res.* 1980; **40**(10): 3430–6. [PubMed Abstract](#)
- Ravin HA, Seligman AM, Fine J: **Polyvinyl pyrrolidone as a plasma expander: studies on its excretion, distribution and metabolism.** *N Engl J Med.* 1952; **247**(24): 921–9. [PubMed Abstract](#) | [Publisher Full Text](#)
- Honda K, Motoki R, Sakuma H, *et al.*: **Complications following the use of plasma expander, especially polyvinylpyrrolidone.** *Int Surg.* 1966; **45**: 539–47.
- Christensen M, Johansen P, Hau C: **Storage of polyvinylpyrrolidone (PVP) in tissues following long-term treatment with a PVP-containing vasopressin preparation.** *Acta Med Scand.* 1978; **204**(4): 295–8. [PubMed Abstract](#) | [Publisher Full Text](#)
- Wessel W, Schoog M, Winkler E: **Polyvinylpyrrolidone (PVP), its diagnostic, therapeutic and technical application and consequences thereof.** *Arzneimittelforschung.* 1971; **21**(10): 1468–82. [PubMed Abstract](#)
- Reske-Nielsen E, Bojsen-Moller M, Vetner M, *et al.*: **Polyvinylpyrrolidone-storage disease. Light microscopical, ultrastructural and chemical verification.** *Acta Pathol Microbiol Scand A.* 1976; **84**(5): 397–405. [PubMed Abstract](#)
- Weiss SW, Goldblum JR: **Benign fibrohistiocytic and histiocytic tumors.** In: *Enzinger and Weiss’s Soft Tissue Tumors.* 6 ed. Philadelphia: Mosby Elsevier; 2014. p. 378–80.
- European Medicines Agency: **Assessment report for methadone medicinal products for oral use containing povidone.** 2014. [Reference Source](#) Accessed 07.11.2015
- Kaur P, Bergrem A, Gerlyng P, *et al.*: **A methadone user with anaemia, skeletal pain and altered appearance.** *Tidsskr Nor Laegeforen.* 2016; **136**(10): 925–9. [PubMed Abstract](#) | [Publisher Full Text](#)
- Kristoffersen AH, Bjanes TK, Jordal S, *et al.*: **Polyvinylpyrrolidone induced artefactual prolongation of activated partial thromboplastin times in intravenous drug users with renal failure.** *J Thromb Haemost.* 2016; **14**(5): 936–9. [PubMed Abstract](#) | [Publisher Full Text](#)
- Kuo TT, Hsueh S: **Mucicarmophilic histiocytosis. A polyvinylpyrrolidone (PVP) storage disease simulating signet-ring cell carcinoma.** *Am J Surg Pathol.* 1984; **8**(6): 419–28. [PubMed Abstract](#) | [Publisher Full Text](#)
- Ganesan S, Felo J, Saldana M, Kalasinsky VF, *et al.*: **Embolized crospovidone (poly[N-vinyl-2-pyrrolidone]) in the lungs of intravenous drug users.** *Mod Pathol.* 2003; **16**(4):

- 286-92.
[Publisher Full Text](#)
19. Kringsholm B, Christoffersen P: **The nature and the occurrence of birefringent material in different organs in fatal drug addiction.** *Forensic Sci Int.* 1987; **34**(1-2): 53-62.
[PubMed Abstract](#) | [Publisher Full Text](#)
 20. Altemeier WA, Schiff L, Galle A, *et al.*: **Physiological and pathological effects of long-term polyvinylpyrrolidone retention.** *AMA Arch Surg.* 1954; **69**(3): 308-14.
[PubMed Abstract](#)
 21. Kepes JJ, Chen WY, Jim YF: **'Mucoïd dissolution' of bones and multiple pathologic fractures in a patient with past history of intravenous administration of polyvinylpyrrolidone (PVP). A case report.** *Bone Miner.* 1993; **22**(1): 33-41.
[PubMed Abstract](#) | [Publisher Full Text](#)
 22. Kuo TT, Hu S, Huang CL, *et al.*: **Cutaneous involvement in polyvinylpyrrolidone storage disease: a clinicopathologic study of five patients, including two patients with severe anemia.** *Am J Surg Pathol.* 1997; **21**(11): 1361-7.
[PubMed Abstract](#) | [Publisher Full Text](#)
 23. Dunn P, Kuo T, Shih LY, *et al.*: **Bone marrow failure and myelofibrosis in a case of PVP storage disease.** *Am J Hematol.* 1998; **57**(1): 68-71.
[PubMed Abstract](#) | [Publisher Full Text](#)
 24. Huang WC, Chang CH, Tsai CC: **Polyvinylpyrrolidone storage disease presenting as pathologic fracture and anemia: report of a case with imprint cytology.** *Diagn Cytopathol.* 2012; **40**(1): 69-72.
[PubMed Abstract](#) | [Publisher Full Text](#)
 25. Kojima M, Takahashi K, Honda K: **Morphological study on the effect of polyvinyl pyrrolidone infusion upon the reticuloendothelial system.** *Tohoku J Exp Med.* 1967; **92**(1): 27-54.
[PubMed Abstract](#) | [Publisher Full Text](#)
 26. Edelmann U, Johansen P, Pedersen AB, *et al.*: **PVP storage as the cause of specific organ symptoms.** *Ugeskr Laeger.* 1977; **139**(39): 2309-12.
[PubMed Abstract](#)
 27. Stalund IV, Riise GN, Leh F, *et al.*: **CARE checklist for "Polyvinylpyrrolidone deposition disease from repeated injection of opioid substitution drugs: report of a case with a fatal outcome".** *Zenodo.* 2021.
[Publisher Full Text](#)

Open Peer Review

Current Peer Review Status:  

Version 2

Reviewer Report 08 July 2021

<https://doi.org/10.5256/f1000research.58229.r89200>

© 2021 Büttner-Herold M. This is an open access peer review report distributed under the terms of the [Creative Commons Attribution License](#), which permits unrestricted use, distribution, and reproduction in any medium, provided the original work is properly cited.



Maïke Büttner-Herold 

Department of Nephropathology, Institute of Pathology, Friedrich-Alexander University Erlangen-Nuremberg (FAU), Erlangen, Germany

The authors addressed all points I had to my perfect satisfaction and I have no further questions. Thank you for the opportunity to review this very interesting case.

Competing Interests: Maïke Büttner-Herold is involved in an European initiative working on a harmonized Kidney biopsy coding (KBC) system, which is coordinated by S. Leh. It is a project in which a large number of European Nephropathologists are involved discussing in meetings of how to best construct a coding system. From time to time we also have Zoom-meetings or email correspondence. This, however, has nothing to do with the case report submitted.

Reviewer Expertise: Nephropathology, GvHD, immunology

I confirm that I have read this submission and believe that I have an appropriate level of expertise to confirm that it is of an acceptable scientific standard.

Version 1

Reviewer Report 26 May 2021

<https://doi.org/10.5256/f1000research.55139.r85062>

© 2021 Colvin R. This is an open access peer review report distributed under the terms of the [Creative Commons Attribution License](#), which permits unrestricted use, distribution, and reproduction in any medium, provided the original work is properly cited.



Robert Barnes Colvin

Department of Pathology, Massachusetts General Hospital, Boston, MA, USA

The paper shows no new information, but the problem is a major one, with missed diagnoses and serious consequences. I think the paper will receive some attention with the major opioid crisis we have.

I have no specific suggestions, other than a careful editing of the prose and the addition of at least one other major publication which has embolized material (EM) - e.g., Ganesan *et al.* (2003)¹.

References

1. Ganesan S, Felo J, Saldana M, Kalasinsky VF, et al.: Embolized crosopvidone (poly[N-vinyl-2-pyrrolidone]) in the lungs of intravenous drug users. *Mod Pathol.* 2003; **16** (4): 286-92 [PubMed Abstract](#) | [Publisher Full Text](#)

Is the background of the case's history and progression described in sufficient detail?

Yes

Are enough details provided of any physical examination and diagnostic tests, treatment given and outcomes?

Yes

Is sufficient discussion included of the importance of the findings and their relevance to future understanding of disease processes, diagnosis or treatment?

Yes

Is the case presented with sufficient detail to be useful for other practitioners?

Yes

Competing Interests: No competing interests were disclosed.

I confirm that I have read this submission and believe that I have an appropriate level of expertise to confirm that it is of an acceptable scientific standard.

Author Response 28 Jun 2021

Ida Viken Stalund, Haukeland University Hospital, Post box 1, 5021 Bergen, Norway

We thank you for your thorough review of our manuscript.

To address your comment, we have added the following sentence in the second paragraph of the discussion: "PVPs light blue color in H&E and the typical localization of the deposits differentiates it from the non-water soluble variant of PVP, crosopvidone." and added your suggested reference.

Competing Interests: No competing interests were disclosed.

Reviewer Report 28 April 2021

<https://doi.org/10.5256/f1000research.55139.r83519>

© 2021 Büttner-Herold M. This is an open access peer review report distributed under the terms of the [Creative Commons Attribution License](#), which permits unrestricted use, distribution, and reproduction in any medium, provided the original work is properly cited.



Maike Büttner-Herold 

Department of Nephropathology, Institute of Pathology, Friedrich-Alexander University Erlangen-Nuremberg (FAU), Erlangen, Germany

The present case report illustrates a very impressive case of PVP deposition in histiocytes in a large number of organs in a patient who repeatedly injected oral opioid substitution drugs. The description of such a finding is very valuable as the identification of foreign material can be very difficult for a pathologist, if the histological picture has not previously been seen. The illustration of the findings is very nicely done.

Some minor points could be addressed:

- Besides the reported anaemia did the patient also have thrombopenia and leukopenia, which could explain the infectious complications?
- Was the patient free of infectious complications when he died?
- Can a loss of pancreatic islets be shown by immunohistochemistry? In Figure 4C one wonders whether remaining islets are depicted.
- As PVP is filtered in the glomeruli, were histiocytes detectable in the glomeruli? Was the distribution of PVP-loaden histiocytes in the kidneys dependent on the renal compartment?
- Did the cardiac infiltration by histiocytes lead to functional impairment of the cardiac output or to arrhythmias?
- Is there a possible explanation why PVP should interfere with the structure of the bone in such a destructive way?
- Does the lack of birefringence of PVP also apply to the Congo red staining?
- Keywords: It would maybe be helpful to include "foreign material" and "histiocytic storage" to facilitate search for a pathologist finding PVP in a patient without being able to assign the finding to the right cause.

Is the background of the case's history and progression described in sufficient detail?

Yes

Are enough details provided of any physical examination and diagnostic tests, treatment given and outcomes?

Partly

Is sufficient discussion included of the importance of the findings and their relevance to future understanding of disease processes, diagnosis or treatment?

Yes

Is the case presented with sufficient detail to be useful for other practitioners?

Yes

Competing Interests: Maïke Büttner-Herold is involved in an European initiative working on a harmonized Kidney biopsy coding (KBC) system, which is coordinated by S. Leh. It is a project in which a large number of European Nephrologists are involved discussing in meetings of how to best construct a coding system. From time to time we also have Zoom-meetings or email correspondence. This, however, has nothing to do with the case report submitted.

Reviewer Expertise: Nephrology, GvHD, immunology

I confirm that I have read this submission and believe that I have an appropriate level of expertise to confirm that it is of an acceptable scientific standard, however I have significant reservations, as outlined above.

Author Response 28 Jun 2021

Ida Viken Stalund, Haukeland University Hospital, Post box 1, 5021 Bergen, Norway

We thank you for your thorough review of our manuscript. We have addressed your comments point by point.

Besides the reported anemia, did the patient also have thrombocytopenia and leukopenia, which could explain the infectious complications?

- The patient had episodes of mild thrombocytopenia and leukopenia. In general, his leukocyte response to infection was weak. We added the following sentence in the section "Further development" to address this question: "He had short episodes of mild thrombocytopenia and leukocytopenia, and in general, his leukocyte response to infection was weak."

Was the patient free of infectious complications when he died?

- In the days and weeks prior to his death, he had stable, moderately increased CRP. Clinically, he showed no signs of acute infection and he did not receive antibiotic treatment. The autopsy revealed small foci of acute inflammation in the pancreas, but otherwise there were no signs of an acute infection. We added the following sentence in the section "Autopsy" to address this question: "The autopsy revealed no evidence of infection besides minor foci of acute inflammation in the pancreas."

Can a loss of pancreatic islets be shown by immunohistochemistry? In Figure 4C, one wonders whether remaining islets are depicted.

- Based on H&E morphology there was little preserved pancreatic parenchyma, both pancreatic acini and islets. Synaptophysin and Chromogranin A staining revealed a marked loss of pancreatic islets. CK-19 staining revealed areas of some preserved

ductal structures, though the morphology was impaired by autolysis.

We changed the following sentence in the section "Autopsy" to address this question: "There was little preserved exocrine and endocrine pancreas parenchyma. The pancreatic tissue was dominated by dense fibrosis interspersed by heavy infiltrations of histiocytes (Figure 4c)."

- Figure 4C depicts fibrosis, PVP-containing histiocytes and ductal structures impaired by autolysis. Synaptophysin and Chromogranin A staining could not detect islets in this area. We changed the legend to figure 4C accordingly: (c) Pancreas: Pronounced fibrosis with histiocytic infiltrates. Poorly preserved ductal structures.

As PVP is filtered in the glomeruli, were histiocytes detectable in the glomeruli? Was the distribution of PVP-loaden histiocytes in the kidneys dependent on the renal compartment?

- In H&E, we observed occasional PVP-containing vacuoles in glomeruli. With CD68 staining, we detected histiocytes in most glomeruli. The number of histiocytes per glomerulus cross section was variable, but always less than ten. We added the following sentence in the section "Autopsy" to address this question: In glomeruli, we observed a slightly increased number of histiocytes and occasional PVP-containing vacuoles.
- The vast majority of PVP-containing histiocytes were seen in the tubulointerstitial compartment, as stated in the "Autopsy" section.

Did the cardiac infiltration by histiocytes lead to functional impairment of the cardiac output or to arrhythmias?

- The autopsy revealed infiltrates of PVP-containing histiocytes in the myocardium. We also observed peri- and intraneural distribution of the histiocytes. It is possible that such infiltrates could induce arrhythmias or other forms of cardiac impairments. Our patient did not show signs of such organ dysfunction, neither clinically nor in echocardiographic and electrocardiographic evaluations. We added the following sentence in the section "Autopsy" to address this question: "Peri- and intra-neural distribution was seen in several organs, including the heart. However, there were never any clinical, echocardiographic or electrocardiographic evidence of impaired cardiac output or arrhythmias prior to his death."

Is there a possible explanation why PVP should interfere with the structure of the bone in such a destructive way?

- The only mentioning of a possible cause for the bone destruction is in a case report from 1993: Kepes *et al.* suggested that cells containing engulfed PVP would undergo mucoid alterations as a result of interactions between the engulfed material and the cytoplasm. The authors argue that in bone, the PVP-induced mucoid changes cause "softening of the bone" and interfere with the structural integrity of the bone trabeculae. One could also speculate that the massive infiltration of histiocytes in the marrow space could affect the blood supply to the osseous tissue, causing a form of avascular necrosis.

We think a discussion of this unresolved matter is out of focus for this case report.

Does the lack of birefringence of PVP also apply to the Congo red staining?

- Yes, the lack of birefringence of PVP also apply to the Congo red. We changed the

following sentence in the section "Biopsy findings" to address this question: "The vacuoles did not show birefringence in Congo red stain or any other stains."

Keywords: It would maybe be helpful to include "foreign material" and "histiocytic storage" to facilitate search for a pathologist finding PVP in a patient without being able to assign the finding to the right cause

- Good point. We added these keywords.

Competing Interests: No competing interests were disclosed.

The benefits of publishing with F1000Research:

- Your article is published within days, with no editorial bias
- You can publish traditional articles, null/negative results, case reports, data notes and more
- The peer review process is transparent and collaborative
- Your article is indexed in PubMed after passing peer review
- Dedicated customer support at every stage

For pre-submission enquiries, contact research@f1000.com

F1000Research