





REGULAR ARTICLE

Retinal haemorrhage in infants investigated for suspected maltreatment is strongly correlated with intracranial pathology

Ingemar Thiblin¹  | Jacob Andersson¹  | Knut Wester²  | Göran Höberg³ | Ulf Höberg^{4,5} 

¹Department of Surgical Sciences, Uppsala University, Uppsala, Sweden

²Department of Clinical Medicine K1, University of Bergen, Bergen, Norway

³Private practice, Stockholm, Sweden

⁴Department of Women's and Children's Health, Uppsala University, Uppsala, Sweden

⁵Department of Epidemiology and Global Health, Umeå University, Umeå, Sweden

Correspondence

Ingemar Thiblin, Department of Forensic Medicine, Uppsala University, Box 1024, 751 40 Uppsala, Sweden.
 Email: ingemar.thiblin@surgsci.uu.se

Funding information

The authors received no financial support for the research, authorship, and/or publication of this article

Abstract

Aim: To test the two prevailing hypotheses regarding the aetiology of infant retinal haemorrhage: (a) traction forces exerted by the lens and/or corpus vitreum on the retina during infant shaking or (b) retinal vessel leakage secondary to intracranial pathology and raised intracranial pressure.

Methods: Comparison of medical findings and reported type of trauma in infants investigated for suspected physical abuse with presence ($n = 29$) or non-presence of retinal haemorrhage (RH) ($n = 119$).

Results: Intracranial pathology was recorded in 15 (13%) of the non-RH cases and in 27 (97%) of the RH cases ($p < 0.0001$). All 18 infants with bilateral RH had intracranial pathology. Of 27 infants subjected to witnessed or admitted shaking, two were in the group with RH. One had a single unilateral RH and no intracranial pathology. The other had bilateral RH and intracranial pathology with non-specific white matter changes, acute subdural and subarachnoid haemorrhages, and suspected cortical venous thrombosis. In 15 RH cases, there was no trauma reported and no findings other than RH and intracranial pathology. Accidental blunt head trauma was reported in 7 RH cases.

Conclusion: The present study indicates that RH in infants is secondary to intracranial pathology of non-specific aetiology.

KEYWORDS

infant abuse, intracranial pathology, retinal haemorrhage, subdural haemorrhage

1 | INTRODUCTION

Different mechanisms have been suggested to explain non-birth-related infant retinal haemorrhage, some solely involving traumatic aetiology and others pointing to either traumatic or non-traumatic aetiologies. Proposed mechanisms that are solely traumatic include traction forces on the retina exerted by the vitreous body when the

infant is shaken^{1,2} or disruption of retinal blood vessels by transmission shock waves along facial bones during blunt impact head injury.³ Venous congestion resulting from increased intrathoracic pressure during forceful chest compression has also been suggested as a mechanism.⁴

A suggested mechanism that could arise through either traumatic or non-traumatic aetiology is leakage from congested retinal veins

Abbreviations: AHT, Abusive head trauma; ASAH, Acute subarachnoid haemorrhage; ASDH, Acute subdural haemorrhage; CSDH, Chronic subdural haemorrhage; ONSD, Optic nerve sheath diameter; RH, Retinal haemorrhage; RICP, Raised intracranial pressure; SBS, Shaken baby syndrome.

This is an open access article under the terms of the Creative Commons Attribution-NonCommercial License, which permits use, distribution and reproduction in any medium, provided the original work is properly cited and is not used for commercial purposes.

© 2021 The Authors. *Acta Paediatrica* published by John Wiley & Sons Ltd on behalf of Foundation Acta Paediatrica.

because of raised intracranial pressure mediated via the optic nerve sheath.⁵ Examples of traumatic aetiologies include retinal haemorrhage associated with subdural haemorrhage in infants injured in witnessed fall accidents^{6,7} and traffic accidents.^{8,9} Nontraumatic aetiologies include acute meningeal haemorrhage from a vascular malformation¹⁰ or chronic subdural hematoma (CSDH)/hygroma, or external hydrocephalus with no evidence of trauma¹¹⁻¹³ and infectious disease.¹⁴

Despite these possible nontraumatic aetiologies, extensive retinal haemorrhage, especially when bilateral, has been claimed to be highly specific for infant abusive head trauma (AHT)^{2,15} and described as a cardinal feature of shaken baby syndrome/abusive head trauma.¹ If such a specificity was the case, one would assume that a mechanism implying vitreoretinal traction as a separate local, intraocular event could cause RH independently of any intracranial pathology. Conversely, if the cause is an extraocular phenomenon, such as raised intracranial or intrathoracic pressure, one would expect the RH to be associated with these extraocular factors.

The purpose of the present study was to investigate the conflicting hypotheses that non-birth-related retinal haemorrhage in infants is independent of intracranial pathology, i.e. caused by direct forces in the eye vs. retinal haemorrhage being secondary to intracranial pathology associated with raised intracranial pressure.

2 | METHODS

2.1 | Study design

This is a comparative case series study.

2.2 | Participants

Infants (ages 1–365 days) who underwent examination because of suspicion of maltreatment during 1997 to 2014 were identified in the Swedish National Patient Register by the following ICD-10 codes (Swedish version of International Classification of Diseases 10th version): Z03.8K (observation for suspected maltreatment), Y07.9 (maltreatment and neglect by unspecified perpetrator), T74.1 (physical abuse, confirmed), and Y06 (neglect and abandonment). The medical records were requested from the paediatric departments in Sweden.

A total of 337 infants with any maltreatment diagnosis were identified, and medical records could be retrieved for 257 (76%). The inclusion criterion was that the infant had been examined with both fundoscopy and neuroimaging by computed tomography and/or magnetic resonance imaging, ultimately leading to inclusion of 148 infants.

2.3 | Case categorization

The 148 infants were categorized into two main groups with respect to the presence ($n = 29$) or non-presence of retinal haemorrhage (RH) ($n = 119$). The RH cases were divided into unilateral ($n = 10$) and

Keynotes

- The exact mechanism behind retinal haemorrhage in alleged abusive head trauma is unclear; a study that may clarify and possibly distinguish between proposed mechanisms is therefore warranted.
- The present study revealed a strong correlation between presence of retinal haemorrhage and different types of subdural effusions. The correlation was apparently independent of underlying aetiology.
- The results emphasize the need for studying infant retinal haemorrhage with well-defined abuse cases and controls.

bilateral RH ($n = 19$) subgroups for further comparisons of the main outcome. The examining ophthalmologists' original reports were not always available and when present, not systematically detailed. For this reason, RH was not graded beyond unilateral/bilateral.

2.4 | Outcome

The main outcome was defined as any kind of intracranial pathology, including intracerebral haemorrhage, acute subdural haemorrhage, chronic subdural haemorrhage, hygroma, acute subarachnoid haemorrhage, brain oedema, cortical vein thrombosis, sinus vein thrombosis, and contusions.

2.5 | Covariates

Additional outcomes registered for interpretation of pathogenesis were findings and symptoms consistent with raised intracranial pressure, reported type of trauma, signs of head trauma (scalp/facial soft tissue lesions and skull fractures), reason for seeking care, age in days, and sex.

Findings consistent with raised intracranial pressure were defined as any statement of papillary oedema, rapidly increasing head circumference, sunset gaze, increased suture diastasis, compressive effect of extra-cerebral effusion such as midline shift or compressed ventricles, alternatively an extra cerebral effusion (subarachnoid or subdural) in combination with enlarged ventricles as seen in external hydrocephalus¹⁶ or objectively measured or observed raised intracranial pressure (such as “fluid emptying under high pressure”) during neurosurgical interventions. Symptoms consistent with raised intracranial pressure were defined as vomiting, seizures, and lowered level of consciousness.

The type of reported trauma was based on statements by caregivers or witnesses: (a) shaking without blunt force trauma, (b) shaking with blunt force trauma, (c) solely blunt force trauma (both accidental and non-accidental), and (d) no trauma.

2.6 | Additional descriptive data

Age in weeks, birth data, history of trauma, and detailed results of neuroimaging and ophthalmological examination are reported at the individual level for the retinal haemorrhage cases.

2.7 | Statistics

Fisher's exact test was used to compare proportions, and the Wilcoxon rank sum test was used for comparisons of age. R version 1.2.1114 was employed for all calculations and graphical illustrations of descriptive statistics. A $p < 0.05$ was regarded as statistically significant.

2.8 | Ethics approval and consent to participate

The regional Ethical Review Board in Uppsala approved the study (2014-11-19 No 382). Approval for ordering medical records was obtained by the regional Ethical Review Board in Uppsala (2015-11-18 No 383/2) and by having the personal ID of the case medical records retrieved after each hospital's approval according to the Swedish Public Law and Privacy Act (2009:400).

3 | RESULTS

3.1 | General descriptive data

There was no difference in sex distribution between the 29 retinal haemorrhage (RH) cases and the 119 non-RH cases, 58% and 59% boys, respectively. Neither was there any statistically significant age difference between the two groups; the mean age in the RH infants was 104 - median age 82 (range, 16-355) days. Among the non-RH cases, the mean age was 140 - median age 116 (range, 3-349) days ($W = 2060.50$; $p = 0.09$) (Figure 1).

After exclusion of cases without intracranial pathology, the mean age for the retinal haemorrhage group was 108 days, and the median was 88 (range, 16-355) days. For the non-RH group, the mean age was 122 days, and the median was 119 (range, 19-294) days ($W = 210$; $p = 0.85$) (Figure 2).

3.2 | Reasons for seeking care

Neurological symptoms were the main reason for seeking care for all infants who had such symptoms, significantly more frequent in the retinal haemorrhage group (RH $n = 22$ of 29 [76%]; non-RH $n = 12$ of 119 [10%]; $p < 0.0001$). Other reasons for seeking care in both groups were increasing head circumference (RH group: $n = 4$ of 29 [14%]; non-RH group: $n = 3$ of 119 [2.5%]; $p = 0.03$), concern about possible injury after witnessed or admitted abuse by shaking or blunt head trauma (accidental or abusive; RH group: $n = 2$ of 29 [7%]; non-RH group: $n = 51$ of 119 [43%]; $p = 0.0002$), and symptomatic extracranial fractures (RH group: $n = 2$ of 29 [7%]; non-RH group: $n = 24$ of 119 [20%]; $p = 0.11$). In the non-RH group, seven infants were examined because a sibling had findings indicative of abuse, 17 were examined because of bruises, six because of incidental and asymptomatic skeletal findings on x-ray performed in the investigation of disease, two were referred for severe crying, and one because of burn injury. In two cases, the reason for seeking care remained unclear.

3.3 | Ocular and intracranial findings and neurological symptoms

Any kind of intracranial pathology was recorded in 15 (13%) of the 119 non-RH cases and in 27 (97%) of the 29 RH cases ($p < 0.0001$). All 19 infants with bilateral RH had intracranial pathology. Small and isolated RH was also found in two infants without intracranial pathology; a 3-week-old girl with spontaneous vaginal term delivery had two isolated RHs in one eye (Table S1 case 2). Shaking had been admitted,

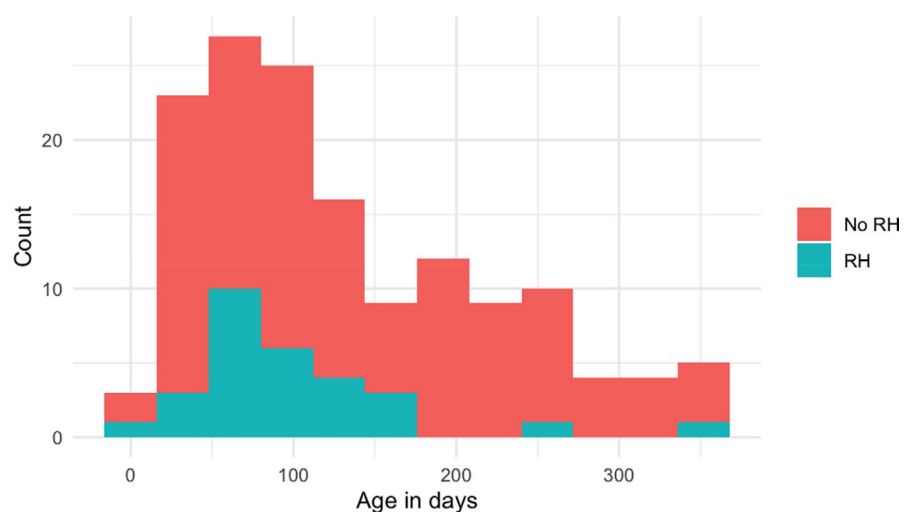


FIGURE 1 Age distribution in infants with ($n = 29$) and without ($n = 119$) retinal haemorrhage

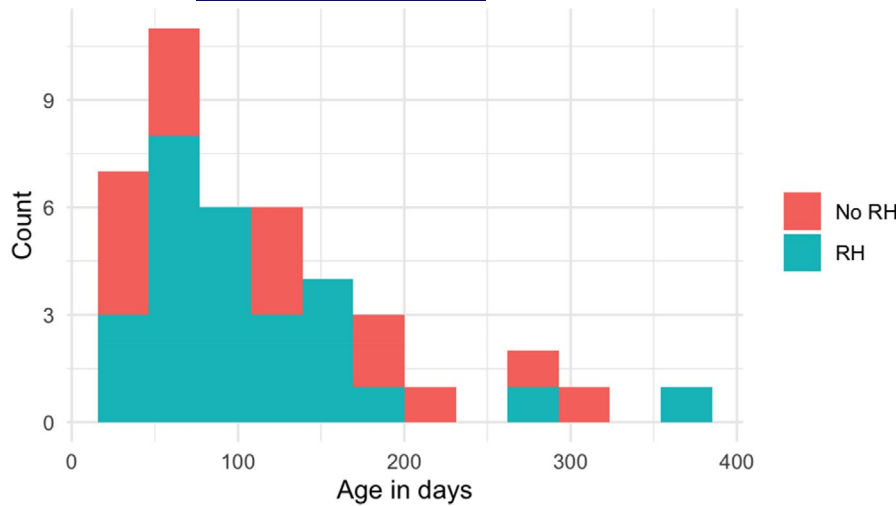


FIGURE 2 Age distribution of infants with intracranial pathology with retinal haemorrhage ($n = 27$) and without retinal haemorrhage ($n = 15$)

TABLE 1 Distribution of different kinds of intracranial pathology in infants with and without retinal haemorrhage

Intracranial pathology	No RH ($n = 119$)	RH all ($n = 29$)	RH bilateral ($n = 19$)	RH unilateral ($n = 10$)	Fisher's exact test ^a
Any kind	15 (13%)	27 (97%)	19 (100%)	8 (80%)	RH all: ($p < 0.0001$) RH bi: ($p < 0.0001$) RH uni: ($p < 0.0001$)
ASAH ^b	0	0	0		RH all:- RH bi:- RH uni:-
ASDH ^c	1 (0.8%)	1 (3%)	1 (5%)	0	RH all: ($p = 0.34$) RH bi: ($p = 0.11$) RH uni: -
CSDH ^d /hygroma	3 (2.5%)	10 (34%)	4(21%)	6 (60%)	RH all: ($p < 0.0001$) RH bi ($p = 0.001$) RH uni: ($p < 0.0001$)
Mixed ASDH and CSDH/hygroma with ASAH	3 (2.5%)	2 (7%)	2 (10%)	0	RH all: ($p = 0.27$) RH bi: ($p = 0.14$) RH uni:
Mixed ASDH and CSDH/hygroma without ASAH	7 (5.8%)	8 (28%)	8 (42%)	0	RH all: ($p = 0.002$) RH bi: ($p = 0.0001$) RH uni:-
ASAH and ASDH	1 (0.8%)	3 (7%)	2 (10%)	1 (10%)	RH all: ($p = 0.02$) RH bi: ($p < 0.05$) RH uni: ($p = 0.15$)
Other (Supplementary table case 2,10, 12, 15, 21)	0	5 (17%)	2 (10%)	3 (30%)	RH all:- RH bi:- RH uni:-

^a“No RH” is reference for all three RH groups.

^bAcute subarachnoid haemorrhage.

^cAcute subdural haemorrhage.

^dChronic subdural haemorrhage.

however without any recorded details of this shaking. The infant was asymptomatic, and the reason for seeking care was concern of possible injury caused by the admitted shaking. The other infant without intracranial pathology was an 11-week-old girl with a large head (head circumference +3 SD-Table S1 case 21). This infant had only a single RH in one eye. There were no neurological symptoms, and the reason for seeking care was a symptomatic femur shaft fracture.

Follow-up retinal examinations were reported in only one case—an 11-week-old girl with a chronic subdural haemorrhage that was surgically decompressed twice, first on day 2, and who later developed hydrocephalus (Table S1 case 14). At the first examination, there were discrete retinal haemorrhages in one eye; on the second examination 5 days later and after the child had been transferred to foster care, new RHs had developed in the posterior pole of the

same eye. On the third examination on day 14, all RHs had resolved—this infant was shunted because of hydrocephalus.

Papillary oedema was rare, described in only three cases, all in the retinal haemorrhage group (Table S1 cases 11, 17, and 23). One had a chronic subdural haemorrhage/hygroma without any component of acute haemorrhage; the two others had mixed density—unilateral subdural haemorrhage and tense fontanelles. The reason for seeking care was increasing head size in case 23 and vomiting, seizures, and reduced level of consciousness in the other two cases.

3.4 | Nature of intracranial pathology

For details regarding the types of intracranial pathology and their distribution between the two patient groups, see Table 1. A total of 42 of 148 infants had an intracranial pathological condition; in 40 cases this consisted of extra cerebral fluid collections containing blood elements. The great majority ($n = 33$, 82.5%) of these had blood elements indicating chronicity (chronic subdural haemorrhage/hygroma or mixed density chronic and acute subdural haemorrhage with or without acute subarachnoid haemorrhage). Isolated acute subarachnoid haemorrhage was not described in any of the cases, and acute subdural haemorrhage (with or without acute subarachnoid haemorrhage) was rare in both groups, four (14%) in the retinal haemorrhage group and two (1.7%) in the non-retinal haemorrhage group. Chronic subdural haemorrhage/hygroma as well as mixed density acute subdural haemorrhage and chronic subdural haemorrhage/hygroma was strongly associated with retinal haemorrhage, which applies also to when the isolated unilateral retinal haemorrhage group is analysed separately. Three infants had intracranial pathology other than, or in addition to subdural effusions. These were brain oedema (Table S1 case 12), contusion, intracerebral haemorrhage and chronic subdural haemorrhage (Table S1 case 10), and contusion (Table S1 case 15).

In three of the retinal haemorrhage cases (Table S1 cases 25, 28, and 29) and four of the non-RH cases, increased subarachnoid space and/or increased ventricle size were noted in the radiologist's report.

3.5 | Raised intracranial pressure

A comparison of findings indicative of raised intracranial pressure (see Material and Methods for definitions) in infants with intracranial pathology showed that 16 of 27 (59%) in the retinal haemorrhage group and 4 of 15 (27%) in the non-RH group had such findings ($p = 0.06$). Neurological symptoms (vomiting, seizures, lowered level of consciousness, apnoea) were recorded in 22 (76%) of the 29 RH cases and in 12 (10%) of the 119 non-RH cases ($p < 0.0001$). Those with unilateral vs. bilateral RHs differed significantly with respect to the presence of neurological symptoms compatible with raised intracranial pressure (5 unilateral [45%] vs.

17 bilateral [94%]; $p = 0.006$) and clinical and radiological findings indicating raised intracranial pressure (3 unilateral RH [30%] vs 13 bilateral RH [68%]; $p = 0.01$). Of the 29 infants with RH, 12 (41%) had both objective clinical/radiological findings and neurological symptoms compatible with raised intracranial pressure. Twenty-six (90%) of the 29 infants with RH had any combination of objective signs and/or neurological symptoms consistent with raised intracranial pressure.

Witnessed or admitted physical abuse of any kind was reported in 35 (29%) of the 119 non-RH cases and in two (7%) of the 29 RH cases ($p = 0.005$).

Of 27 infants subjected to witnessed or admitted shaking with ($n = 4$) or without ($n = 23$) blunt force impact, one had bilateral retinal haemorrhage. This infant also had intracranial pathology, including ASDH, acute subarachnoid haemorrhage, suspected small chronic subdural haemorrhage, suspected cortical vein thrombosis, and non-specific white matter changes. Another vaginally delivered 3-week-old infant subjected to abusive shaking had two isolated retinal haemorrhages without intracranial pathology.

3.6 | Other cranial findings

Three children, 3, 6, and 8 weeks old, in the retinal haemorrhage group had bruising and/or soft tissue swelling in the scalp with underlying skull fracture. Two infants, 24 and 25 weeks old, in the RH group had a skull fracture without a bruise or soft tissue swelling. Thus, five infants of 29 (17%) in the retinal haemorrhage group had a skull fracture. In the non-RH group, 18 of 119 (15%, mean age 16 weeks, median 15 weeks, range 0–33 weeks) had a skull fracture, 10 also with a related soft tissue injury and 3 with intracranial pathology (one chronic subdural haemorrhage, and two acute subdural haemorrhage). Nine additional infants had scalp hematoma without fracture in the non-RH group, one of whom had intracranial pathology (chronic subdural haemorrhage with high attenuating components interpreted as fresh blood).

3.7 | Reported type of trauma

Witnessed or admitted shaking without blunt force impact was reported in one (3%) of the 29 retinal haemorrhage cases (3-week-old vaginally delivered infant with unilateral RH and no intracranial pathology, Table S1 case 2) and in 22 (18%) of the 119 non-RH cases ($p = 0.05$). Witnessed or admitted shaking with blunt force was reported in one (3%) of the 29 RH cases (Table S1 case 3) and in three (2.5%) of the 119 non-RH cases.

Witnessed or admitted/reported blunt force was documented in nine (31%; abusive in 2, accidental in 7) of the 29 retinal haemorrhage cases and in 38 (32%; abusive in 26, accidental in 12) of the 119 non-RH cases.

In the 15 infants who had intracranial pathology without retinal haemorrhage, shaking with or without blunt force trauma was

not reported. Blunt force trauma (all accidental falls) was reported in eight of these cases. In six of the cases, no history of trauma was given. In the last case, a neighbour had informed the social authority of maltreatment, but there was no information about trauma in the medical records.

4 | DISCUSSION

4.1 | Principal findings

In the present study, there was a strong association between retinal haemorrhage and intracranial pathological conditions in infants with suspected shaken baby syndrome/abusive head trauma. Almost all (97%) infants with retinal haemorrhage also had intracranial pathology, whereas only a small proportion (13%) without retinal haemorrhage did so. Conversely, a large proportion (62%) of infants with intracranial pathology also had retinal haemorrhage. Retinal haemorrhage without intracranial pathology was found in only two cases. In both, the retinal haemorrhages (one in one infant, two in the other, Table S1 case 1 and case 2) were unilateral. The retinal haemorrhages in the 3 week old infant (Case 2) may have originated at birth since retinal haemorrhages may resolve over a period of several weeks.^{17,18} For infants harbouring bilateral retinal haemorrhage, the association with intracranial pathology was absolute.

4.2 | Reasons for seeking care

There were large differences between the groups regarding what symptoms and findings that caused care givers to seek health care. For the retinal haemorrhage group, the reasons appeared in general to reflect more serious intracranial condition than the reasons given by the care givers in the non-RH group; neurological symptoms and increasing HC were significantly more common as reason for referral in the RH group, whereas concern that shaking alone or together with blunt head trauma had caused an injury was much more frequent in the non-RH group.

There was an overweight of objective findings of injury in the non-RH group too; however, these did not indicate severe *intracranial* conditions, but with extracranial locations, such as extracranial fractures, bruises, and incidental and asymptomatic skeletal x-ray abnormalities found during investigation of diseases. Moreover, some infants were examined because siblings had findings suggesting abuse.

4.3 | Mechanism of retinal haemorrhage

As discussed in the Introduction, the aim of the present comparative case series study was to test the two prevailing hypotheses of the mechanism of non-birth-related infantile retinal haemorrhages: vitreoretinal traction vs. leakage from congested retinal veins secondary

to intracranial conditions. The fundamental predicted consequence of the latter hypothesis is that cases involving retinal haemorrhage should also have intracranial pathology, which was the case in our series. However, such an association does not necessarily prove causality. Unfortunately, follow-up ocular examination was reported in only one infant (Table S1 case 14) and demonstrated that new retinal haemorrhages did develop after the infant had been transferred to foster care. This finding indicates that the infant's retinal haemorrhage was secondary to the intracranial pathology and not caused by any direct, physical effects on the intraocular contents. In other words, the intracranial pathology preceded the retinal haemorrhage, and this finding supports the notion of causality between the two. In our study, findings indicative of raised intracranial pressure were significantly overrepresented in infants with bilateral RH compared with those having only unilateral retinal haemorrhage, suggesting a dose-response relationship that supports causality.

A study of children age <2 years with retinal haemorrhage showed that extensive retinal haemorrhage resolves to being not visible or mild within 1 to 2 weeks and does not persist as extensive for longer than a few days.¹⁹ Thus, if the chain of causality repeated shaking-vitreoretinal traction-retinal haemorrhage is valid, the concomitant intracranial pathology would be expected to be acute. However, in our series, five infants with bilateral retinal haemorrhage had chronic subdural haemorrhage/hygroma without any component of fresh blood. This finding is incompatible with a simultaneous development of intracranial and ocular pathology but is compatible with retinal haemorrhage being secondary to intracranial pathology leading to intraocular vascular leakage. An association between non-acute intracranial pathology and retinal haemorrhage (also extensive) has previously been noted in infants with hygroma and external hydrocephalus.^{11-13,16} Four infants in the present study had purely high density subdural haemorrhage on computer tomography, which would normally indicate acute subdural haemorrhage, and two of these infants also had acute subarachnoid haemorrhage. This observation might lead to the conclusion that the retinal haemorrhages and the intracranial pathology appeared at the same time, in other words that the two were independent of each other. However, because neuroimaging and ocular examinations were not performed in immediate connection to the infant showing signs of encephalopathy, the possibility of the retinal haemorrhages being secondary to intracranial pathology still remains.

Of 27 infants subjected to witnessed or admitted shaking, only one had bilateral retinal haemorrhage, and this infant was preterm with both chronic and acute intracranial conditions. Thus, retinal haemorrhage as a consequence of vitreoretinal traction does not gain support from the results of the present study.

4.4 | Raised intracranial pressure

Although assuming that infant retinal haemorrhage is secondary to intracranial pathology, as our results indicate, the precise mechanism of the retinal haemorrhage cannot be determined from the study data. However, the high proportion (90%) of infants with retinal

haemorrhage who also had findings or symptoms indicative of raised intracranial pressure suggests that this factor is important in retinal haemorrhage pathogenesis. It has been suggested that a rapid rise in intracranial pressure leads to decreased venous drainage of the eyes, resulting in vitreous hypertension and retinal or vitreous haemorrhage in adults.²¹⁻²³ Mena et al.¹⁰ have suggested that the same mechanism may explain retinal haemorrhage in infants. This mechanism is consistent with the high proportion of mixed density-density subdural effusions in cases of retinal haemorrhage in the present study. A chronic subdural haemorrhage/hygroma or external hydrocephalus may be complicated by a spontaneous acute haemorrhage,^{11,12,23-26} and a recent case report provides convincing evidence that such complications can cause extensive retinal haemorrhage.⁷

As is well known, raised intracranial pressure can lead to symptoms of encephalopathy, such as seizures, reduced level of consciousness, impaired breathing, and vomiting. Thus, a rise in the intracranial pressure from an acute haemorrhage in a chronic subdural haemorrhage or as a complication of external hydrocephalus may trigger symptoms such as vomiting, seizures, intense crying, or apnoea. These in turn may add to venous congestion by the Valsalva mechanism (vomiting, seizures) or increased brain perfusion as a response to hypoxia. In a study describing signs of progressive hydrocephalus in 107 children, 33 of whom were infants, retinal haemorrhage was not described in any case.²⁷ This observation seems to be in line with the hypothesis that retinal haemorrhage results from a rapid rise in the intracranial pressure rather than a slowly developing raised intracranial pressure over days, as suggested by Walsh and Hedges.²⁸ The cavernous sinuses are not developed until about 6-7 months age and the venous drainage occurs via anastomoses to the face and nasopharynx veins.²⁹ Perhaps this anatomical feature in the young infants makes them more prone to develop retinal haemorrhage in connection with a rapid raise of intracranial pressure.

4.5 | The lack of papillary oedema

Although the large majority (90%) of our infants with retinal haemorrhage had signs and/or symptoms of raised intracranial pressure, papillary oedema was described in very few (11%). Because some of the infants without papilledema in the present study had raised intracranial pressure verified by objective measures during neurosurgery, the non-presence of papilledema seems to be of limited value for ruling out raised intracranial pressure in infants with retinal haemorrhage. Unfortunately, very few studies exist on the presence of papilledema in infants with raised intracranial pressure. A rare occurrence of papilledema with probable raised intracranial pressure has earlier been described among infants with both non-shunted and shunted progressive hydrocephalus. In that study, 2 out of 33 (6%) had papillary oedema, whereas other signs of raised intracranial pressure such as tense fontanelle and splayed sutures were much more common.²⁷ Furthermore, studies on the optic nerve sheath diameter (ONSD) and intracranial pressure have demonstrated that a pathologically widened ONSD is rare in young infants as long as

the fontanels are open.^{30,31} However, in infants/children with closed fontanels, the ONSD correlated well with the intracranial pressure elevation. As a widened ONSD most likely is a prerequisite for papilledema, the lack of papilledema in our infants can therefore not be taken as a sign of a normal intracranial pressure.

4.6 | Medico-legal implications

The results of the present comprehensive case series study suggest that non-birth-related retinal haemorrhages in infants are secondary to traumatic or non-traumatic intracranial pathology associated with raised intracranial pressure and that isolated shaking is unlikely to cause retinal haemorrhage independently of intracranial pathology. Consequently, the presence of retinal haemorrhage provides no reliable information about the aetiology of the intracranial pathology, and abusive head trauma cannot be inferred solely based on the combination of the two.

To move towards evidence-based medico-legal assessment of the aetiology of infant intracranial pathology, the examination needs to include risk factors for intracranial pathology, such as prematurity, small for gestational age, and multiparity,³² and markers of benign external hydrocephalus, such as rapid increase in head size and certain radiological findings.³³ The neuroradiological examination should also include state-of-the-art procedures for detecting signs of vascular malformations and cerebral venous thrombosis.

4.7 | Strengths and limitations

To avoid a spurious correlation between intracranial pathology and retinal haemorrhage, the primary inclusion criterion in this study was that infants had to have been examined for the suspicion of maltreatment, irrespective of the findings. A drawback with this selection procedure is that infants with symptomatic intracranial pathology related to trauma corroborated by independent (not by acquaintance) observation were few, and cases related to diagnosed disease or vascular malformation were not included by definition, since shaken baby syndrome/abusive head trauma is regarded as a diagnosis by exclusion of non-traumatic causes.

A strength of the present study is the national coverage over a long period of 18 years, making it possible to identify several cases of suspected maltreatment examined by both neuroimaging and fundoscopy. As is always the case, the retrospective study design has its limitations. The quality of the information in the medical records is far from uniform with respect to descriptions of traumatic events, neuroimaging, and ocular examination, with the last variable especially making systematic grading of the pattern and extent of retinal haemorrhage beyond unilateral vs. bilateral impossible.

The retrospective design also means failure to retrieve medical records for all identified cases. The reason for the hospital turning down requisitions is unclear, but selection bias from findings or circumstances unique to the non-provided cases seems unlikely.

5 | CONCLUSION

The results of the present study indicate that non-birth-related retinal haemorrhage in infants are secondary to intracranial pathology associated with raised intracranial pressure, which may be of traumatic or non-traumatic origin and not the result of traction forces between the retina and vitreous body acting directly on the retinal vessels. Consequently, the presence or non-presence of RH cannot be regarded as a reliable basis for determining the underlying aetiology of the intracranial pathology. Furthermore, retinal haemorrhage is likely to have low sensitivity for detecting head trauma and thus also for ruling out infant maltreatment, making them of limited value in the investigation of suspected infant abuse.

CONFLICT OF INTEREST

Ingemar Thiblin, Ulf Högberg, and Knut Wester have written statements and appeared in court in child abuse cases both on the request of the prosecutor or the court and the defence. Göran Högberg has written statements and appeared in court in child abuse cases on the request of the defence.

ORCID

Ingemar Thiblin  <https://orcid.org/0000-0002-2962-2466>

Jacob Andersson  <https://orcid.org/0000-0001-8266-1926>

Knut Wester  <https://orcid.org/0000-0001-8489-3931>

Ulf Högberg  <https://orcid.org/0000-0002-2121-7511>

REFERENCES

1. Levin AV. Retinal hemorrhage in abusive head trauma. *Pediatrics*. 2010;126(5):961-970.
2. Christian CW. Committee on child abuse and neglect, American academy of pediatrics. the evaluation of suspected child physical abuse. *Pediatrics*. 2015;135(5):e1337-e1354. <https://doi.org/10.1542/peds.2015-0356>. ISSN 0031-4005, 1098-4275.
3. Rao N, Smith RE, Choi JH, Xiaohu X, Kornblum RN. Autopsy findings in the eyes of fourteen fatally abused children. *Forensic Sci Int*. 1988;39(3):293-299.
4. Tomasi LG. Purtscher retinopathy in the battered child syndrome. *Arch Pediatr Adolesc Med*. 1975;129(11):1335.
5. Emerson MV, Jakobs E, Green WR. Ocular autopsy and histopathologic features of child abuse. *Ophthalmology*. 2007;114(7):1384-1394.
6. Atkinson N, van Rijn RR, Starling SP. Childhood falls with occipital impacts. *Pediatr Emerg Care*. 2018;34(12):837-841.
7. Aoki N. Infantile acute subdural hematoma with retinal hemorrhage caused by minor occipital impact witnessed by an ICU Nurse: a case report. *J Pediatr Neurol Neurosci*. 2020;4(1):47-50.
8. Vinchon M, Noizet O, Defoort-Dhellemmes S, Soto-Ares G, Dhellemmes P. Infantile subdural hematomas due to traffic accidents. *Pediatr Neurosurg*. 2002;37(5):245-253.
9. Kivlin JD, Currie ML, Greenbaum V, et al. Retinal hemorrhages in children following fatal motor vehicle crashes: a case series. *Arch Ophthalmol*. 2008;126(6):800-804.
10. Mena OJ, Paul I, Reichard RR. Ocular Findings in raised intracranial pressure: a case of Terson syndrome in a 7-month-old infant. *Am J Forensic Med Pathol*. 2011;32(1):55-57.
11. Scheller J. Infantile retinal hemorrhages in the absence of brain and bodily injury. *Acta Paediatr*. 2017;106(12):1902-1904.
12. Wester K. Two infant boys misdiagnosed as "shaken baby" and their twin sisters: a cautionary tale. *Pediatr Neurol*. 2019;97:3-11.
13. Scheller J. An unexpected cause of bilateral retinal hemorrhage in a four-month-old boy. *Pediatr Neurol*. 2018;78:79. <https://doi.org/10.1016/j.pediatrneurol.2017.07.015>
14. Salvatori MC, Lantz PE. Retinal hemorrhages associated with fatal paediatric infections. *Med Sci Law*. 2015;55(2):121-128. PMID: 24644226.
15. Maguire SA, Watts PO, Shaw AD, et al. Retinal hemorrhages and related findings in abusive and non-abusive head trauma: a systematic review. *Eye Lond Engl*. 2013;27(1):28-36.
16. Maytal J, Alvarez LA, Elkin CM, Shinnar S. External hydrocephalus: radiologic spectrum and differentiation from cerebral atrophy. *AJR Am J Roentgenol*. 1987;148(6):1223-1230.
17. Naderian G, Fesharaki H, Sajjadi V, et al. Retinal hemorrhages in a neonate following vacuum extraction. *J Ophthalmic vis Res*. 2013;8(2):179-181.
18. Watts P, Maguire S, Kwok T, et al. Newborn retinal hemorrhages: a systematic review. *J AAPOS*. 2013;17(1):70-78.
19. Binenbaum G, Chen W, Huang J, Ying G-s, Forbes BJ. The natural history of retinal hemorrhage in pediatric head trauma. *J Am Assoc Pediatr Ophthalmol Strabismus*. 2016;20(2):131-135.
20. Lee HC, Chong S, Lee JY, et al. Benign extracerebral fluid collection complicated by subdural hematoma and fluid collection: clinical characteristics and management. *Childs Nerv Syst*. 2018;34(2):235-245.
21. Muller PJ, Deck JHN. Intraocular and optic nerve sheath hemorrhage in cases of sudden intracranial hypertension. *J Neurosurg*. 1974;41(2):160-166.
22. Medele RJ, Stummer W, Mueller AJ, Steiger H-J, Reulen H-J. Terson's syndrome in subarachnoid hemorrhage and severe brain injury accompanied by acutely raised intracranial pressure. *J Neurosurg*. 1998;88(5):851-854.
23. Vinchon M, Delestret I, DeFoort-Dhellemmes S, Desurmont M, Noulé N. Subdural hematoma in infants: can it occur spontaneously? Data from a prospective series and critical review of the literature. *Child's Nerv Syst*. 2010;26(9):1195-1205.
24. Laubscher B, Deonna T, Uske A, van Melle G. Primitive megalencephaly in children: natural history, medium term prognosis with special reference to external hydrocephalus. *Eur J Pediatr*. 1990;149(7):502-507.
25. Hellbusch LC. Benign extracerebral fluid collections in infancy: clinical presentation and long-term follow-up. *J Neurosurg Pediatr*. 2007;107(2):119-125.
26. Ghosh PS, Ghosh D. Subdural hematoma in infants without accidental or nonaccidental injury: benign external hydrocephalus, a risk factor. *Clin Pediatr (Phila)*. 2011;50(10):897-903.
27. Kirkpatrick M, Engleman H, Minns RA. Symptoms and signs of progressive hydrocephalus. *Arch Dis Child*. 1989;64(1):124-128.
28. Walsh FB, Hedges TR. Optic nerve sheath hemorrhage. *Am J Ophthalmol*. 1951;34(4):509-527.
29. Chow MSM, Wu SL, Hui V, Chow TCH, Yew DT. Revisit the cavernous sinus from fetus to adult—new an old data. *Anat Rec*. 2018;301:819-824.
30. Kerscher SR, Schöni D, Hurth H, et al. The relation of optic nerve sheath diameter (ONSD) and intracranial pressure (ICP) in pediatric neurosurgery practice - Part I: Correlations, age-dependency and cut-off values. *Child's Nervous System*. 2020;36(1):99-106.
31. Kerscher SR, Schöni D, Neunhoffer F, et al. The relation of optic nerve sheath diameter (ONSD) and intracranial pressure (ICP) in pediatric neurosurgery practice—Part II: Influence of wakefulness, method of ICP measurement, intra-individual ONSD-ICP correlation and changes after therapy. *Child's Nervous System*. 2020;36(1):107-115.

32. Högberg U, Andersson J, Squier W, et al. Epidemiology of subdural hemorrhage during infancy: a population-based register study. *PLoS One*. 2018;13(10):e0206340. <https://doi.org/10.1371/journal.pone.0206340>
33. Zahl SM, Egge A, Helseth E, Wester K. Benign external hydrocephalus: a review, with emphasis on management. *Neurosurg Rev*. 2011;34(4):417-432.

How to cite this article: Thiblin I, Andersson J, Wester K, Högberg G, Högberg U. Retinal haemorrhage in infants investigated for suspected maltreatment is strongly correlated with intracranial pathology. *Acta Paediatr*. 2021;00:1-9. <https://doi.org/10.1111/apa.16139>

SUPPORTING INFORMATION

Additional supporting information may be found in the online version of the article at the publisher's website.