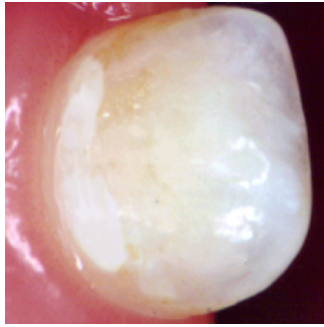


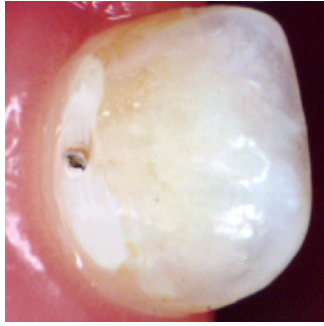
Appendix II

Fig. 1. Criteria for five-graded severity registration of caries on different surfaces.

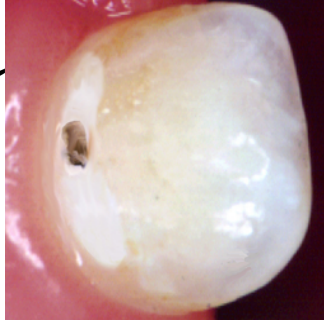BUCCAL AND LINGUAL CARRIES (CLINICAL RECORDINGS)



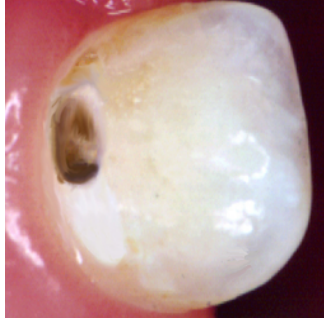
GRADE 1 (B1)
White or discolored enamel. No cavitation clinically.



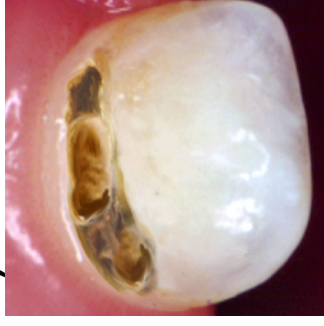GRADE 2 (B2)
Small cavitation in enamel.



GRADE 3 (B3)
Moderate sized cavity in enamel with exposed dentin (verified by probing).

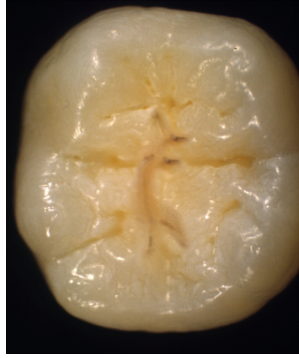

GRADE 4 (B4)
Large cavity in enamel and moderate cavity in dentin.

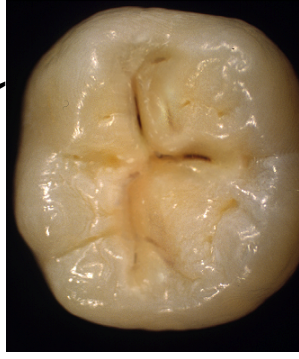


GRADE 5 (B5)
Extensive cavity in enamel and substantial loss of dentin.

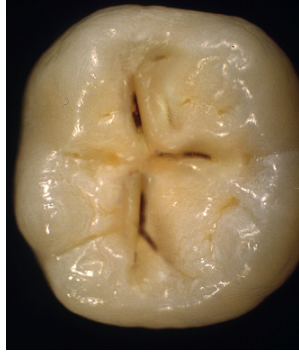OCCLUSAL CARRIES (CLINICAL AND RADIOGRAPHIC RECORDINGS)



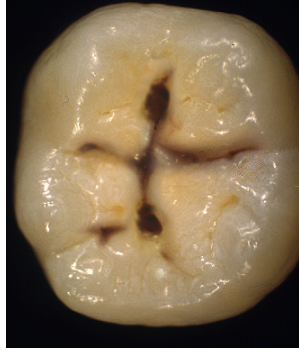GRADE 1 (O1)
White or brown discoloration in enamel. No clinical cavitation. No radiographic evidence of caries.



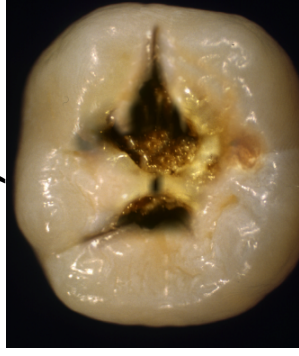
GRADE 2 (O2)
Small cavity formation, or discoloration of the fissure with surrounding grey/opaque enamel and/or radiolucency in enamel on radiograph.



GRADE 3 (O3)
Moderate sized cavity and/or radiolucency in the outer third of dentin.

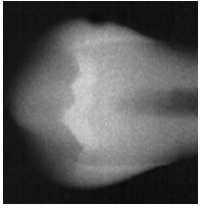


GRADE 4 (O4)
Big cavitation and/or radiolucency in the middle third of dentin.

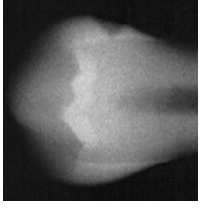


GRADE 5 (O5)
Very big cavity and/or radiolucency in the inner third of dentin.

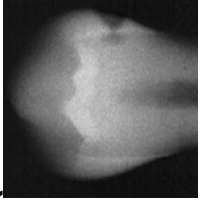
APPROXIMAL CARIES (RADIOGRAPHIC RECORDINGS)



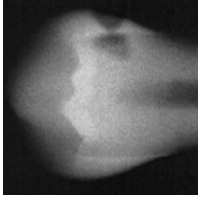
GRADE 1 (A1)
Radiolucency in outer half of enamel.



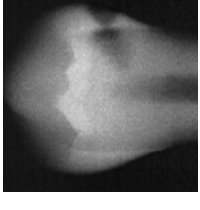
GRADE 2 (A2)
Radiolucency in inner half of enamel.



GRADE 3 (A3)
Radiolucency in the outer third of dentin.



GRADE 4 (A4)
Radiolucency in the middle third of dentin.



GRADE 5 (A5)
Radiolucency in the inner third of dentin.