

Paper I

Phosphorylcholine-Coated Metallic Stents in Rabbit Iliac and Porcine Coronary Arteries

Karel K. J. Kuiper,¹ Keith A. Robinson,² Nicolas A. F. Chronos,² Jianhua Cui,² Spencer J. Palmer² and Jan Erik Nordrehaug¹

From the ¹Department of Heart Disease, Haukeland University Hospital, Bergen, Norway and ²Andreas Gruentzig Cardiovascular Center, Department of Medicine (Cardiology), Emory University School of Medicine, Atlanta, Georgia, USA

(Submitted February 10, 1998. Accepted for publication March 27, 1998)

Scand Cardiovasc J 32; 261–268, 1998

The arterial wall reaction to phosphorylcholine-coated metal stents was examined in rabbits and pigs. Compared to non-coated stents, no significant difference was found by angiography and histology. We conclude that although phosphorylcholine-coating does not provoke arterial neointima formation or decrease luminal diameter compared to stainless steel stents, the coating does not seem to reduce restenosis.

Key words: angioplasty, pig, rabbit, phosphorylcholine-coating, stents.

Karel K. J. Kuiper, MD, Department of Heart Disease, Haukeland University Hospital, N-5021 Bergen, Norway, Tel + 47 55 97 22 20. Fax + 47 55 97 51 50. E-mail: Karel.K.Kuiper@hjerte.haukeland.no

The development of serious intimal hyperplasia is a current limitation to the clinical success of coronary metal stents. Restenosis after stenting has been reported in about 20%–30% of patients (1, 2), with an even higher frequency in smaller arteries. Improved stent implantation techniques and the use of newer antiplatelet drugs such as ticlopidine have reduced the occurrence of stent thrombosis and femoral artery bleeding complications (3–8). However, stent thrombosis is still a problem with the use of metal stents and implantation in smaller arteries is not recommended. A number of stent coatings and biodegradable stents have been developed to overcome these problems (9–15), some of which have provoked serious intimal hyperplasia in animal models (10, 11, 13). Ideally, a stent coating should be non-thrombogenic and should reduce restenosis itself or be capable of binding drugs that can act locally on the vessel wall to reduce restenosis.

Phosphorylcholine (PC) is the most abundant phospholipid in the outer layer of the plasma membrane of erythrocytes and thrombocytes, making their external surface non-thrombotic. PC derivatives have been synthesized to coat medical devices which are in contact with blood and have been reported to be non-thrombogenic (16, 17). In the present study we sought to investigate whether the arterial wall thickening and luminal reduction were less with a PC-coating on coronary stents compared to stainless steel stents alone,

when implanted in rabbit iliac arteries and in porcine coronary arteries.

METHODS

PC-coating

The coating is composed of methacrylate polymers which serve as a backbone to which PC is attached. Phosphorylcholine is a zwitterion and binds water, which makes the coated surface non-thrombogenic. The coating binds strongly to metal. Slotted tube stainless steel Palmaz-Schatz stents[®], PS 153 (Johnson & Johnson) were coated with PC by BCP Dilatec Inc., UK.

The investigation conforms with the *Guide for the Care and Use of Laboratory Animals* and the study protocol was approved by the local ethical committee for animal care and use. All animals were fed on a standard chow diet without cholesterol supplementation.

Rabbit study protocol

Eight male Chinchilla rabbits Chbb:CH (weight 3.9 ± 0.5 kg) underwent transcatheter balloon angioplasty stent placement of both iliac arteries. Sedation was induced by 0.5 ml fentanyl (0.315 mg/ml)/fluanisone (10 mg/ml) (Hypnorm[®]) intramuscularly. General anesthesia was achieved by giving 4 mg/kg

diazepam intraperitoneally and maintained by supplemental doses of 0.5 ml diazepam and fentanyl/fluanisone in a 1:1 combination. After infiltrating the skin with 0.5% xylocaine for local anesthesia, the right carotid artery was exposed and a 5F sheath was inserted and anchored with ligatures. A bolus of 100 IU/kg heparin was administered intra-arterially. A PC-coated and a non-coated stent were randomized to implantation in the right or left iliac artery at anatomically comparable sites. The stents were mounted on a 2.5 mm semi-compliant angioplasty balloon catheter and deployed at 8 atmospheres for 30 s; the ilio-sacral joint served as an anatomic landmark over which the radiopaque balloon marker was placed. Angiography was performed in the frontal view to assess patency of both arteries, using a 4F catheter and injecting 3 ml of ioxaglate (Hexabrix®) as contrast medium. A 2.5 mm balloon angioplasty catheter dilated to 6 atmospheres (rated diameter 2.5 mm) was placed on the caudal part of the abdomen, in plane with the iliac arteries for calibration for subsequent quantitative analysis. The procedure was completed by ligating the carotid artery and by closing the subcutis and the skin with separate ligatures; subsequently the animals were allowed to recover. Buprenorfin 0.3 mg (Temgesic®) and penicillin were given once daily for the first 2 to 3 days. No antithrombotic medication was given during follow-up.

Repeat angiography was performed after 4 weeks, following the same procedure as for the initial operation, but inserting a sheath into the left carotid artery. After angiography, a laparotomy was performed and the abdominal aorta was cannulated with an 18G infusion-needle. The animals were killed by administering an overdose of pentobarbital intra-arterially via the sheath in the left carotid artery. The iliac arteries were perfusion fixed antegrade with buffered 2% glutaraldehyde at a pressure of 100 mmHg for 15 min with a cannula in the inferior caval vein as efflux. The stented parts of the arteries were excised and immersed in 2% glutaraldehyde overnight.

Swine study protocol

Ten swine (*Sus scrofa*, 8 full-grown Göttingen mini-pigs, weight 20–22 kg and 2 juvenile Norhybrid domestic swine, weight 32–36 kg) were implanted with a PC-coated and a non-coated stent, randomized to the left anterior descending artery (LAD) or the left circumflex artery (LCx). A single dose of 330 mg acetylsalicylic acid was administered orally the night before the procedure. Anesthesia was induced by giving ketamine 10 mg/kg (Ketalar®), medetomidine 0.1 mg/kg (Dormitor®) and atropine 0.03 mg/kg intramuscularly. On adequate sedation, the pig was transported to the operation theater and isoflurane was given in a mixture of O₂/NO₂ (1:1) by nose cone

until the animal was sufficiently relaxed to allow endotracheal intubation. Anesthesia was maintained by 1–1.5% isoflurane in O₂/air. Electrodes were placed on the chest for continuous electrocardiographic monitoring. After infiltrating the skin with 0.5% xylocaine, the right femoral artery was exposed and an 8F sheath was inserted and secured with ligatures. A bolus of 100 IU/kg of heparin was administered intra-arterially. A multipurpose hockeystick catheter served as guiding catheter. Angiography was performed from three standard views: anterior-posterior, right and left oblique view (30°) using ioxaglate (Hexabrix®) as contrast medium. First, the coated stent was deployed after advancing a 0.014-inch floppy guide wire into the proximal part of either the LAD or the LCx according to randomization. The stent was mounted on a 3.0 mm diameter compliant angioplasty balloon catheter and dilated at a final pressure of 12 atmospheres over 20 s. Thereafter, the control non-coated stent was implanted proximally in the other artery using the identical type of balloon catheter at the same pressure and inflation time. Another angiography was performed from identical views to assess vessel patency. The femoral artery was ligated and the subcutis and skin closed with separate ligatures. About 30 min before conclusion of the procedure, intramuscular diazepam 1 mg/kg and buprenorfin 0.05 mg/kg (Temgesic®) was given and the animals were thereafter permitted to recover. Buprenorfin (Temgesic®) was given every 12th hour for the first 2 to 3 days. A penicillin/streptomycin combination was given for 3 to 4 days to prevent post-procedure infections. No antithrombotic medication was given during follow-up.

After 4 weeks the animals were anesthetized using the same protocol as for the first procedure. A 6F sheath was inserted in the left femoral artery. Control angiography was performed from identical views as for the first procedure, using a hockeystick catheter and ioxaglate (Hexabrix®) as contrast medium. The pigs were then killed by administering an overdose of intra-arterial potassium chloride, the hearts were excised and the coronary vasculature perfusion fixed at 100 mmHg for 15 min with buffered 2% glutaraldehyde.

Quantitative angiography

In the rabbit studies the angiography frame with maximal opacification was stored for subsequent quantitative analysis, which was performed with a digital electronic caliper (Sandhill, model EC-1) (18), using a 2.5 mm balloon angioplasty catheter inflated at 6 atmospheres for calibration. Repeat angiography in the rabbit study was also performed with a Siemens angiography system with a fully computerized digital quantitative angiography system (AWOS). Lumen area of the stents was analyzed by videodensitometry. For

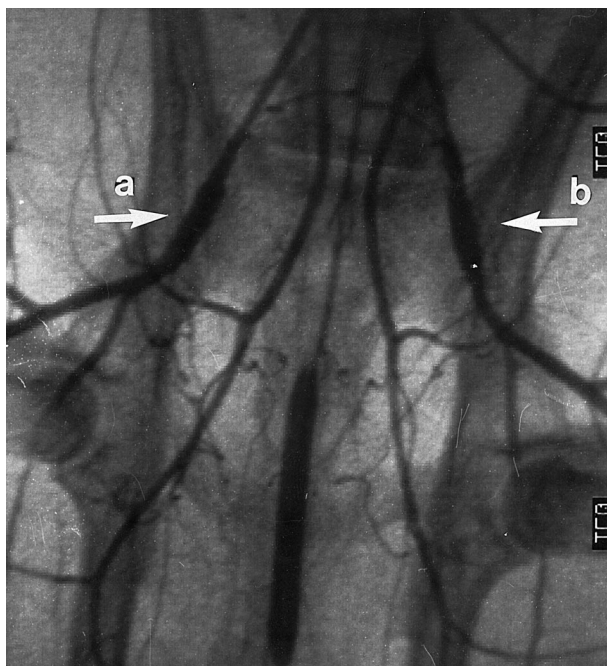


Fig. 1. Follow-up angiography after 4 weeks of phosphorylcholine-coated (a) and non-coated (b) stent in rabbit iliac artery. A stent is indicated by the arrow.

the pig study, single matched "best views" from the angiography images were selected for digital quantitative analysis. Stenosis diameter (minimal luminal diameter in the stent) and reference vessel diameter were measured, and percent stenosis was calculated. The guiding catheter served for calibration.

Histology

Stented artery segments were stored in 0.1 M cacodylate buffer until further processing. They were dehydrated in graded ethanol series to 100% and infiltrated and embedded in methyl methacrylate or a mixture of hydroxyethyl methacrylate, hydroxypropyl methacrylate, and butylmethacrylate. After polymerization the blocks were cut into 0.3 mm cross-sections from several sites per stent using a diamond-tipped rotary saw (Buehler) and glued to acrylic slides. The sections were then ground to 30–50 μm and stained with paragon/toluidine blue. Computer-assisted planimetry was used to measure luminal area, vessel-wall area

(area within external elastic lamina), intimal area and maximal intimal thickness.

Statistical analysis

All data are presented as mean \pm standard deviation (SD). Student's *t* test was used to compare minimal luminal diameter and stenosis between the two stent groups and within each stent group at subsequent time intervals. Data not normally distributed (histological data) were analyzed by Mann-Whitney *U* test. Mean values were considered significantly different when a two-tailed *p*-value was < 0.05 .

RESULTS

Rabbit study

All the stents were deployed without complications. During follow-up, none of the animals revealed signs of inferior limb arterial insufficiency. Repeat angiography showed that no thrombotic stent occlusion had occurred (Fig. 1). Both PC-coated and non-coated stents were equally dilated during implantation (stent diameter 2.42 ± 0.18 mm vs 2.37 ± 0.08 mm, an increase of 33.9% vs 31.3%, $p = \text{NS}$). At repeat angiography, there was no difference in stent diameter for both groups, 2.25 ± 0.20 mm vs 2.20 ± 0.18 mm, $p = \text{NS}$. Lumen area measured by videodensitometry was also the same in both groups (Table I).

Histomorphometric analysis showed there was some neointima formation, but intimal area was not significantly different between either group. There was a tendency for the arteries in the PC-coated stents to have a larger lumen (luminal area 4.27 ± 0.76 mm² vs 3.97 ± 0.61 mm², $p = 0.067$), while the vessel area was not statistically significant different (Table II, Fig. 2 a–d).

Pig study

In 9 pigs one stent from each group was deployed; in one minipig only the PC-coated stent was implanted (in the LCx), the non-coated stent could not be negotiated into the LAD. One pig died suddenly after 2 days, but the chest was opened within 15 min and the stented artery segments excised. Macroscopically, there was a thrombus in the non-coated stent implanted in the LCx.

Table I. Angiographic measurements for stented iliac arteries in rabbit

	Coated stents	Non-coated stents
Luminal in-stent diameter after stent implantation (mm)	2.42 ± 0.18	2.37 ± 0.08
% Increase of luminal diameter after stent implantation	33.9 ± 16.8	31.3 ± 16.2
Luminal in-stent diameter at follow-up (mm)	2.25 ± 0.20	2.20 ± 0.18
Luminal in-stent area (mm ²) at follow-up (videodensitometry)	4.12 ± 0.71	4.23 ± 0.64

\pm Standard deviation, $p = \text{NS}$

Table II. *Histomorphometric analysis of stented iliac arteries in rabbit*

	Coated stents	Non-coated stents	<i>p</i>
Intimal area (mm ²)	0.59 ± 0.16	0.58 ± 0.27	NS
Maximal intimal thickness (mm)	0.20 ± 0.05	0.23 ± 0.11	NS
Luminal area (mm ²)	4.27 ± 0.76	3.97 ± 0.61	0.067
Vessel area (mm ²)	5.45 ± 0.83	5.11 ± 0.65	NS

Reangiography after one month in the other cases showed that there were no occlusions in PC-coated or non-coated stents (Fig. 3). Predilatation angiography showed that the artery diameters for the PC-coated and non-coated stent groups were 2.81 ± 0.48 mm and 2.73 ± 0.43 mm respectively ($p = \text{NS}$). The stent dilatation was equal in the two groups, 3.30 ± 0.25 mm for the PC-coated stent and 3.15 ± 0.64 mm for the non-coated stent ($p = \text{NS}$) (Fig. 4). Balloon-to-artery ratios were 1.25 ± 0.16 and 1.20 ± 0.31 for the PC-coated and non-coated stent groups ($p = \text{NS}$). At repeat

angiography the minimal diameter for the PC-coated stent was 2.74 ± 0.65 mm and for the non-coated stent 2.55 ± 0.73 mm ($p = \text{NS}$). There was a significant difference within both stent groups in luminal diameter loss from postdilatation to follow-up ($p < 0.05$) (Fig. 4).

At histomorphometry there were no statistically significant differences between the coated and non-coated stent groups for intimal area, maximal intimal thickness, luminal area or vessel area. Nor were there any differences detected between LAD and LCx stent locations (Tables III and IV, Fig. 5a–d).

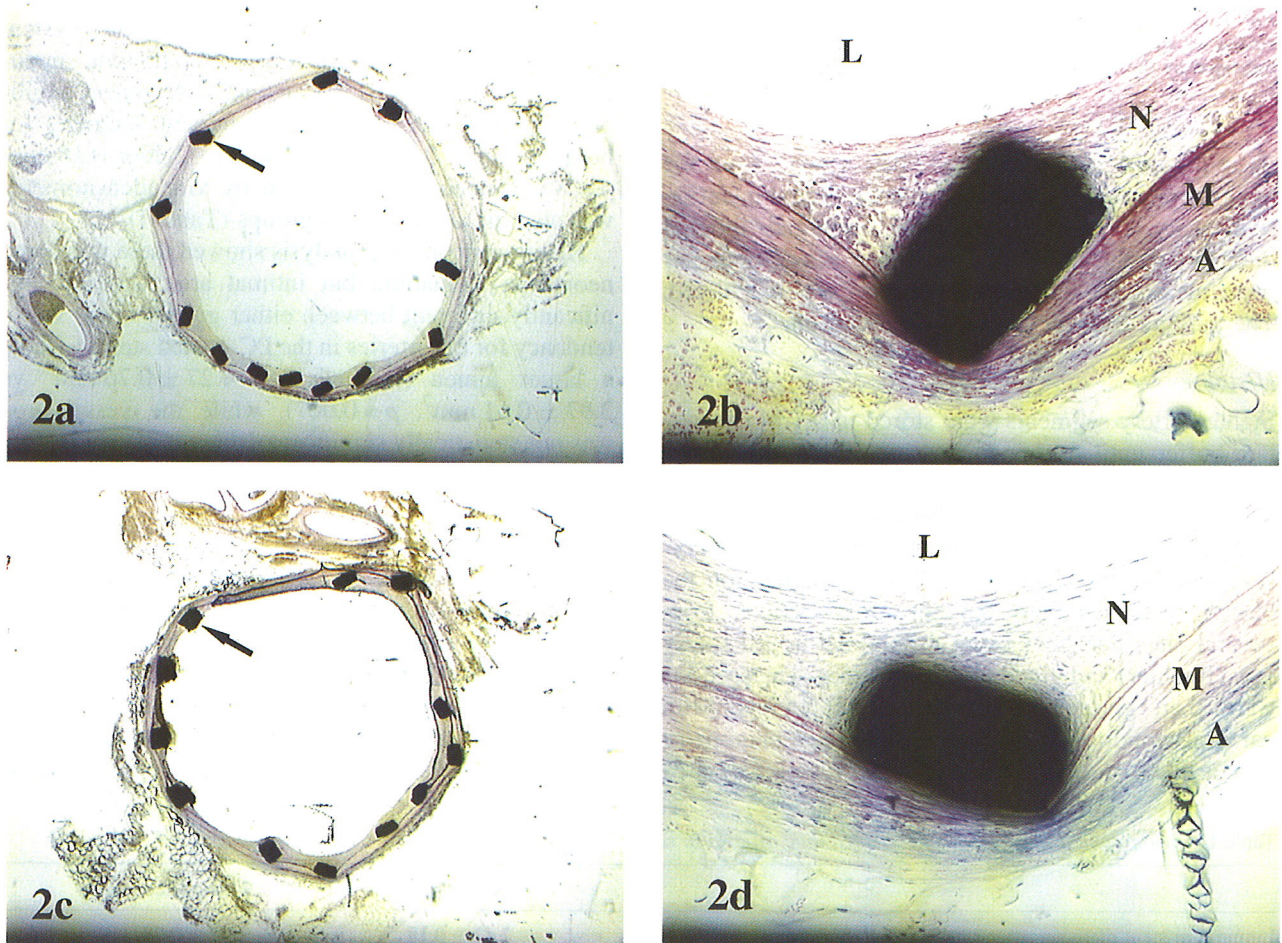


Fig. 2. Light microscopy of sections from stented rabbit iliac arteries. Control stents are in panels (a) and (b) (a stent strut is indicated by the arrow) while phosphorylcholine-coated stents are in (c) and (d). Note similar neointima size and morphology between arteries with control and coated stents. Instrument magnification in (a) and (b) was 20 \times , and 100 \times in (c) and (d). L = lumen, N = neointima, M = media, and A = adventitia.

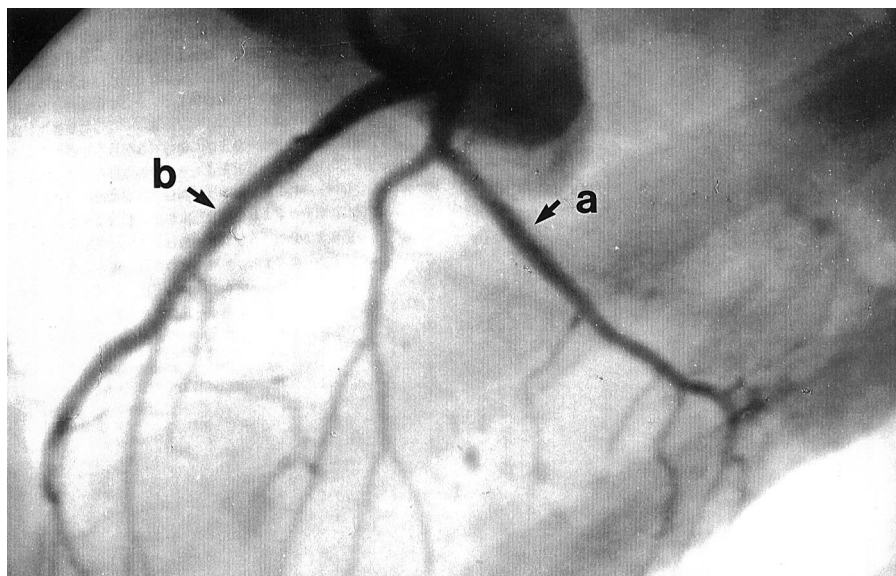


Fig. 3. Follow-up angiography of the left coronary porcine artery. Phosphorylcholine-coated stent (a) in circumflex artery and non-coated stent (b) in left anterior descending artery. A stent is indicated by the arrow.

No statistically significant difference in the injury score between the groups was found in either the rabbit study or the pig study. The degree of cellularity of the intima was qualitatively similar between the groups. Moderate inflammation was seen with both the PC-coated and the non-coated stents, mostly granulocytes in the adventitia, with the occasional foreign body giant cell in the neointima adjacent to the stent strut. However, there was no striking difference between the groups.

DISCUSSION

Stents and coatings may be regarded as foreign bodies in the blood vessels. Compared with stainless steel

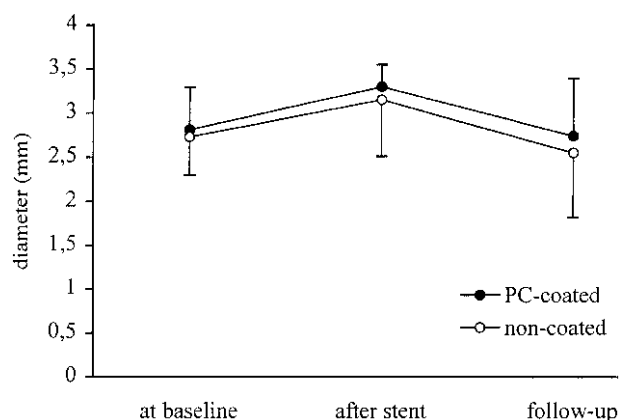


Fig. 4. Angiographical luminal diameter at baseline and stent diameter immediately after placement and at 4 weeks' follow-up of phosphorylcholine (PC)-coated and non-coated stent in coronary arteries of swine. $P < 0.05$ for stent diameter after stent placement to 4 weeks' follow-up (late loss) for both the PC-coated and non-coated stents. No significance between groups.

Table III. Histomorphometric analysis of stented pig coronary arteries

	Coated stents	Non-coated stents
Intimal area (mm ²)	1.51 ± 0.97	1.34 ± 0.55
Maximal intimal thickness (mm)	0.44 ± 0.27	0.47 ± 0.38
Luminal area (mm ²)	2.67 ± 1.03	2.42 ± 1.27
Vessel area (mm ²)	5.85 ± 1.20	5.09 ± 0.95

± Standard deviation, $p = \text{NS}$.

stents, the PC-coating did not provoke any additional intima reactions as confirmed by angiography and quantitative histology. This was observed both in the elastic iliac arteries and in the more muscular coronary arteries. It has been suggested that the intimal smooth muscle cell proliferation is more prolonged after stent implantation than after balloon injury alone (19). During the 4 weeks' follow-up we did not detect any differences between coated and non-coated stents. The follow-up time should be sufficient also to detect delayed reactions. Furthermore, the peak rate of intimal thickening did not seem to be delayed but occurred within approximately the same time after different stimuli (19).

Our aim was primarily to assess the vessel-wall

Table IV. Histomorphometric analysis of stented pig coronary arteries by stent location

	LAD	LCx
Intimal area (mm ²)	1.19 ± 0.27	1.67 ± 1.00
Maximal intimal thickness (mm)	0.33 ± 0.11	0.57 ± 0.39
Luminal area (mm ²)	3.00 ± 0.79	2.17 ± 1.26

± Standard deviation, $p = \text{NS}$.

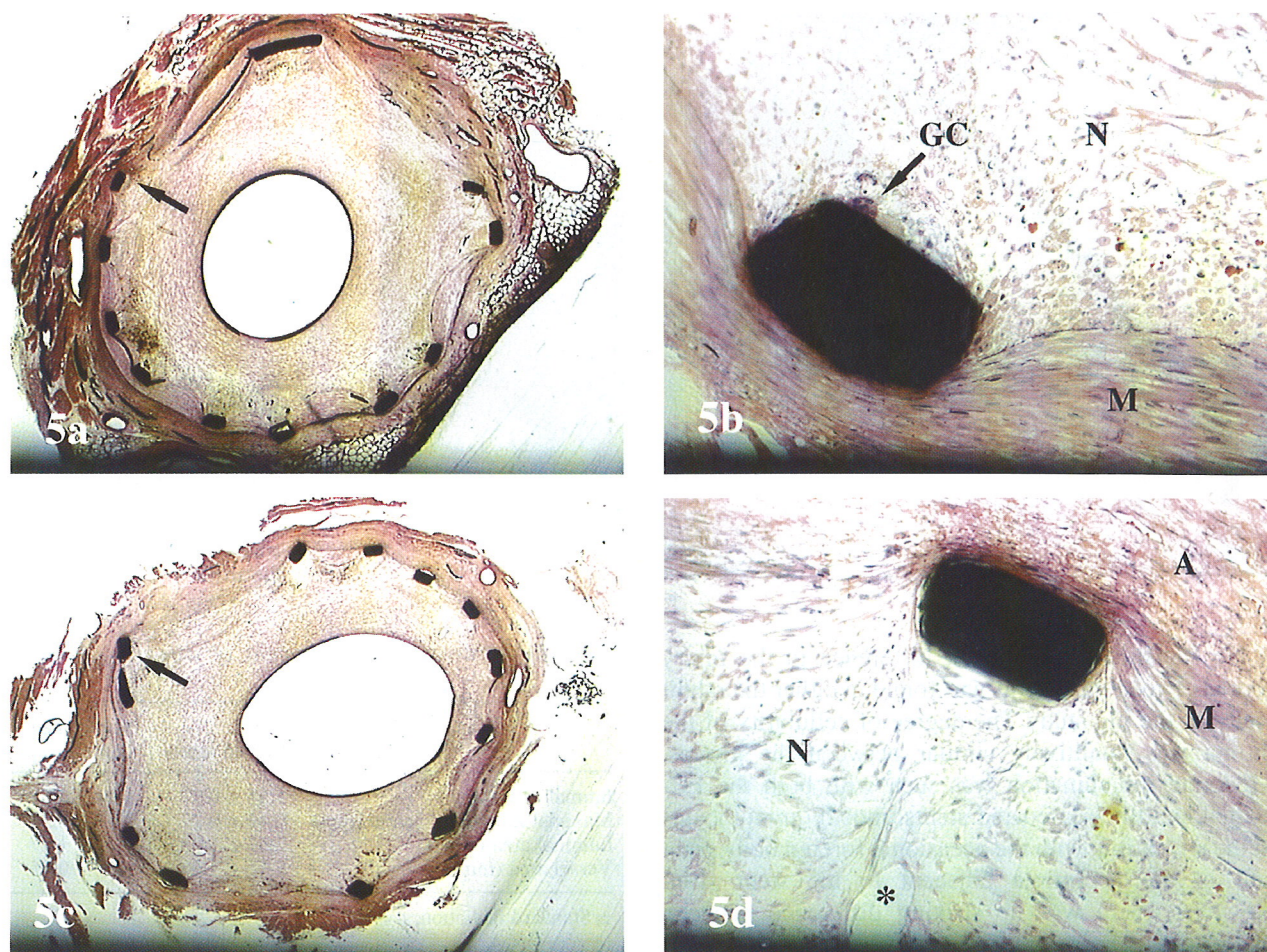


Fig. 5. Light microscopy of sections from stented pig coronary arteries. Control stents are in panels (a) and (b) (a stent strut is indicated by the arrow) while PC-coated stents are in panels (c) and (d). There is approximately equivalent neointima size in arteries with control and coated stents. A foreign body giant cell (GC) is seen attached to the stent in (b), while a neovascular channel (*) is seen in (d). Instrument magnification in (a) and (b) was 20 \times , and 100 \times in (c) and (d). L = lumen, N = neointima, M = media, and A = adventitia.

reaction to PC. Other biological coatings have provoked intense wall reactions (10, 13). In this respect, PC is a major improvement. When the vessel wall is extensively injured, subsequent stenosis is likely to develop (20); oversized metallic stenting has been used as a restenosis model. In both animal species in this study the stent/balloon to artery ratio was approximately 1.2:1. The intimal reaction in the rabbits was about three times greater than commonly seen after balloon injury alone (7). It is uncertain if this reflects a high degree of injury obtained in our study, or is only part of an increased intimal response generally seen after stent implantation (21). Our data did not support the hypothesis that PC counteracts the intimal response to balloon dilatation and stenting of coronary and peripheral arteries.

Only one acute stent thrombosis occurred in our study, whereas this has been much more frequent in

previous publications (7). We did not detect thrombi either in the angiographic follow-up or in the histological sections in either stent group. The balloon pressures used to expand the stents in both the rabbit iliac and swine coronary arteries were about the same as in a previous study (7). High-pressure stent expansion is known to reduce the occurrence of stent thrombosis considerably (3), probably by providing optimal stent expansion and thereby minimizing turbulent blood flow through the stent. Such high pressures may not be necessary to expand stents in a uniform way in the relatively thin-walled, normal animal arteries. Thus, proper stent expansion may explain the low occurrence of thrombotic events in both the coated and non-coated stent groups.

Although there are possible mechanisms for both a low thrombogenicity and a counteraction of restenosis for this stent coating, the latter seems more unlikely.

The PC head group is the predominating phospholipid in the outer part of the natural cell membrane, while negatively charged phospholipids such as phosphatidylserine are on the inner side of the membrane. By this asymmetry the cell becomes non-thrombogenic. Furthermore, PC-coating on foreign material reduces the level of interaction of proteins when present as a close-packed array on an interface rendering the surface hydrophilic (22). The natural phospholipids in cell membranes give rise to the platelet aggregation inhibitor and accelerator prostacyclin and thromboxane A₂ respectively via arachidonic acid and endoperoxides (23). Owing to the strong metal binding of the phosphorylcholine-coated stent, this is unlikely to undergo the same process and thereby interfere with the balance between prostacyclin and thromboxane A₂.

Platelet aggregation may be involved in the development of arterial stenosis after angioplasty balloon injury (24). By reducing clot formation, the PC-coating could reduce restenosis. However, many previous attempts to interfere with restenosis by inhibiting platelet aggregation have not been successful (24). Furthermore, PC has no known inhibitory effect on smooth muscle recruitment and migration, which is an important mechanism for restenosis development.

In conclusion, both PC-coated and non-coated stainless steel stents cause an increased but similar intimal hyperplasia. Angiographic loss of luminal diameter during follow-up was significant in both stent groups and was not reduced by PC. The in-stent luminal diameter at follow-up was the same for PC-coated and non-coated stents. PC-coating alone (without acting as drug carrier) does not seem to have the potential to reduce restenosis compared to stainless steel stents.

ACKNOWLEDGEMENT

This study was supported by a grant from the Bergen Heart Foundation, Bergen, Norway.

REFERENCES

1. Fischman DL, Leon MB, Baim DS, et al. for the Stent Restenosis Study Investigators. A randomized comparison of coronary artery stent-placement and balloon angioplasty in the treatment of coronary artery disease. *N Engl J Med* 1994; 331: 496–501.
2. Serruys PW, de Jaegere P, Kiemeneij F, et al. for the Benestent Study Group. A comparison of balloon-expandable stent implantation with balloon angioplasty in patients with coronary artery disease. *N Engl J Med* 1994; 331: 489–495.
3. Colombo A, Hall P, Nakamaru S, et al. Intracoronary stenting without anticoagulation accomplished with intravascular ultrasound guidance. *Circulation* 1995; 91: 1676–1688.
4. Goy JJ, Sigwart U, Vogt P, et al. Long-term follow-up of the first 56 patients treated with intracoronary self-expanding stents (the Lausanne experience). *Am J Cardiol* 1991; 67: 569–572.
5. de Jaegere P, Serruys PW, Bertrand M, et al. Wiktor stent implantation in patients with restenosis following balloon angioplasty of a native coronary artery. *Am J Cardiol* 1992; 69: 598–602.
6. Macander PJ, Agrawa SK, Roubin GS. The Gianturco-Roubin balloon-expandable intracoronary flexible coil stent. *J Invas Cardiol* 1991; 3: 85–94.
7. Rogers C, Edelman ER. Endovascular stent design dictates experimental restenosis and thrombosis. *Circulation* 1995; 91: 2995–3001.
8. Schömig A, Neumann FJ, Kastrati A, et al. A randomized comparison of antiplatelet and anticoagulant therapy after the placement of coronary-artery stents. *N Engl J Med* 1996; 334: 1084–1089.
9. Chronos NAF, Robinson KA, Kelly AB, et al. Thromboresistant phosphorylcholine coating for coronary stents. *Circulation* 1995; 92: I-490 (Abstract).
10. van der Giessen WJ, Lincoff AM, Schwartz RS, et al. Marked inflammatory sequelae to implantation of biodegradable and nonbiodegradable polymers in porcine coronary arteries. *Circulation* 1996; 94: 1690–1697.
11. Holmes Jr DR, Camrud AR, Jorgenson MA, Edwards WD, Schwartz RS. Polymeric stenting in the porcine coronary artery model: differential outcome of exogenous fibrin sleeves versus polyurethane-coated stents. *J Am Coll Cardiol* 1994; 24: 525–531.
12. Hårdhammer PA, van Beusekom HMM, Emanuelsson HU, et al. Reduction in thrombotic events with heparin-coated stents in normal porcine arteries. *Circulation* 1996; 93: 423–430.
13. Murphy JG, Schwartz RS, Edwards WD, Camrud AR, Vlietstra RE, Holmes Jr DR. Percutaneous polymeric stents in porcine coronary arteries: initial experience with polyethylene terephthalate stents. *Circulation* 1992; 86: 1596–1604.
14. de Scheerder IK, Wilczek KJ, Verbeke EV, et al. Biocompatibility of polymer-coated oversized metallic stents implanted in normal porcine coronary arteries. *Atherosclerosis* 1995; 114: 105–114.
15. Serruys PW, Emanuelsson H, van der Giessen WJ, et al. on behalf of the Benestent-II Study Group. Heparin-coated Palmaz-Schatz stents in human coronary arteries: early outcome of the Benestent-II pilot study. *Circulation* 1996; 93: 412–422.
16. le Bird R, Hall B, Chapman D, Hobbs KEF. Material thrombolastography: an assessment of phosphorylcholine compounds as models for biomaterials. *Thromb Res* 1988; 51: 471–483.
17. Hayward JA, Chapman D. Biomembrane surfaces as models for polymer design: the potential for haemocompatibility. *Biomaterials* 1984; 5: 135–142.
18. Scoblionko DP, Brown G, Mitten S, et al. A new digital electronic caliper for measurements of coronary arterial stenosis: comparison with visual estimates and computer-assisted measurements. *Am J Cardiol* 1984; 53: 689–693.
19. Kamenz J, Hanke H, Hassenstein S, et al. Time course of accumulation of macrophages and intimal cell proliferation following experimental stenting. *Circulation* 1993; 88: I-652 (Abstract).
20. Schwartz RS, Murphy JG, Edwards WD, Camrud AR,

- Vlietstra RE, Holmes DR. Restenosis after balloon angioplasty: a practical proliferative model in porcine coronary arteries. *Circulation* 1990; 82: 2190–2200.
21. de Jaegere PPT, de Feyter PJ, van der Giessen WJ, Serruys PW. Endovascular stents: preliminary clinical results and future developments. *Clin Cardiol* 1993; 16: 369–378.
 22. Yianni Yp. Biocompatible surfaces based upon biomembrane mimicry. In: Quinn PJ, Cherry RJ, eds. *Structural and dynamic properties of lipids and membranes*. Portland Press Research, 1992: 187–216.
 23. Godfried SL, Deckelbaum LI. Natural antioxidants and restenosis after percutaneous transluminal coronary angioplasty. *Am Heart J* 1995; 129: 203–210.
 24. Liu MW, Roubin GS, King III SB. Restenosis after coronary angioplasty: potential biologic determinants and role of intimal hyperplasia. *Circulation* 1989; 79: 1374–1387.