

Paper V

**Implementing a Best Treatment Strategy with Intracoronary
Brachytherapy for In-Stent Restenosis in Patients at High Risk for
Recurrence**

Karel K.J. Kuiper, MD, Mohamed Salem, MD, Svein Rotevatn, MD, PhD, Joseph Mills, MD,
Jan Erik Nordrehaug, MD, PhD

Department of Heart Disease
Haukeland University Hospital
N-5021 Bergen, Norway

Cardiovascular Revascularization Medicine: In Press

Corresponding author:

Karel K.J. Kuiper, MD

Department of Heart Disease
Haukeland University Hospital
N-5021 Bergen, Norway

Phone: +4755972220

Fax: +4755975150

E-mail: karel.kuiper@helse-bergen.no

Financial disclosure:

None of the authors has any financial disclosures.

Abstract:

BACKGROUND: The deployment of drug-eluting stents (DES) to treat bare-metal stent (in-stent) restenosis (ISR) has become routine practice with a consequential decline in the use of intracoronary brachytherapy (ICBT). However, there are concerns as to the long-term safety profile of DES particularly in terms of late stent thrombosis. In addition, an appropriate treatment strategy for stenosis within DES has not been developed. The aim of this study was to examine the efficacy of best treatment with ICBT for ISR in patients at high-risk for future recurrence. **METHODS:** Forty-seven consecutive patients with symptomatic ISR with at least one or more increased risk criterion for recurrence were treated with beta-radiation. The patients received best treatment based on avoidance of previously reported procedural risk factors for recurrence (incomplete stent apposition, dissection, geographical miss, damage to the non-injured vessel segment), deferring ICBT when provisional stenting was performed. A beta-radiation dose of 20 Gy was used and clopidogrel was prescribed for at least 6 months. **RESULTS:** Treatment was successful for all patients without in-hospital complications. Intracoronary brachytherapy increased the total intervention procedure-time by 15 ± 10 minutes. The ISR length was 25.4 ± 11.5 mm. The angiographic minimal luminal diameter after the ICBT was 2.24 ± 0.43 mm versus 0.75 ± 0.58 mm at baseline ($p<0.05$). At 9-month follow-up minimal luminal diameter was 1.93 ± 0.48 mm ($p<0.05$ versus baseline). Binary restenosis was detected in six patients (13%). During 29.7 ± 9.3 months follow-up, target lesion revascularisation or target vessel (non-lesion) revascularisation was performed in 17 patients (36%). Only one patient suffered a myocardial infarction and no deaths were observed. **CONCLUSION:** The adoption of a best-practice protocol for the use of ICBT to treat ISR can result in a safe and effective clinical and angiographic outcome. Under these circumstances and with appropriate patient selection, ICBT may continue to be of value despite the popular use of DES.

Key words:

Brachytherapy, in-stent restenosis, drug-eluting stent.

Short summary for annotated table of contents:

In this study patients with in-stent restenosis were treated by intracoronary brachytherapy implementing best treatment strategy based on avoidance of previously reported procedural risk factors for recurrence. Nine month after treatment recurrence of restenosis was comparable to results obtained after treatment of in-stent restenosis with drug-eluting stents. During long term follow-up stent thrombosis was not a major problem.

Introduction

The treatment of in-stent restenosis (ISR) after percutaneous coronary intervention (PCI) remains a difficult clinical issue and one which is at the centre of much debate (1;2). Several interventional therapies for the treatment of ISR such as balloon angioplasty, atheroablative techniques and repeated stenting (“stent-in-stent”) have proved to be ineffective over time with high rates of restenosis (3-5). However, analysis of the considerable data concerning the use of intracoronary brachytherapy (ICBT) has been more encouraging. Intracoronary brachytherapy appears to successfully reduce restenosis in patients with ISR from 50% in controls to 15-22% in randomized, placebo-controlled trials and, although anxieties exist regarding the possible long-term effects of radiation and the attrition of efficacy over time, ICBT has been the officially recommended treatment of choice for ISR in the USA and Europe (6-9). More recently, data supporting the use of drug-eluting stents (DES) for bare-metal stent ISR have been published. In the short to medium term, DES may be even more effective than ICBT, however, there are growing concerns surrounding the ubiquitous use of DES and the resultant reports of late stent thrombosis (ST). It would seem, therefore, that all proposed therapeutic strategies for ISR have their potential shortcomings and consequently it may be possible to improve and refine the brachytherapy procedure in order to define a future role for this interventional modality.

Procedural predictors of restenosis after brachytherapy have been identified in the previous multicenter studies (6-8;10). In the present study special attention was given to prevention or treatment based on previously identified procedural or postprocedural risk criteria. This was defined as a best treatment strategy, which was applied to a group of patients with symptomatic and angiographic in-stent restenosis who had a high risk of recurrence.

Methods

Patients: The study population consisted of 47 consecutive patients with previous intracoronary stent implantation in native coronary arteries or in aortocoronary venous bypass grafts. Inclusion criteria required patients presented with symptoms of angina (CCS class IIA-IV), a positive exercise ECG (>1 mm ST-depression), and angiographic evidence of ISR. All patients had at least one increased risk criterion for ISR: vein graft lesion, ostial lesion, at least one previous treatment for ISR in the same location, lesion length >20 mm, reference vessel diameter <3.0mm, total occlusion or diabetes mellitus. Angiographic entry criteria included diameter stenosis $\geq 50\%$ within the stent treatment site in vessels that were ≥ 2.5 to 5.0 mm in diameter. Main exclusion criteria were bifurcation lesions, unprotected left main lesion, unsuccessful PCI, acute myocardial infarction within five days, severe heart failure (EF<20%), refractory ventricular arrhythmias, and cardiogenic shock. Best treatment was defined according to the following criteria: beta-radiation dose of 20 Gy, absence of incomplete stent apposition confirmed by intravascular ultrasound (IVUS), no dissection, avoidance of geographical miss, avoidance of damage to the non-injured vessel segment, and deferring brachytherapy for one month when provisional stenting was performed. In the presence of severe symptoms balloon angioplasty was performed to stabilize the patients and brachytherapy deferred by up to one month.

Brachytherapy equipment: The Galileo™ Intravascular Radiotherapy System (Guidant Corp.) was used to deliver the radioactive treatment. The radiation source, the beta-radiation emitting isotope ^{32}P , is sealed in the distal 20 mm of a source wire and has a 14 days half time. The radiotherapy source wire is lead automatically into a centering catheter, which permitted some perfusion when inflated. Radiation therapy was given with a fixed dose of 20

Gy, while radiation time is computed automatically, dependent on reference lumen diameter (RLD) as measured by QCA and IVUS.

Procedure: Dilation with non-compliant balloons was performed at high pressures to optimize stent apposition. Before radiotherapy, the angioplasty result was evaluated by QCA and IVUS, also to exclude incomplete stent apposition and dissections outside the stent. If provisional stent implantation was necessary, ICBT was postponed for one month. The centering catheter was slightly undersized (diameter dependent on minimal luminal diameter (MLD)) and inflated at 4.0 atmospheres to avoid damage to the non-injured part of the vessel. To ensure adequate coverage of the lesion and to avoid geographical miss, a centering catheter (available in the length of 32 mm and 52 mm) was used with at least 5 to 10 mm margin proximal and distal to the regions of balloon dilation.

Stenosis quantitation: Angiography was performed in orthogonal views. Reference luminal diameter, defined as the mean of the vessel diameter proximally and distally from the lesion, and MLD were measured using the contrast-filled tip of the guiding catheter as calibration. Intravascular ultrasound was performed with the Endosonics system, and quantitation performed by a technician blinded to the clinical data. Angiographic analysis after the procedure and at follow up was performed using the CAAS II analysis system (Pie Medical BV, Maastricht, Netherlands).

Medication: All patients were on treatment with acetylsalicylic acid and clopidogrel for at least 24 hours before treatment. After insertion of the 8F arterial sheath 7.500 IE heparin was administered intraarterially, an additional dose of 2.500 IE of heparin was given if activated clotting time (ACT) was < 300 seconds. After discharge the combination of acetylsalicylic acid and clopidogrel was used for at least six months.

Follow-up: Creatine kinase-MB (CK-MB), Troponin I (Tp-I) and ECG were obtained at baseline and 24 hours post procedure to assess procedural and in-hospital complications. The

patients were examined one month and 9 months after discharge, angiographic follow-up was performed at nine months. Late follow-up was obtained at 29.7 ± 9.3 months.

Study end-points: The study end-points were both clinical and angiographic. Major adverse cardiac events (MACE) in-hospital and during follow-up were defined as death, acute ST-elevation and/or Q-wave myocardial infarction and target vessel revascularisation. Angiographic restenosis was defined by quantitative computer analysis, regardless of symptoms. Binary restenosis was defined as diameter stenosis $>50\%$ at follow-up.

Statistical analysis: Results are presented as mean \pm SD for continuous variables and as n (%) for categorical data. Paired-samples T-Test was used for comparison of angiographic parameters at baseline, post ICBT, and at follow-up. Binary logistic regression was performed to study independent risk factors for restenosis and major adverse coronary events. Survival analysis was performed using Kaplan-Meier method. The data were analyzed by using the SPSS program for Windows 11.0.

Results

Patient characteristics: Patient characteristics and previous medical history are shown in table 1. Thirty-three patients (70%) had been treated with balloon angioplasty or stent-in-stent for ISR at least once. In one patient ISR in LAD and LCx was treated during the same procedure. In six patients (13%) the ISR involved the ostium of the RCA, in two (4%) the ostium of a saphenous vein graft and of the LCx in one (2%). In-stent total occlusion was observed in eight patients (17%).

The procedure: The procedure was successful in all patients. Intracoronary brachytherapy was administered for 180 ± 70 seconds. Brachytherapy alone increased the total intervention procedure-time by a mean of 15 ± 10 minutes. Total stent length was 22.7 ± 10.9 mm (8-64mm). The in-stent restenosis length was 25.4 ± 11.5 mm, the centering balloon length was 38.8 ± 9.6

mm. Final balloon diameter for dilation of the ISR was 3.5 ± 0.5 mm versus 3.1 ± 0.4 mm when the stents were implanted ($p<0.05$). The angiographic MLD after the procedure was 2.24 ± 0.43 mm versus 0.75 ± 0.58 mm at baseline ($p<0.05$). Dissections at the margins of the stents were not detected. The mean diameter stenosis post ICBT was 24.9% versus 74.8% at baseline ($p<0.05$). All patients were discharged one day after ICBT.

In-hospital complications: Elevation of Tp-I after 24 hours was observed in 7 patients (15%), the rise of the cardiac markers was less than 3 times the upper normal limit. The mean values of CK-MB and Tp-I remained within the reference limits after 24 hours (table 2). Repetitive ECG's did not reveal new ST-elevation infarction in any patient. There was no death, new myocardial infarction or subacute stent thrombosis. No other complications occurred.

Follow-up: Follow-up angiography after 9 months has been performed in 43 patients (92%) (table 4). Restenosis at the edges of the radiation field ("edge stenosis") was detected in three patients, recurrence of in-stent restenosis in two patients, in one patient both edge-stenosis and new stenosis in another vessel was seen.

After a mean follow-up of 29.7 ± 9.3 months, thirteen patients were treated with PCI and four patients were revascularised with CABG because of simultaneously occurring lesion-progression in a non-ICBT treated artery. One patient suffered from myocardial infarction, but death did not occur (table 3). There was no difference in the duration of clopidogrel treatment longer than 6 months for patients with and without TVR. No independent risk factors for either MACE or restenosis could be identified using logistic regression analysis. The Kaplan-Meier curve for MACE is shown in figure 1.

Discussion

We have shown that intracoronary brachytherapy using a best treatment approach based on previous research, including the use of the high 20 Gy dose, is an effective treatment

of symptomatic and angiographic in-stent restenosis (10). There were no serious complications in hospital or during follow-up. There was no significant rise of cardiac biomarkers. Analysis of biomarkers is often used to compare myocardial infarctions rates in randomised studies, but is also useful to assess complication rate in an observational study of best treatment strategy. Despite the fact that 70% of the patients were treated for ISR at least once before ICBT, and all had risk factors for recurrence, ISR occurred in only 13% of patients at angiography after 9 months. The use of strict selection criteria, and thereby including only patients who appeared to be most at risk of a recurrence of ISR if treated in a conventional manner, was important in order to identify maximum efficacy in these subgroups with challenging clinical presentations.

Several cautions were taken in our study to ensure success of the therapy. The importance of detecting and treating incomplete stent apposition, avoidance of damage to the non-affected adjacent vessel segment and the importance of geographical miss have been discussed by other groups (11). Furthermore, since prophylactic use of ICBT after implantation of new stents is discouraged, angioplasty prior to ICBT was performed cautiously in order to minimise the risk of any dissection outside the stents, necessitating the implantation of supplementary stents (7). In two patients new stents were implanted because of stenosis outside the stent. In these cases ICBT was postponed for at least 4 weeks to permit endothelialisation of the stent. There is evidence that prophylactic radiation of bare stents may provoke increased rates of ST (7). Patients with severe clinical symptoms underwent predilatation up to one month before brachytherapy in order to allow adequate planning and completion of their final therapeutic procedure under stable conditions. None of the patients having two separate procedures experienced cardiac events during the intervening time period.

There seems to be no difference in reductions of restenosis between beta- and gamma radiation (12). In the present study a radiation dose of 20 Gy was used, this is probably a near optimal dose. Radiation dose of 18 Gy is more favourable than a dose of 12 Gy and there is an indication that 21 Gy is better than 18 Gy (13;14).

Two, significant, prospective, randomised studies comparing either Sirolimus eluting stents against ICBT or Paclitaxel eluting stents against ICBT have been recently published (15;16). In both studies, DES appears to be the superior treatment option with lower rates of MACE and target lesion restenosis at 9 months follow-up. The debate, therefore, would seem to have shifted to which DES for ISR with ICBT consequently relegated to a last-resort option or even obscurity. However, it may be too soon to completely dismiss the clinical application of ICBT. The numbers of patients in the two head to head studies are relatively small compared to the data amassed for ICBT over some years, and the short follow-up period of 9 months may have resulted in false reassurance of the safety of DES in this setting. Genuine concerns regarding DES thrombosis, particularly late ST (often after the discontinuation of one or more antiplatelet agents and often beyond 9 months from implantation), are growing (17-19). In addition, as yet unpublished data from the BASKET trial investigators – BASKET-LATE, identified DES implantation as an independent predictor of late cardiac death/non-fatal MI, a clinical endpoint which appeared to be primarily related to late ST. In the present study the adoption of a best practice protocol under optimum conditions has resulted in a target lesion restenosis rate comparable to that of the DES trials, and although there is some attenuation of ICBT efficacy out at 2.5 years follow-up, there does not seem to be a “price to pay” in the form of late thrombosis. The absence of ST reported here, in contrast to other reported studies involving ICBT, may have been a consequence of the strict protocol used and/or the vigilant 6 month period of dual antiplatelet therapy (8;20). The optimal duration of clopidogrel in general can probably not be concluded from the

randomised studies. Interventionalists have already more or less intuitively adopted the practice of prescribing for extended periods. Of course the small number of study subjects renders the interpretation of these findings to be somewhat speculative; nevertheless, a mean follow-up period of almost 30 months does provide a degree of reassurance, a fact which cannot be said for DES under these clinical conditions.

The use of DES in the treatment of de-novo coronary lesions have dramatically reduced the overall rates of ISR (21;22). However, DES restenosis does exist and provides a significant clinical challenge. The medium to long-term effects of ICBT in such patients is unknown, with particular concern surrounding the potential lack of endothelialisation when two such potent anti-proliferative agents are used. However, preliminary data from registries suggest that brachytherapy reduces in-stent restenosis recurrence when drug-eluting stents are used, without any apparent increase of stent thrombosis (23). Of course, additional more robust data are required before ICBT can be advocated as the treatment of choice in this setting. In the interim, it may well be a choice of a different drug-eluting agent to treat DES ISR which is the preferred option.

Recently published data from prophylactic brachytherapy to prevent a first restenosis after de novo stent implantation demonstrated an adverse clinical outcome for patients receiving beta-radiation therapy (10;24). As a result, a prophylactic approach cannot be recommended. Furthermore, the large-scale use of radiation in the treatment of a relatively benign disorder such as ISR may heighten concerns about possible long-term effects and the development of late atherosclerosis in these patients. Three year follow-up after ICBT shows that the reduction of restenosis is largely maintained, although studies extending out to five years show diminished effect and in one using a γ -radiation source, no effect (25-28). The development of late atherosclerosis after radiation exposure may even accelerate over a period of 5-20 years (29). Taking all these factors in to consideration, along with the promising early

results for DES treatment of ISR, it would be inappropriate to suggest that ICBT should remain a first-line therapy for all patients with bare-metal stent ISR. Careful selection of patients will become paramount in order to maximize the benefits and minimize the deleterious clinical outcomes for both treatment modalities.

The main goal of the present study was to establish whether or not an acceptable primary result could be obtained with ICBT using the available best practice techniques under optimum conditions. Early and late follow-up was then completed in order to assess the clinical efficacy of this treatment strategy and to identify significant complications. Low rates of both restenosis and adverse clinical events were observed and although late recurrence resulted in increased target lesion revascularization, myocardial infarction occurred in only one study patient. Despite European and FDA guidelines, the use of DES for the treatment of ISR has become widely accepted, with procedural and logistic complexities undermining the clinical application of ICBT. Furthermore, recent randomized data has only served to strengthen the perceived superiority of DES over ICBT. Nevertheless, these latter studies were comparatively small, with a short follow-up period and long lists of exclusion criteria rendering their applicability to real-world Cardiology somewhat uncertain. The results of the present study demonstrate that, in a group of patients at high risk of further restenosis, ICBT can be performed in a safe and effective manner. Intracoronary brachytherapy is, therefore, a treatment strategy for ISR which is worthy of consideration under specific clinical circumstances.

Reference List

1. Fischman DL, Leon MB, Baim DS, Schatz RA, Savage MP, Penn I, Detre K, Veltri L, Ricci D, Nobuyoshi M. Stent Restenosis Study Investigators. A randomized comparison of coronary-stent placement and balloon angioplasty in the treatment of coronary artery disease. *N Engl J Med* 1994;331:496-501.
2. Serruys PW, de Jaegere P, Kiemeneij F, Macaya C, Rutsch W, Heyndrickx G, Emanuelsson H, Marco J, Legrand V, Materne P. Benestent Study Group. A comparison of balloon-expandable-stent implantation with balloon angioplasty in patients with coronary artery disease. *N Engl J Med* 1994;331:489-495.
3. vom Dahl J, Dietz U, Haager PK, Silber S, Niccoli L, Buettner HJ, Schiele F, Thomas M, Commeau P, Ramsdale DR, Garcia E, Hamm CW, Hoffmann R, Reineke T, Klues HG. Rotational atherectomy does not reduce recurrent in-stent restenosis: results of the angioplasty versus rotational atherectomy for treatment of diffuse in-stent restenosis trial (ARTIST). *Circulation* 2002;105:583-588.
4. Alfonso F, Zueco J, Cequier A, Mantilla R, Bethencourt A, Lopez-Minguez JR, Angel J, Auge JM, Gomez-Recio M, Moris C. A randomized comparison of repeat stenting with balloon angioplasty in patients with in-stent restenosis. *J Am Coll of Cardiol* 2003;42:796-805.
5. Albiero R, Nishida T, Karvouni E, Corvaja N, Vaghetti M, Di Mario C, Colombo A. Cutting balloon angioplasty for the treatment of in-stent restenosis. *Catheter Cardiovasc Interv* 2000;50: 452-459.

6. Waksman R, Raizner AE, Yeung AC, Lansky AJ, Vandertie L. Use of localised intracoronary beta-radiation in treatment of in-stent restenosis: the INHIBIT randomised controlled trial. *Lancet* 2002;359:551-557.
7. Leon MB, Teirstein PS, Moses JW, Tripuraneni P, Lansky AJ, Jani S, Wong SC, Fish D, Ellis S, Holmes DR, Kerieakes D, Kuntz RE. Localized intracoronary gamma-radiation therapy to inhibit the recurrence of restenosis after stenting. *N Engl J Med* 2001;344:250-256.
8. Teirstein PS, Massullo V, Jani S, Popma JJ, Mintz GS, Russo RJ, Schatz RA, Guarneri EM, Steuterman S, Morris NB, Leon MB, Tripuraneni P. Catheter-based radiotherapy to inhibit restenosis after coronary stenting. *N Engl J Med* 1997;336:1697-1703.
9. Raizner AE, Oesterle SN, Waksman R, Serruys PW, Colombo A, Lim YL, Yeung AC, van der Giessen WJ, Vandertie L, Chiu JK, White LR, Fitzgerald PJ, Kaluza GL, Ali NM. Inhibition of restenosis with beta-emitting radiotherapy: Report of the proliferation reduction with vascular energy trial (PREVENT). *Circulation* 2000;102:951-958.
10. Verin V, Popowski Y, de Bruyne B, Baumgart D, Sauerwein W, Lins M, Kovacs G, Thomas M, Calman F, Disco C, Serruys PW, Wijns W, Piessens M, Kurtz J, Simon R, Delafontaine P, Erbel R. The Dose-Finding Study Group: Endoluminal beta-radiation therapy for the prevention of coronary restenosis after balloon angioplasty. *N Engl J Med* 2001;344:243-249.
11. Sianos G, Kay IP, Costa MA, Regar E, Kozuma K, De Feyter PJ, Boersma E, Disco C, Serruys PW. Geographical miss during catheter-based intracoronary beta-radiation: incidence and implications in the BRIE study. *J Am Coll Cardiol* 2001;38:415-420.

12. Shirai K, Lansky AJ, Mintz GS, Costantini CO, Fahy M, Mehran R, Dangas G, Moses JW, Stone GW, Waksman R, Leon MB. Comparison of the angiographic outcomes after beta versus gamma vascular brachytherapy for treatment of in-stent restenosis. *Am J Cardiol* 2003;92:1409-1413.
13. Schukro C, Syeda B, Schmid R, Stemberger A, Lang I, Derntl M, Neunteufl T, Christ G, Kirisits C, Pokrajac B, Glogar D. Intracoronary brachytherapy with beta-radiation for the treatment of long diffuse in-stent restenosis. *Coron Artery Dis* 2004;15:285-289.
14. Kuchulakanti P, Torguson R, Canos D, Satler LF, Suddath W, Chan R, White LR, Gevorkian N, Bui A, Wang B, Kent KM, Pichard AD, Waksman R. Optimizing dosimetry with high-dose intracoronary gamma radiation (21 Gy) for patients with diffuse in-stent restenosis. *Cardiovasc Revasc Med* 2005;6:108-112.
15. Holmes DR, Jr., Teirstein P, Satler L, Sketch M, O'Malley J, Popma JJ, Kuntz RE, Fitzgerald PJ, Wang H, Caramanica E, Cohen SA, for the SISR Investigators. Sirolimus-eluting stents vs vascular brachytherapy for in-stent restenosis within bare-metal stents: The SISR randomized trial. *JAMA* 2006;295:1264-1273.
16. Stone GW, Ellis SG, O'Shaughnessy CD, Martin SL, Satler L, McGarry T, Turco MA, Kereiakes DJ, Kelley L, Popma JJ, Russell ME, for the TAXUS. Paclitaxel-eluting stents vs vascular brachytherapy for in-stent restenosis within bare-metal stents: The TAXUS V ISR randomized trial. *JAMA* 2006;295:1253-1263.
17. Waters RE, Kandzari DE, Phillips HR, Crawford LE, Sketch MH, Jr. Late thrombosis following treatment of in-stent restenosis with drug-eluting stents after discontinuation of antiplatelet therapy. *Catheter Cardiovasc Interv* 2005;65:520-524.

18. Lee CH, Lim J, Low A, Tan HC, Lim YT. Late angiographic stent thrombosis of polymer based paclitaxel eluting stent. *Heart* 2006;92:551-553.
19. Nasser M, Kapeliovich M, Markiewicz W. Late thrombosis of sirolimus-eluting stents following noncardiac surgery. *Catheter Cardiovasc Interv* 2005;65:516-519.
20. Waksman R, Ajani AE, White RL, Pinnow E, Dieble R, Bui AB, Taaffe M, Gruberg L, Mintz GS, Satler LF, Pichard AD, Kent KK, Lindsay J. Prolonged antiplatelet therapy to prevent late thrombosis after intracoronary gamma-radiation in patients with in-stent restenosis: Washington radiation for in-stent restenosis trial plus 6 months of clopidogrel (WRIST PLUS). *Circulation* 2001;103:2332-2335.
21. Moses JW, Leon MB, Popma JJ, Fitzgerald PJ, Holmes DR, O'Shaughnessy C, Caputo RP, Kereiakes DJ, Williams DO, Teirstein PS, Jaeger JL, Kuntz RE. Sirolimus-eluting stents versus standard stents in patients with stenosis in a native coronary artery. *N Engl J Med* 2003;349:1315-1323.
22. Stone GW, Ellis SG, Cox DA, Hermiller J, O'Shaughnessy C, Mann JT, Turco M, Caputo R, Bergin P, Greenberg J, Popma JJ, Russell ME, for the TAXUS-IV Investigators: One-year clinical results with the slow-release, polymer-based, paclitaxel-eluting TAXUS stent: The TAXUS-IV trial. *Circulation* 2004;109:1942-1947.
23. Park DW, Park SW, Park KH, Lee BK, Kim YH, Lee CW, Hong MK, Kim JJ, Park SJ. Frequency of and risk factors for stent thrombosis after drug-eluting stent implantation during long-term follow-up. *Am J Cardiol* 2006;98:352-356.
24. Serruys PW, Wijns W, Sianos G, de Scheerder I, van den Heuvel PA, Rutsch W, Glogar HD, Macaya C, Materne PH, Veldhof S. Direct stenting versus direct stenting followed by centered beta-radiation with intravascular ultrasound-guided dosimetry and long-term

- anti-platelet treatment: Results of a randomized trial: Beta-radiation investigation with direct stenting and galileo in Europe (BRIDGE). *J Am Coll Cardiol* 2004;44:528-537.
25. Teirstein PS, Massullo V, Jani S, Popma JJ, Russo RJ, Schatz RA, Guarneri EM, Steuterman S, Sirkin K, Cloutier DA, Leon MB, Tripuraneni P. Three-year clinical and angiographic follow-up after intracoronary radiation: results of a randomized clinical trial. *Circulation* 2000;101:360-365.
26. Ajani AE, Waksman R, Sharma AK, Cha DH, Cheneau E, White RL, Canos D, Pichard AD, Satler LF, Kent KM. Three-year follow-up after intracoronary gamma radiation therapy for in-stent restenosis: Original WRIST. *Cardiovasc Rad Med* 2001;2:200-204.
27. Grise MA, Massullo V, Jani S, Popma JJ, Russo RJ, Schatz RA, Guarneri EM, Steuterman S, Cloutier DA, Leon MB, Tripuraneni P, Teirstein PS. Five-year clinical follow-up after intracoronary radiation: results of a randomized clinical trial. *Circulation* 2002;105:2737-2740.
28. Waksman R, Ajani AE, White RL, Chan R, Bass B, Pichard AD, Satler LF, Kent KM, Torguson R, Deible R, Pinnow E, Lindsay J. Five-year follow-up after intracoronary gamma radiation therapy for in-stent restenosis. *Circulation* 2004;109:340-344.
29. Corn BW, Trock BJ, Goodman RL. Irradiation-related ischemic heart disease. *J Clin Oncol* 1990;8:741-750.

Figure 1

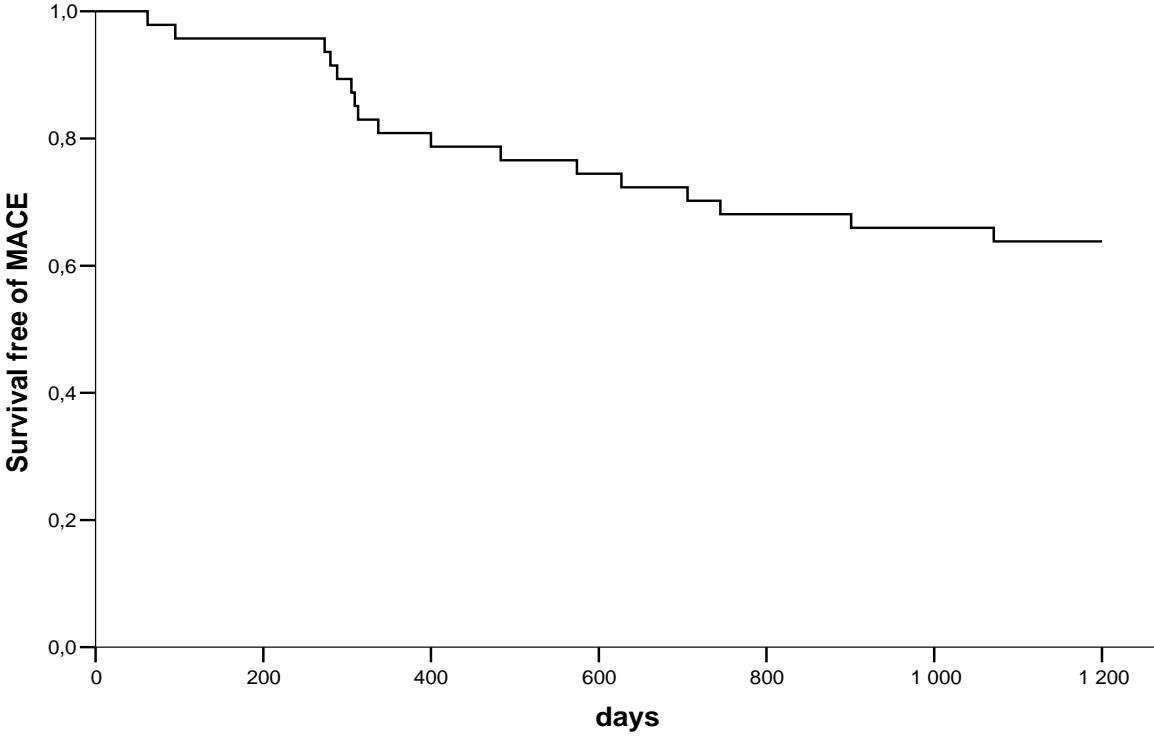


Figure legend

Figure 1. Kaplan-Meier curve for major adverse cardiac endpoints (death, acute myocardial infarction, target vessel revascularisation) after treatment with intracoronary brachytherapy for in-stent restenosis.

MACE: major adverse cardiac endpoints.

Table 1 Baseline Characteristics (N=47)

Female/male	10 / 37
Age (yrs)	61.6±10.8
Diabetes mellitus	7 (15%)
Hypertension	19 (40%)
Family history of CAD ¹	33 (70%)
Smoking - current	7 (15%)
- previous	22 (47%)
Previous CABG ²	14 (30%)
Prior intervention:	
>1 PCI ³ before ISR ⁴	33 (70%)
Stent Length (mm)	22.7±10.9 (8-64)
No. of Stents	1.7±0.8 (1-4)
Stent Diameter (mm)	3.1±0.4 (2.5-4.0)
Vessels with ISR	LAD 8 (17%)
	LCx 7 (15%)
	RCA 22 (47%)
	LM 2 (4%)
	SVG 7 (15%)
	LAD and LCx 1 (2%)

¹CAD: coronary artery disease. ²CABG: coronary artery bypass grafting. ³PCI: percutaneous coronary intervention. ⁴ISR: in-stent restenosis.

Table 2. Cardiac Biomarkers

	Pre-procedure (N=47)	24h post- procedure (N=47)
Ck ¹ (U/L)	88.2±41.6	87.3±52.7
Ck-MB ² (U/L)	0.9±1.3	2.4±4.9
Troponin I (U/L)	0.0±0.0	0.2±0.6

p=NS. ¹Ck: Creatine kinase. ²Ck-MB: Isoenzyme of Creatine kinase.

Table 3. Major adverse cardiac end-points during follow-up.

	N=47 (%)	N=47 (%)
	9 months	29.7±9.3 months
Death	0	0
Acute myocardial infarction	0	1 (2)
PCI ¹ -TLR ²	3 (6)	9 (19)
PCI-TVR ³ , non-TLR	3 (6)	4 (8)
CABG ⁴	1 (2)	4 (8)
Total MACE ⁵	7 (15)	18 (38)

¹PCI: percutaneous coronary intervention. ²TLR: target lesion revascularisation. ³TVR: target vessel revascularisation. ⁴CABG: coronary artery bypass grafting. ⁵MACE: major adverse cardiac end-points.

Table 4. Quantitative Coronary Angiography

	Baseline (N= 47)	After procedure (N= 47)	9-month follow-up (N= 43)
MLD ¹ (mm)	0.75±0.58	2.24±0.43*	1.93±0.48*
RLD ² (mm)	2.96±0.62	3.11±0.52	3.08±0.53 [†]
Acute gain (mm)		1.50±0.53	
Late loss (mm)			0.30±0.49
Stenosis diameter (%)	74.8	24.9*	37.3*
Restenosis, n (%)			6 (13%)

*p<0.05 versus baseline. [†]p=NS versus baseline and versus “after procedure”. ¹MLD:

Minimal luminal diameter. ²RLD: Reference luminal diameter

