



CONCISE REVIEW

Simple limbal epithelial transplantation: Current status and future perspectives

Catherine J. Jackson^{1,2,3} | Inger T. Myklebust Ernø² | Håkon Ringstad⁴ |
Kim A. Tønseth^{1,4} | Darlene A. Dartt⁵ | Tor P. Utheim^{1,2,3,6,7,8,9,10}

¹Department of Plastic and Reconstructive Surgery and Institute for Surgical Research, Oslo University Hospital, Oslo, Norway

²Institute of Oral Biology, Faculty of Dentistry, University of Oslo, Oslo, Norway

³Department of Medical Biochemistry, Oslo University Hospital, Oslo, Norway

⁴Institute of Clinical Medicine, Faculty of Medicine, University of Oslo, Norway

⁵Schepens Eye Research Institute, Massachusetts Eye and Ear Infirmary, Department of Ophthalmology, Harvard Medical School, Boston, Massachusetts

⁶Department of Ophthalmology, Oslo University Hospital, Oslo, Norway

⁷Department of Ophthalmology, Vestre Viken Hospital Trust, Drammen, Norway

⁸Department of Ophthalmology, Stavanger University Hospital, Stavanger, Norway

⁹Department of Clinical Medicine, Faculty of Medicine, University of Bergen, Bergen, Norway

¹⁰Department of Ophthalmology, Sørlandet Hospital, Arendal, Norway

Correspondence

Catherine J. Jackson, PhD, Department of Plastic and Reconstructive Surgery, Post Box 4956, Nydalen, 0424 Oslo, Norway.
Email: catherinejoan.jackson@gmail.com

Abstract

Damage to limbal stem cells as a result of injury or disease can lead to limbal stem cell deficiency (LSCD). This disease is characterized by decreased vision that is often painful and may progress to blindness. Clinical features include inflammation, neovascularization, and persistent cornea epithelial defects. Successful strategies for treatment involve transplantation of grafts harvested from the limbus of the alternate healthy eye, called conjunctival-limbal autograft (CLAU) and transplantation of limbal cell sheets cultured from limbal biopsies, termed cultured limbal epithelial transplantation (CLET). In 2012, Sangwan and colleagues presented simple limbal epithelial transplantation (SLET), a novel transplantation technique that combines the benefits of CLAU and CLET and avoids the challenges associated with both. In SLET a small biopsy from the limbus of the healthy eye is divided and distributed over human amniotic membrane, which is placed on the affected cornea. Outgrowth occurs from each small explant and a complete corneal epithelium is typically formed within 2 weeks. Advantages of SLET include reduced risk of iatrogenic LSCD occurring in the healthy cornea at harvest; direct transfer circumventing the need for cell culture; and the opportunity to perform biopsy harvest and transplantation in one operation. Success so far using SLET is comparable with CLAU and CLET. Of note, 336 of 404 (83%) operations using SLET resulted in restoration of the corneal epithelium, whereas visual acuity improved in 258 of the 373 (69%) reported cases. This review summarizes the results of 31 studies published on SLET since 2012. Progress, advantages, challenges, and suggestions for future studies are presented.

KEYWORDS

cornea, limbus, limbal stem cell deficiency, simple limbal epithelial transplantation, stem cells

Abbreviations: allosLET, allogenic SLET; AM, amniotic membrane; AMT, amniotic membrane transfer; CLAU, corneal limbal autograft; CLET, cultured limbal epithelial transplantation; COMET, cultured oral mucosal epithelial transplantation; Ir-CLAL, living-related conjunctival limbal allograft; KLAL, keratolimbal allograft; LSCD, limbal stem cell deficiency; MMP, mucous membrane plemigoid; OSSN, ocular surface squamous neoplasia; PK, penetrating keratoplasty; SLET, simple limbal epithelial transplantation; SOMET, simple oral mucosal epithelial transplantation; VEGF, vascular endothelial growth factor; Δ Np63 α , delta p63 transcription factor alpha isoform positive.

1 | INTRODUCTION

The corneal epithelium is renewed by stem cells located in specialized niches in the limbus at the cornea-conjunctiva junction. Loss or damage to the limbal stem cell pool can lead to limbal stem cell deficiency (LSCD), where homeostatic maintenance of the corneal epithelium is

This is an open access article under the terms of the Creative Commons Attribution-NonCommercial License, which permits use, distribution and reproduction in any medium, provided the original work is properly cited and is not used for commercial purposes.

© 2019 The Authors. STEM CELLS TRANSLATIONAL MEDICINE published by Wiley Periodicals, Inc. on behalf of AlphaMed Press

compromised, leading to ingrowth of the conjunctiva. Etiology includes autoimmune diseases (Steven-Johnson syndrome), infections (trachoma), contact lens wear, and thermal/alkali burns. LSCD may be partial or total depending on the extent of the damage.¹ Conjunctivalization is pathogenic for LSCD and is frequently accompanied by inflammation, neovascularization, persistent epithelial defects, and scarring resulting in decreased vision or blindness.

Several surgical and stem cell-based treatments for LSCD have been developed over the last decades.¹ Simple limbal epithelial transplantation (SLET) is a new treatment strategy introduced by Sangwan et al.² In this technique a small limbal biopsy is harvested from the healthy eye. The biopsy is divided into minute explant pieces that are distributed over human amniotic membrane (AM) and glued to the cornea (Figure 1). Outgrowth from individual explants merges with neighboring explant growth.⁴ Reepithelialization is typically achieved within 2 weeks. This review summarizes 404 cases in 31 clinical studies using SLET to date.

Significance statement

The present review examines work reporting simple limbal epithelial transplantation (SLET), an innovative technique that uses minimal limbal tissue from the healthy eye to regenerate the cornea in the limbal deficient diseased eye. Results since the introduction of SLET in 2012 suggest that the success rate is comparable to established techniques, conjunctival-limbal autograft and cultured limbal epithelial transplantation. However, SLET has the advantages of requiring a smaller biopsy, achieving harvest and transplantation in a single operation, and the unnecessary of cell culture laboratories. AlloSLET, a novel modification of SLET using allogeneic tissue, promises to further improve outcome through promotion of early resolution of inflammation in the injured/diseased eye.

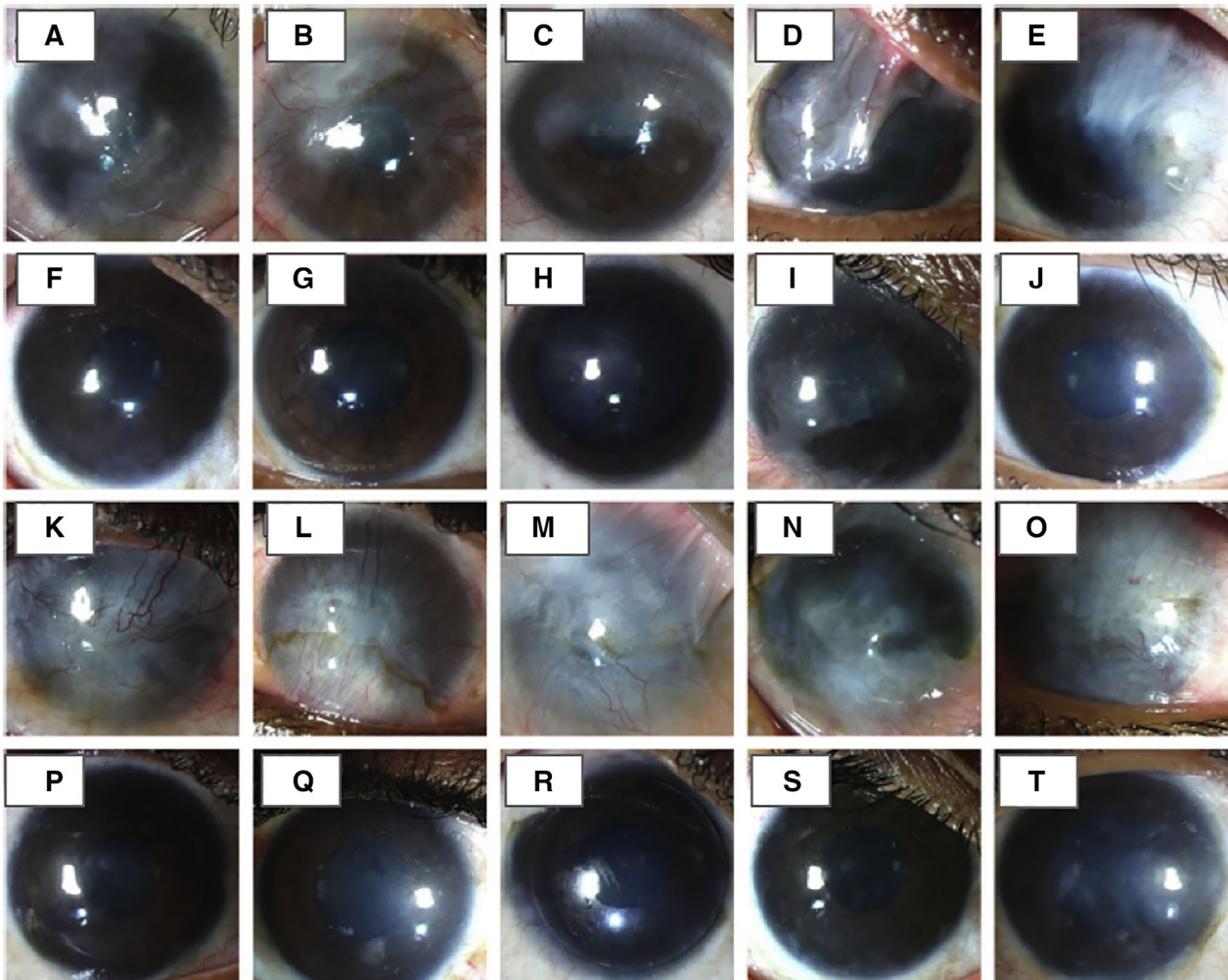


FIGURE 1 Illustration of 2-year outcomes following the use of simple limbal epithelial transplantation (SLET) for treatment of patients with partial and total limbal stem cell deficiency (LSCD). A-J, Patients with partial LSCD following ocular burns: A-F, Preoperative photographs and F-J, 2-year postoperative photographs showing a completely epithelized and stable corneal surface. K-U, Patients with total LSCD: K-O, Preoperative clinical photographs. P-T, 2-year postoperative photographs after SLET using Slit-lamp photography. Images reprinted from Basu et al³

2 | CURRENT OPTIONS FOR TREATMENT OF LSCD

Reepithelialization of the corneal surface and improved visual acuity are the primary and secondary aims in treating LSCD. Currently, there are two main surgical techniques available using autologous limbal tissue; conjunctival-limbal autograft (CLAU), and cultured limbal epithelial transplantation (CLET). In the CLAU technique two conjunctival-limbal biopsies are harvested (120° cornea circumference each as described in the original CLAU technique) and transferred directly to the affected limbal deficient eye.⁵ Thus, an advantage of this procedure is that it does not require the use of a transplant substrate, saving the expense of using AM. Published reviews summarizing results of CLAU report a success rate of between 80% and 100% and improvement in visual acuity of 25% and 100%, with a survival rate of 62% at 6-year follow-up.^{6,7}

The CLET technique depends on the culture of limbal biopsies to produce limbal cell sheets prior to transplantation.⁸ The introduction of the CLET procedure by Pellegrini et al. in 1997 offered a significant advantage over CLAU by harvest of a smaller amount of limbal tissue, minimizing the risk of iatrogenic injury to the healthy eye.⁸ Meta-analysis shows successful reepithelialization in 72% (n = 720) of cases and improved visual acuity in 63% (n = 539) of cases reporting the use of the standard CLET technique.⁹ This technique has been criticized for use of mouse cells and other xenogeneic components in preparation of the cultured sheets, potentially resulting in infection and quality variation.¹⁰ However, it is possible to substitute AM for mouse feeder cells.^{11,12} As evidence of its safety, in 2015, the CLET technique advanced to become the first stem cell-based therapy to receive approval for application throughout the European Union (EU) under the trade name “Holoclar”.¹³

Several non-limbal cell types have also shown promise in treating LSCD, offering options for treatment of bilateral LSCD using autologous cells and avoiding immunosuppression.¹⁴ Among alternatives, the cultured oral mucosal epithelial transplantation (COMET) technique has been most widely reported.¹⁵ Use of this tissue allows treatment of patients with Stevens-Johnson syndrome.¹⁶ The success rate for COMET is comparable to CLET, resulting in reepithelialization in 63% (n = 230) of reported cases and improved visual acuity in 68% (n = 202).¹⁷

2.1 | Current challenges in treatment of LSCD

Though complications are rare and reepithelialization of the donor site usually occurs, the risk associated with taking two large limbal biopsies from the healthy donor eye is a concern associated with CLAU.^{18–20} The CLET and COMET techniques address this challenge but require production of cultured sheets in a good manufacturing practice-regulated laboratory, which is expensive and limits accessibility. The COMET technique is promising, but peripheral neovascularization following surgery has been reported in many cases.¹⁶ The use of anti-angiogenic agents in concert with COMET has shown benefit. However,

inhibition of vascular endothelial growth factor has been shown to affect the overall wound healing response and induce corneal melt.²¹

SLET offers several advantages compared with the above options: (a) risk of iatrogenic damage to the donor eye is reduced; (b) a small biopsy means the procedure can be repeated if necessary; (c) SLET does not require expensive specialized culture facilities; and (d) The SLET procedure can be performed in one operation streamlining patient care, resource management, and reducing costs. Results of a recent study involving 125 patients show that SLET can be successfully used to treat partial and total LSCD (Figure 1).³

Treatment of bilateral LSCD remains a challenge. In addition to COMET, conjunctival-limbal allografts from a living-related relative (Ir-CLAL) or cadaveric tissue (keratolimbal allograft [KLAL]) are options. There have been two reports of modified SLET using allogeneic limbal tissue (alloSLET) to treat bilateral LSCD. AlloSLET compared with Ir-CLAL and KLAL procedures have so far not been directly compared. Regardless of the procedure, systemic immunosuppressants are critical for survival of allograft tissue.^{22,23} A standard of care and recommended duration of immunosuppressants necessary to prevent allograft rejection has yet to be defined.²² Large studies reporting KLAL and Ir-CLAL procedures suggest an average duration of 42²⁴–44²⁵ months, whereas the only large study reporting alloSLET for bilateral LSCD recommends gradual reduction over 2 years followed by the indefinite use of systemic and topical immunosuppressants.²³ Patients should be monitored for adverse systemic effects while taking immunosuppressants, which may include hypertension, diabetes mellitus, and biochemical abnormalities.²²

3 | CHARACTERISTICS OF SLET STUDIES

The present review is based on a search of the National Library of Medicine (PubMed) database using the term “simple limbal epithelial transplantation” that gave a list of 31 publications reporting pre-clinical results of SLET (Table S1) and one publication optimizing the SLET technique.²⁶

As of August 2019, 404 cases of SLET were reported. The eight largest case series' reported treatment of 125,³ 68,²⁷ 30,²⁸ 30,²⁹ 30,²³ 18,³⁰ 15,³¹ and 11³² eyes. These included the largest prospective study to date, with 125 patients and a follow-up period of at least 1 year³ and a multicenter international study of 68 patients.²⁷ The remaining 23 studies were noncomparative single case studies or case series of 10 eyes or less.^{2,4,33–52} One study directly compared SLET with CLAU, with 10 patients randomly assigned to each group.³³ The Sangwan group in India published the most studies.^{2,3,27,29,35,42–49} Other centers in India,^{4,23,28,30–33,39–41,51,52} England,³⁸ Brazil,³⁶ Mexico,³⁴ Thailand,⁵⁰ and the United States³⁷ also contributed.

4 | ETIOLOGY OF CASES TREATED WITH SLET

Grading LSCD severity is important since some cases of partial LSCD may not require stem cell transplant.^{53,54} SLET was mainly used in the

treatment of adults and children with unioocular total and partial LSCD resulting from burns and chemical injuries (Table S1). Patients with unilateral LSCD and a clinically non-inflamed wet ocular surface are ideal candidates for SLET.^{3,37} Preliminary reports also indicate that SLET has potential for use in non-LSCD ocular diseases; ocular surface squamous neoplasia (OSSN) (9 eyes),^{35,41,51} laryngo-onycho-cutaneous syndrome (1 eye),³⁹ pterygium (9 eyes),³⁴ and recurrent pterygium (4 eyes) if results are confirmed in larger studies.⁵⁵ However, pterygium can be treated using pterygium extended removal followed by autologous extended conjunctival grafting, which has a high success rate and is safe, simple, and fast to perform.⁵⁶

It has been shown that SLET can be used in patients with LSCD following failure of treatment with CLET.²⁹ At a mean follow-up of 2.3 years, 80% of the 30 eyes treated by SLET maintained a successful outcome without complications. Bilateral autoimmune diseases such as Steven-Johnsons syndrome and ocular cicatricial pemphigoid are contraindications for SLET using autologous tissue. A recent study also showed that scleral ischemia resulting from chemical injury is a poor prognostic indicator for success using SLET.³¹

SLET using biopsies of contralateral autologous tissue is most common. Although larger studies are necessary before recommendations can be made, recent case studies show the use of alloSLET for treatment of LSCD with a range of etiologies including extreme dry eye,⁴⁰ chemical injury,⁴⁷ and iatrogenic LSCD induced by mitomycin treatment for conjunctival melanoma.³⁸ Iyer et al. also suggested innovative use of alloSLET as an acute temporary biological bandage.³⁰ The goal of this treatment was to provide immediate stabilization of the wound environment, minimize more serious damage, and prepare the wound for future SLET using autologous tissue.

5 | THE SLET TECHNIQUE

Most studies used the original autologous SLET technique described by Sangwan et al. harvesting a small biopsy of limbal tissue from the healthy eye.² In summary, the injured eye is prepared with a 360° peritomy, and the vascular pannus covering the cornea is removed (Figure S1). The eye is covered by AM to the extent of the peritomy, secured with fibrin glue (Figure S1A). A small 2 × 2 mm biopsy (30° cornea circumference) is excised from the superior limbus of the healthy eye and placed in a balanced salt solution (Figure S1B). The limbal tissue biopsy is subsequently cut into tiny pieces that are fixed onto the AM epithelial side up in a circular arrangement (avoiding the visual axis) using fibrin glue (Figure S1C). A soft bandage contact lens is then applied along with topical antibiotics and corticosteroids for the first week or until healed (Figure S1D). A second layer of AM instead of the contact lens can also be used.^{37,55} Use of cryopreserved AM instead of fresh AM has been shown to be equally effective and allows the use of this procedure in the United States.³⁷ Partial LSCD can be treated using a modified SLET technique, where superficial keratectomy is performed only in areas of fibrovascular pannus, thus avoiding the intact limbus areas.^{3,28}

The SLET procedure has also been used as a preventative measure against development of LSCD. Wide excisional biopsies of ocular surface squamous neoplasia and SLET can be performed in the same procedure to prevent LSCD after resection.^{35,41}

When severe stromal opacification is present, patients will additionally require penetrating keratoplasty (PK). It is sometimes necessary to perform PK simultaneously with SLET if patients are unwilling to undergo a second operation.²⁷ Results from the three largest studies point to a correlation of failure with simultaneous performance of PK with SLET.^{3,27,28} Furthermore, SLET improves the corneal environment, which may promote self-clearing of the stroma.^{3,28} Therefore, delaying PK for at least a year post-SLET is recommended. In support of this, a large multicenter study reported an overall success rate of 84% (n = 68), but this dropped to 20% in the eight eyes receiving simultaneous PK and SLET.²⁷ However, the authors cautioned that the unsuccessful cases may have presented with more serious etiology. Singh et al. described performance of deep anterior lamellar keratoplasty in pediatric patients 9–15 months post-SLET giving visual improvement of 64% (n = 11).³²

Failure of SLET is correlated with regeneration of the cornea by migrating conjunctival cells.⁵⁰ Thus, *in vivo* confocal microscopy and impression cytology can be useful in determining the phenotype of regenerated epithelium on the cornea, allowing early diagnostic assessment of failure and management before clinical symptoms appear.⁵⁰

6 | MECHANISM OF REGENERATION

The success of SLET is in large part attributed to *in vivo* expansion of transplanted explants on the corneal surface. However, the exact mechanism in terms of the individual contribution of fibrin glue, AM, limbal biopsy size, distribution of the biopsies, preexisting stem cells, and migration pattern of transplanted cells is as yet unknown. Detailed discussion of the role of these factors in reestablishing an epithelialized cornea is beyond the scope of the present review. The proposed benefits of the major components, fibrin glue and AM, and the source of proliferating stem cells will be briefly discussed here.

Fibrin glue was first reported as a replacement for sutures in an AM transplantation (AMT) procedure in 11 patients with partial LSCD.⁵⁷ Here, reepithelialization was achieved through growth from residual limbal and corneal tissue, without the need to transplant limbal cells. Kheirkhah and colleagues suggested that the glue forms a full contact seal between the transplanted AM and the corneal surface, ensuring reepithelialization occurs on the surface of the AM rather than underneath, taking full advantage of the AM microenvironment.⁵⁷ *in vitro* work has shown that fibrin glue inhibits cell migration, which in SLET may prevent ingrowth of conjunctival tissue at a critical phase and promote expansion of epithelial cells from explants on the AM surface.⁵⁸ Growth rates vary between explants from the same donor placed in the same eye, which may be attributed to the amount of fibrin glue used for their individual attachment or to differences in handling during transplant.⁴ Fibrin glue has also been shown to extend the beneficial effects of AM by delaying its breakdown compared with sutures.^{7,57}

The main benefit of AM is in its early application to control inflammation. It provides a substrate to promote the formation of a well-differentiated stratified corneal epithelium.⁵⁹ The advantage of the addition of limbal tissue in SLET (compared with AM alone as used in the AMT procedure) is highlighted where limbal explants have been lost postoperatively, resulting in failure of SLET despite the presence of AM.³ Amescua et al. used ultra-high-resolution optical coherence tomography to reveal that the transplanted AM persisted at least 4 months post-SLET (in one patient).³⁷

The relative contribution of transplanted cells and residual surviving stem cells to the regenerated epithelium is unknown. A stable source of proliferating stem cells is necessary to restore long-term homeostasis of the corneal epithelium. These may be established through transplanted stem cells becoming embedded or by dormant residual stem cells becoming reactivated. It is possible that in some cases removal of fibrotic tissue and paracrine signals from transplanted explants is sufficient to stimulate residual stem cells to resume their homeostatic function. Preliminary investigation to resolve these questions has revealed the presence of focal points of basal layer cells expressing putative markers for stem cells (Δ Np63 α and ABCG2) post-SLET³; the presence of a mix of patient and donor cells on the cornea several months post-alloSLET³⁰; and patches of outgrowth emerging from individual explants growing in a centripetal pattern that eventually merge with outgrowth from neighboring explants.³⁷ Although it is clear that the role of transplanted cells needs further investigation in larger studies, these initial analyses suggest that the rapid reepithelialization seen post-SLET can be attributed, at least in part, to transplanted proliferating cells from limbal explants.

7 | RESULTS

Most studies used reversal of the main features of LSCD as the primary measure of success. This is defined as complete reepithelialization, a clinically stable corneal epithelium and reversal of vascularization.⁶⁰ Improved visual acuity was used as a secondary definition of success. Reported follow-up periods ranged from 6 to 59 months. Failure usually occurred within 6 months of surgery (Table 1). Combined results show that 83% (n = 336) of SLET operations were successful by the primary criterion and visual acuity improved in 69% of cases (n = 258) (Table 1). Summarizing results by severity, the success rates were 74.2% (n = 35) for partial LSCD and 76.8% (n = 151) for total LSCD (Table 1).

The overall success rate compares well with other procedures that use autologous limbal tissue.^{7,9,17} A direct comparison between SLET and CLAU performed on patients with the same etiology and in the same clinical setting supports SLET as an equally safe and effective treatment for LSCD.³³ A primary success rate of 62.5% (n = 30) was also reported where SLET was performed in cases of failed CLET.²⁹

The success rate declined in treatment of pediatric patients with LSCD, with a rate of 71% compared with 85.5% in adults.^{3,28,52} Successful treatment of pediatric LSCD using CLET has also been disappointing (46.7%),⁶¹ suggesting pediatric LSCD is especially challenging. This could be linked to the pressure for young patients to undergo

surgery earlier (before inflammation is fully controlled) in order to reduce the risk of developing amblyopia (lazy eye),²⁸ which often accompanies sensory vision loss. Furthermore, ocular inflammation is correlated with failure⁶² and children generally experience more inflammation.⁶³

Overall, SLET compares well with other procedures (CLAU, CLET, COMET) that use autologous tissue for treatment of LSCD, resulting in similar average primary and secondary criteria success rates. Importantly, SLET has now been validated in several larger studies and in several international centers since the first published report in 2012.^{3,27-29} Many studies have reported long-term success, with follow-up periods of 12 to 59 months (Tables 1 and 2).^{3,27,28,30,35,38,39}

8 | RISK FACTORS FOR FAILURE AND COMPLICATIONS

8.1 | Preoperative

The presenting features of the patient eye should be considered when deciding treatment. Absolute contraindications include a dry ocular surface, blind eye with no visual potential, disorganized anterior segment, and the continued presence of adnexal pathologies.²³ Presentation with LSCD resulting from acid injury is also correlated with failure.²⁸ The association of presenting features with prognosis post-SLET has been summarized in a review by Shanbhag et al. (see their table 1²³).

Preexisting symblepharon is correlated with failure.^{3,27,28} According to Basu et al., the presence of symblepharon extending toward the cornea pre-SLET could indicate conjunctival deficiency, and outcomes may improve if symblepharon is addressed before or at the time of SLET.³ A retrospective case series of four children where only one patient had a completely successful outcome also noted that recurrence of LSCD coincided with areas of severe preoperative symblepharon.⁵² The three partial success patients had initially presented with more severe injury and extensive LSCD. Thus, authors suggested that damage to conjunctival stem cells may have contributed to failure. Repeat SLET combined with conjunctival autograft transplant resulted in reepithelialization and an avascular surface.

Optimization of the ocular surface including fast resolution of inflammation prior to SLET is important to give the best chance for successful outcome, especially in pediatric cases.^{3,27,52} Glucocorticoids and AM transfer are often used to reduce inflammation in the acute phase and induce epithelialization. Iyer and colleagues have shown that alloSLET can also be successfully used for this purpose.³⁰

8.2 | Intraoperative

Based on poor results when combining PK with CLET, Basu and colleagues recommend identifying patients with thin corneas by optical coherence tomography or ultrasound bio-microscopy before surgery so that lamellar corneal graft can be performed simultaneously with SLET if required.^{3,64}

TABLE 1 Outcomes of studies using simple limbal epithelial transplantation (SLET)

References	Surgery	No. of patients	Stable corneal epithelium %	Improvement in visual acuity %	Complications in recipient eye	Follow-up period
1 Shambhag et al. ²³	AlloSLET: Living-related alloSLET x16 Cadaveric x14	30	83.3% (25/30) 14/16 (87.5%) in Living-related 11/14 (78.6%) in cadaveric	60% (18/30)		Median 28 months (range, 13-66 months)
2 Prabhasawat et al. ⁵⁰	SLET x5 Living-related alloSLET x5	10 eyes in 9 patients	70% (7/10)	70% (7/10) Ranging within improvement to 6/60 or better from HM	Failure: Central/peripheral neovascularization correlated with regrowth by conjunctival cells x3	3-18 months
3 Gupta et al. ³¹	SLET 6 months later x15	7 x non-isch. 8 x isch.	75% (6/8) in non-isch. 29% (2/7) in isch.			1 year
4 Narang et al. ⁵¹	SLET x1	1	100% (1/1)	Unchanged x1	Cataract	31 months
5 Mednick et al. ⁵⁵	Pterygium surgery + adjunct mitomycin C treatment	4	100% (4/4)	100% (4/4)	Symblepharon x1 Pterygium in new area x1 Neovascularization resolved with anti-VEGF injections x1	8-30 months
6 Gupta et al. ²⁸	Repeated SLET x1 resulted in failure PK x3	30	Partial 66.6% (10/15) Total 73.3% (11/15)	71.4 % of patients BCVA at presentation: 20/200 or worse (blindness) x24 20/70-20/160 (low vision) x2 20/60 or better x4 Final BCVA: 20/200 or worse (blindness) x19	Progressive conjunctivalization (30%) Foreign body sensation in donor eye (x3; 10%)	1.1 years (range, 6 months-3.5 years)
7 Basu et al. ²⁹	PK x1 Corneal transplantation x4 Repeated SLET x2	30	80% (24/30)	63% of successful outcomes (15/24) Improved to 20/200 or better	Recurrence of LSCD x6 (20%) Hemorrhage beneath the AM x2 (7%) Persistent epithelial defect with corneal graft infiltrate x1 (3%) Donor eye: Subconjunctival hemorrhage x6 (20 %)	2.3 ± 1.5 years
8 Singh et al. ³²	DALK 9-15 months after SLET x11	11	82% (9/11)	64% (7/11) Improvement by ≥2 lines	Recurrence of keratolimbal vascularization or conjunctivalization with graft opacification x2 Focal recurrences of mild keratolimbal conjunctivalization/vascularization x9 Mid-to-deep stromal involvement with visual axis opacification x9 Deeper stromal involvement of varying degrees which did not involve the visual axis x2	11.63 ± 2.21 months

(Continues)

TABLE 1 (Continued)

References	Surgery	No. of patients	Stable corneal epithelium %	Improvement in visual acuity %	Complications in recipient eye	Follow-up period
9 Vasquez-Perez ³⁸	PK	1	100% (1/1)	100% (1/1) From hand movements to 6/12	Recurrence of herpes simplex keratitis x1	>20 months
10 Mohamed et al. ³⁹		1	100% (1/1)	100% (1/1) 20/160 improved to 20/40 vision	Focal LSCD and recurrence of symblepharon x1 Recurrence of granulation tissue x1	18 months
11 Kaliki et al. ³⁵	Wide excisional biopsy of OSSN + Primary SLET x7 Plaque radiotherapy x3	7	Clear cornea: 71.4% (5/7)		Peripheral corneal opacity x2 (29%)	12 months
12 Arora et al. ³³		10 SLET 10 CLAU	100% (20/20)	100% (20/20) Preoperative in SLET group was 2.13 ± 1.0, which improved to 1.53 ± 0.72 and 1.62 ± 0.86 at 3 and 6 months, respectively	SLET group: Hemorrhage under AM x1 (Spontaneous resolution) No complications at donor site in either group	6 months
13 Iyer et al. ³⁰	AlloSLET Subsequent limbal autograft (SLET technique) x5	17 (18 eyes)	94.11% (17/18)	72.2% (13/18) Better than 20/120	Gradual failure of allograft x7 Symblepharon formation x3 (16.7%)	10.28 ± 6.7 (3-23) months
14 Basu et al. ³	Standard SLET + modified for partial LSCD x125 PK x10 Cataract surgery x5	125	76% (95/125) overall Adults—Tot. 80% (44/55) Adults—Part. 80% (8/10) Children—Tot. 71.2% (37/52) Children—Part. 76% (6/8)	75.2% (94/125) overall Two-line improvement	Donor eye: Subconjunctival hemorrhage x35 (28%) Pyogenic granuloma x2 (1.6%) LSCD x0 Recipient eye: Conjunctivalization x23 (18.4%) Symblepharon x21 (16.8%) Hemorrhage under hAM x10 (8%) Loss of transplants x7 (5.6%) Detached hAM x4 (3.2%) Keratitis x8 (6.4%) Corneal melting with perforation x2 (1.6%) Lignocaine allergy x1 (0.8%)	1.5 years (range, 1-4 years)
15 Arya et al. ⁴⁰	Standard + cadaveric AlloSLET	2	100% (2/2)	100% (2/2) Case 1: From HM to 20/20 by six weeks Case 2: From light perception to hand movements close to the face	Case 2: underlying optic atrophy	3 months

(Continues)

TABLE 1 (Continued)

References	Surgery	No. of patients	Stable corneal epithelium %	Improvement in visual acuity %	Complications in recipient eye	Follow-up period
16 Queiroz et al. ³⁶		4	50% (2/4)	25% (1/4) From hand motion to 20/80 vision	No adhesion of limbal grafts to cornea x1 Recurrence of corneal neovascularization and persistent epithelial defect x1	6 months
17 Vazirani et al. ²⁷		68	83.8% (57/68)	64.7% (44/68) 20/200 or better	Focal recurrences of pannus not progressing to the center of the cornea x21 (30.9%) Microbial keratitis x5 Ocular hypertension secondary to steroid use x1 Pyogenic granuloma x1 Focal iatrogenic LSCD at the site of the donor limbus x1	>6 months. Median, 12 months. Range, 6-59 months
18 Mittal et al. ⁴¹	Excisional biopsy of cornea/limbus + SLET in same setting Radiotherapy	1	100% (1/1)	100% (1/1) From 20/50 to 20/40	None	2 years
19 Mittal et al. ⁵²	Repeated SLET with conjunctival autograft x3	4	100% (4/4)	100% (4/4) From PLPR to counting fingers close to face x1 From PR to 6/36 x 2 From HM to 6/18 x 1	LSCD focal recurrence with symblepharon x3	12-60 months after first SLET and 13-36 months after repeat SLET
20 Vazirani et al. ⁴²	Customized SLET for treating focal recurrent conjunctivalization after SLET	1	100% (1/1)	100% (1/1) From light perception to 20/50	Focal recurrences of conjunctivalization on the cornea and recurrence of symblepharon after first SLET x1	5 months
21 Nair et al. ⁴³	Cataract surgery	1	100% (1/1)	100% (1/1) From light perception to 20/60	Recurrence LSCD x1	7 months
22 Bogantes ³⁴	Pterygium surgery + SLET	10 eyes in 9 patients	100% (10/10)		Pyogenic granuloma at the junction of AM and conjunctiva x1	8 months
23 Das et al. ⁴⁴		1	100% (1/1)	100% (1/1) From counting fingers at 1m to 20/50		27 months
24 Mittal et al. ⁴		5	100% (5/5)	80% (3/5) 2 line improvement	SPK x2 Resolved after increasing lubricant	10.8 months (range, 8-36 months)
25 Amescua et al. ³⁷		4	100% (4/4)	100% (4/4) From worse than 20/200 to 20/50 or better		7.5 ± 1.3 months
26 Vazirani et al. ⁴⁵	Conjunctival autografting with supplemental SLET x1	1	100% (1/1)	100% (1/1) From light perception to 20/40	Recurrence of LSCD with symblepharon and fornical shortening x1	6 months

(Continues)

TABLE 1 (Continued)

References	Surgery	No. of patients	Stable corneal epithelium %	Improvement in visual acuity %	Complications in recipient eye	Follow-up period
27 Lal et al. ⁴⁶		1	100% (1/1)	100% (1/1) From 20/50 to 20/25		2 years
28 Bhalekar et al. ⁴⁷		1	100% (1/1)	100% (1/1) From hand motions to 20/100	Allograft rejection managed with aggressive immune suppression	6 months
29 Bhalekar et al. ⁴⁸		1	100% (1/1)	100% (1/1) Improved to 20/80		13 months
30 Bhalekar et al. ⁴⁹		1		100% (1/1) From light perception with accurate projection to 20/200	Whitish plaque and corneal epithelial hyperplasia ×1	3 weeks
31 Sangwan et al. ²	Original SLET protocol	6	100% (6/6)	66.6% (4/6) From worse than 20/200 in all recipient eyes to 20/40 or better in four eyes		9.2 ± 1.9 months

Abbreviations: AMT, amniotic membrane transplantation; BCVA, best corrected visual acuity; CLET, cultivated limbal epithelial transplantation; DALK, deep anterior lamellar keratoplasty; HM, hand movements; ISCH, ischemia; LSCD, limbal stem cell deficiency; LSCT, limbal stem cell transplantation; MMC, mitomycin C; OSSN, ocular surface squamous neoplasia; Part., partial LSCD; PK, penetrating keratoplasty; PLPR, hand motions, accurate projection of rays; SLET, simple limbal epithelial transplantation; SPK, superficial punctuate keratitis; Tot., total LSCD.

8.3 | Postoperative

The most common complications following SLET reported in the three largest follow-up studies (involving 125,³ 68,²⁷ and 30²⁸ patients) were focal recurrence of LSCD,²⁷ progressive conjunctivalization,^{3,28} progressive symblepharon,³ and keratitis (Table 1).^{3,27} More unusual complications were loss of transplants following surgery,³ epithelial defects that persisted for more than 6 months,^{29,36} and pyogenic granuloma.^{3,27,34}

One study reported corneal epithelial hyperplasia following SLET in an 11-year-old boy.⁴⁹ The authors suggested that in young patients the contact lens should be removed as soon as possible after corneal epithelialization is complete due to the high rate of cell proliferation that is typically seen.

A trial of 30 patients who underwent SLET after failed CLET reported zero cases of iatrogenic LSCD despite harvest of multiple biopsies from donor eyes.²⁹ Harmless subconjunctival hemorrhage after biopsy harvest, which resolved within 1 month was noted in 28% of donor eyes in the largest study involving 125 patients.³ Iatrogenic LSCD at the site of the donor limbus was also noted in one patient.

In summary, preexisting symblepharon and simultaneous performance of PK with SLET are the main features correlated with SLET failure. Complications following SLET are relatively benign and manageable. The risk of iatrogenic LSCD at the donor site is also low even after harvest of multiple biopsies for repeat SLET.

9 | ALLOGENIC SLET

Very little has been published on the use of alloSLET for permanent restoration of the cornea for treatment of bilateral LSCD. Bilateral LSCD often occurs secondary to Stevens-Johnson syndrome, mucous membrane pemphigoid (MMP), and severe chemical burns, which produce extensive cicatrization or dryness making patients unsuitable candidates for treatment with SLET.²³ A total of 56 eyes in six separate studies have used alloSLET.^{23,30,38,40,47,50} Immunosuppressant steroids were prescribed topically (19 eyes^{30,38}), systemically (1 eye⁴⁷), or in combination (30 eyes²³). Transplant rejection can be managed by increasing the dose of systemic and topical immunosuppressants.^{23,47} A total of 30 eyes were treated in the largest alloSLET study reported so far; 16 eyes received living-related donor tissue and 14 eyes of 13 patients received cadaveric donor tissue.²³ At the final follow-up (median 28 months), the overall improvement in visual acuity was from hand-motion to 20/60 in more than 60% of eyes. Achievement of a stable corneal surface indicating successful outcome varied slightly between the two groups with success noted in 14 of 16 (87.5%) eyes receiving living-related SLET and in 11 of 14 (78.6%) eyes in the cadaveric group at the final follow-up (average 28 months). No serious systemic complications were noted. These results compare well with typical results using Ir-CLAL and KLAL techniques, for example, in a large retrospective case series 105 of 136 patients (77.2%) achieved ocular surface stability.²⁴

Iyer et al. investigated the effectiveness of alloSLET in management of acute inflammation in 17 patients (18 eyes) with severe grade 4 or worse chemical injury (Dua's classification).³⁰ Ten of the patients were children with an age range of 3 months to 10 years. Systemic immunosuppressants were not used since later rejection of allogenic transplants was expected. Follow-up ranged from 3 to 23 months. The authors performed alloSLET with the intention of aiding fast epithelialization of the denuded cornea and to promote early reconstruction of the corneal surface and not with an aim toward long-term survival of the allogenic cells (Figure S2). They speculated that the small size of the allogenic explants may have reduced the antigenic load leading to slow rejection. Complete reepithelialization was achieved within 10-40 days in 17 of 18 (94%) eyes. Improved visual acuity was seen in 13 of 17 (76%) patients. Symblepharon involving one or two quadrants was noted in three eyes.

Iyer and colleagues hypothesize that early resolution of inflammation facilitated by the use of AM and topical steroids may have been influential in preventing further damage to residual stem cells.³⁰ Furthermore, early reepithelialization by allogenic explants may have also reduced ocular surface inflammation allowing residual stem cells to repopulate the cornea.

Though studies are so far limited, reports suggest that use of AM in the alloSLET procedure and regeneration of an epithelial layer using allogenic explants quietens inflammation on the ocular surface. Therefore, in addition to offering an alternative treatment for bilateral LSCD, alloSLET may be especially applicable for fast temporary treatment of pediatric patients, where inflammation has been reported as a key factor hindering successful outcome. AlloSLET offers the advantage of quickly restoring a clear epithelial layer, albeit of a temporary nature, which aids in improvement in visual acuity as early as a month following injury.³⁰ Thus, the risk of amblyopia can be reduced or addressed earlier in pediatric patients. Importantly, the use of allogeneic tissue as a temporary application maintains an undisturbed healthy alternate eye. Valuable autologous limbal tissue can then later be harvested for use in SLET once inflammation in the injured eye has subsided, giving a higher chance of success.

10 | FUTURE STUDIES

The AM carrier could be a critical factor to the success of SLET. It contains anti-inflammatory cytokines, growth factors, and provides a substrate that may allow stem cells in SLET explants to embed. SLET results may be further improved with the use of cross-linked AM.⁶⁵ Comparison of the effect of using denuded vs. intact AM would also be useful. Consideration of a standardized synthetic replacement for AM could also be evaluated to eliminate the inherent variability found in AM, a natural tissue.

Cumulative results show that although regeneration of the corneal epithelium occurs in 83.5% of SLET operations, visual acuity is improved in only 68.7% of patients (Table 1). Avenues for improvement include the pursuit of work indicating that inflammation plays a key role in SLET operations with poor outcomes.³ Inflammatory state

may be influenced by the time between injury and operation, as reported in several studies.^{3,28,62} To advance the treatment of LSCD in children, it may be necessary to focus on faster resolution of inflammation before SLET.²⁸ Temporary application of alloSLET may accomplish this, and larger studies are needed to confirm.³⁰

Mittal et al. showed that individual explants from the same donor often vary in outgrowth.⁴ Follow-up studies could optimize the amount of fibrin glue used for mounting explants, as well as limbal explant size, orientation, harvest site, and handling techniques.

Although SLET minimizes the amount of biopsy harvested from the donor eye, the same technique using an alternative source of autologous tissue may have the additional benefit of offering treatment of bilateral LSCD. Oral mucosal tissue has proved effective in treating LSCD transplanted as cultured sheet transplants (COMET).^{15,66} Transfer of small oral mucosal biopsies in a simple oral mucosal epithelial transplantation (SOMET) technique would avoid the need to harvest ocular limbal material altogether.

Direct comparison of the effectiveness of CLAU, CLET, and SLET in a large randomized prospective study would be useful.

11 | CONCLUSION

In conclusion, results so far indicate that SLET offers a comparable alternative to CLAU and CLET using the two main criteria for success: corneal re-epithelialization and improvement in visual acuity. In addition, there are advantages to harvesting a smaller biopsy for transplant, such as lowered risk of iatrogenic LSCD and the option for repeat operations. Importantly, harvest and transplantation are accomplished in a single operation, which increases efficiency, promotes accessibility, and reduces cost. Latest work shows limbal allografts can be used successfully in treatment of bilateral LSCD.

Direct transfer of limbal explants may support superior maintenance of stem cell phenotype and function following transplant. On the other hand, analysis of biopsies used for CLET transplants has shown a correlation between clinical success and stem cell content suggesting stem cells are maintained during culture.⁶⁷ The opportunity for gene editing prior to transplantation may also be an important advantage of the CLET technique.

Long-term follow-up studies equivalent to CLAU and CLET are now becoming available, and results using SLET are promising. AlloSLET used as a temporary treatment to resolve initial inflammation and quickly recover an intact epithelial layer also holds great potential. This may be especially important in treating pediatric cases of LSCD. Avenues for improvement should be further explored, including the feasibility of using non-limbal autologous tissue from the oral cavity for treatment of bilateral LSCD (SOMET).

CONFLICT OF INTEREST

The authors indicated no potential conflicts of interest.

AUTHOR CONTRIBUTIONS

C.J.J.: conception and design, collection of studies, analysis and interpretation of studies, manuscript writing, final approval of manuscript; I.T.M.E., H.R.: collection of studies, manuscript writing, analysis and interpretation of studies, final approval of manuscript; K.A.T., D.A.D.: conception and design, analysis and interpretation of studies, final approval of manuscript; T.P.U.: conception and design, analysis and interpretation of studies, manuscript writing, final approval of manuscript.

DATA AVAILABILITY STATEMENT

Data sharing is not applicable to this article as no new data were created or analyzed in this study.

ORCID

Catherine J. Jackson  <https://orcid.org/0000-0001-9683-2343>

Tor P. Utheim  <https://orcid.org/0000-0002-3821-6777>

REFERENCES

- Utheim TP. Limbal epithelial cell therapy: past, present, and future. *Methods Mol Biol.* 2013;1014:3–43.
- Sangwan VS, Basu S, MacNeil S, et al. Simple limbal epithelial transplantation (SLET): a novel surgical technique for the treatment of unilateral limbal stem cell deficiency. *Br J Ophthalmol.* 2012;96:931–934.
- Basu S, Sureka SP, Shanbhag SS, et al. Simple limbal epithelial transplantation: long-term clinical outcomes in 125 cases of unilateral chronic ocular surface burns. *Ophthalmology.* 2016;123:1000–1010.
- Mittal V, Jain R, Mittal R. Ocular surface epithelialization pattern after simple limbal epithelial transplantation: an in vivo observational study. *Cornea.* 2015;34:1227–1232.
- Kenyon KR, Tseng SC. Limbal autograft transplantation for ocular surface disorders. *Ophthalmology.* 1989;96:709–722.
- Yin J, Jurkunas U. Limbal stem cell transplantation and complications. *Semin Ophthalmol.* 2018;33:134–141.
- Liang L, Sheha H, Li J, et al. Limbal stem cell transplantation: new progresses and challenges. *Eye.* 2009;23:1946–1953.
- Pellegrini G, Traverso CE, Franzl AT, et al. Long-term restoration of damaged corneal surfaces with autologous cultivated corneal epithelium. *Lancet.* 1997;349:990–993.
- Holland EJ. Management of limbal stem cell deficiency: a historical perspective, past, present, and future. *Cornea.* 2015;34:S9–S15.
- Schwab IR, Johnson NT, Harkin DG. Inherent risks associated with manufacture of bioengineered ocular surface tissue. *Arch Ophthalmol.* 2006;124:1734–1740.
- Utheim TP, Lyberg T, Raeder S. The culture of limbal epithelial cells. *Methods Mol Biol.* 2013;1014:103–129.
- Tsai RJ, Li LM, Chen JK. Reconstruction of damaged corneas by transplantation of autologous limbal epithelial cells. *N Engl J Med.* 2000;343:86–93.
- Pellegrini G, Ardigo D, Milazzo G, et al. Navigating market authorization: the path holoclar took to become the first stem cell product approved in the European Union. *STEM CELLS TRANSLATIONAL MEDICINE.* 2018;7:146–154.
- Sehic A, Utheim OA, Ommundsen K, et al. Pre-clinical cell-based therapy for limbal stem cell deficiency. *J Funct Biomater.* 2015;6:863–888.
- Nakamura T, Inatomi T, Sotozono C, et al. Transplantation of cultivated autologous oral mucosal epithelial cells in patients with severe ocular surface disorders. *Br J Ophthalmol.* 2004;88:1280–1284.
- Prabhasawat P, Ekpo P, Uprasertkul M, et al. Long-term result of autologous cultivated oral mucosal epithelial transplantation for severe ocular surface disease. *Cell Tissue Bank.* 2016;17:491–503.
- Utheim TP. Concise review: Transplantation of cultured oral mucosal epithelial cells for treating limbal stem cell deficiency-current status and future perspectives. *STEM CELLS.* 2015;33:1685–1695.
- Jenkins C, Tuft S, Liu C, et al. Limbal transplantation in the management of chronic contact-lens-associated epitheliopathy. *Eye.* 1993;7:629–633.
- Tan DT, Ficker LA, Buckley RJ. Limbal transplantation. *Ophthalmology.* 1996;103:29–36.
- Miri A, Said DG, Dua HS. Donor site complications in autolimbal and living-related allolimbal transplantation. *Ophthalmology.* 2011;118:1265–1271.
- Baradaran-Rafii A, Eslani M, Haq Z, et al. Current and upcoming therapies for ocular surface chemical injuries. *Ocul Surf.* 2017;15:48–64.
- Ballios BG, Weisbrod M, Chan CC, et al. Systemic immunosuppression in limbal stem cell transplantation: best practices and future challenges. *Can J Ophthalmol.* 2018;53:314–323.
- Shanbhag SS, Patel CN, Goyal R, et al. Simple limbal epithelial transplantation (SLET): review of indications, surgical technique, mechanism, outcomes, limitations, and impact. *Indian J Ophthalmol.* 2019;67:1265–1277.
- Holland EJ, Mogilishetty G, Skeens HM, et al. Systemic immunosuppression in ocular surface stem cell transplantation: results of a 10-year experience. *Cornea.* 2012;31:655–661.
- Ang AY, Chan CC, Biber JM, et al. Ocular surface stem cell transplantation rejection: incidence, characteristics, and outcomes. *Cornea.* 2013;32:229–236.
- Kethiri AR, Basu S, Shukla S, et al. Optimizing the role of limbal explant size and source in determining the outcomes of limbal transplantation: An in vitro study. *PLoS One.* 2017;12:e0185623.
- Vazirani J, Ali MH, Sharma N, et al. Autologous simple limbal epithelial transplantation for unilateral limbal stem cell deficiency: multicentre results. *Br J Ophthalmol.* 2016;100:1416–1420.
- Gupta N, Joshi J, Farooqui JH, et al. Results of simple limbal epithelial transplantation in unilateral ocular surface burn. *Indian J Ophthalmol.* 2018;66:45–52.
- Basu S, Mohan S, Bhalekar S, et al. Simple limbal epithelial transplantation (SLET) in failed cultivated limbal epithelial transplantation (CLET) for unilateral chronic ocular burns. *Br J Ophthalmol.* 2018;102:1640–1645.
- Iyer G, Srinivasan B, Agarwal S, et al. Outcome of allo simple limbal epithelial transplantation (alloSLET) in the early stage of ocular chemical injury. *Br J Ophthalmol.* 2017;101:828–833.
- Gupta N, Singh A, Mathur U. Scleral ischemia in acute ocular chemical injury: long-term impact on rehabilitation with limbal stem cell therapy. *Cornea.* 2019;38:198–202.
- Singh D, Vanathi M, Gupta C, et al. Outcomes of deep anterior lamellar keratoplasty following autologous simple limbal epithelial transplant in pediatric unilateral severe chemical injury. *Indian J Ophthalmol.* 2017;65:217–222.
- Arora R, Dokania P, Manudhane A, et al. Preliminary results from the comparison of simple limbal epithelial transplantation with conjunctival limbal autologous transplantation in severe unilateral chronic ocular burns. *Indian J Ophthalmol.* 2017;65:35–40.
- Hernandez-Bogantes E, Amescua G, Navas A, et al. Minor ipsilateral simple limbal epithelial transplantation (mini-SLET) for pterygium treatment. *Br J Ophthalmol.* 2015;99:1598–1600.
- Kaliki S, Mohammad FA, Tahilian P, et al. Concomitant simple limbal epithelial transplantation after surgical excision of ocular surface squamous neoplasia. *Am J Ophthalmol.* 2017;174:68–75.

36. Queiroz AG, Barbosa MM, Santos MS, et al. Assessment of surgical outcomes of limbal transplantation using simple limbal epithelial transplantation technique in patients with total unilateral limbal deficiency. *Arq Bras Oftalmol.* 2016;79:116–118.
37. Amescua G, Atallah M, Nikpoor N, et al. Modified simple limbal epithelial transplantation using cryopreserved amniotic membrane for unilateral limbal stem cell deficiency. *Am J Ophthalmol.* 2014;158:469–475.e462.
38. Vasquez-Perez A, Nanavaty MA. Modified allogenic simple limbal epithelial transplantation followed by keratoplasty as treatment for total limbal stem cell deficiency. *Ocul Immunol Inflamm.* 2017;26:1–3.
39. Mohamed A, Sangwan VS. Ocular surface reconstruction in laryngoonycho-cutaneous syndrome. *Ocul Immunol Inflamm.* 2017;25:460–462.
40. Arya SK, Bhatti A, Raj A, et al. Simple limbal epithelial transplantation in acid injury and severe dry eye. *J Clin Diagn Res.* 2016;10:ND06–ND07.
41. Mittal V, Narang P, Menon V, et al. Primary simple limbal epithelial transplantation along with excisional biopsy in the management of extensive ocular surface squamous neoplasia. *Cornea.* 2016;35:1650–1652.
42. Vazirani J, Lal I, Sangwan V. Customised simple limbal epithelial transplantation for recurrent limbal stem cell deficiency. *BMJ Case Rep.* 2015;2015.
43. Nair D, Mohamed A, Sangwan VS. Outcome of cataract surgery following simple limbal epithelial transplantation for lime injury-induced limbal stem cell deficiency. *BMJ Case Rep.* 2015;2015.
44. Das S, Basu S, Sangwan V. Molten metal ocular burn: long-term outcome using simple limbal epithelial transplantation. *BMJ Case Rep.* 2015;2015.
45. Vazirani J, Basu S, Sangwan V. Successful simple limbal epithelial transplantation (SLET) in lime injury-induced limbal stem cell deficiency with ocular surface granuloma. *BMJ Case Rep.* 2013;2013.
46. Lal I, Panchal BU, Basu S, et al. In-vivo expansion of autologous limbal stem cell using simple limbal epithelial transplantation for treatment of limbal stem cell deficiency. *BMJ Case Rep.* 2013;2013.
47. Bhalekar S, Basu S, Sangwan VS. Successful management of immunological rejection following allogeneic simple limbal epithelial transplantation (SLET) for bilateral ocular burns. *BMJ Case Rep.* 2013;2013.
48. Bhalekar S, Basu S, Lal I, et al. Successful autologous simple limbal epithelial transplantation (SLET) in previously failed paediatric limbal transplantation for ocular surface burns. *BMJ Case Rep.* 2013;2013.
49. Bhalekar S, Sangwan VS, Basu S. Growth of corneal epithelial cells over in situ therapeutic contact lens after simple limbal epithelial transplantation (SLET). *BMJ Case Rep.* 2013;2013.
50. Prabhasawat P, Luangaram A, Ekpo P, et al. Epithelial analysis of simple limbal epithelial transplantation in limbal stem cell deficiency by in vivo confocal microscopy and impression cytology. *Cell Tissue Bank.* 2019;20:95–108.
51. Narang P, Mittal V, Menon V, et al. Primary limbal stem cell transplantation in the surgical management of extensive ocular surface squamous neoplasia involving the limbus. *Indian J Ophthalmol.* 2018;66:1569–1573.
52. Mittal V, Jain R, Mittal R, et al. Successful management of severe unilateral chemical burns in children using simple limbal epithelial transplantation (SLET). *Br J Ophthalmol.* 2016;100:1102–1108.
53. Sangwan VS, Matalia HP, Vemuganti GK, et al. Amniotic membrane transplantation for reconstruction of corneal epithelial surface in cases of partial limbal stem cell deficiency. *Indian J Ophthalmol.* 2004;52:281–285.
54. Westekemper H, Figueiredo FC, Siah WF, et al. Clinical outcomes of amniotic membrane transplantation in the management of acute ocular chemical injury. *Br J Ophthalmol.* 2017;101:103–107.
55. Mednick Z, Boutin T, Einan-Lifshitz A, et al. Simple limbal epithelial transplantation for recurrent pterygium: A case series. *Am J Ophthalmol Case Rep.* 2018;12:5–8.
56. Hirst LW. Recurrence and complications after 1,000 surgeries using pterygium extended removal followed by extended conjunctival transplant. *Ophthalmology.* 2012;119:2205–2210.
57. Kheirkhah A, Casas V, Raju VK, et al. Sutureless amniotic membrane transplantation for partial limbal stem cell deficiency. *Am J Ophthalmol.* 2008;145:787–794.
58. Yeung AM, Faraj LA, McIntosh OD, et al. Fibrin glue inhibits migration of ocular surface epithelial cells. *Eye.* 2016;30:1389–1394.
59. Dietrich-Ntoukas T, Hofmann-Rummelt C, Kruse FE, et al. Comparative analysis of the basement membrane composition of the human limbus epithelium and amniotic membrane epithelium. *Cornea.* 2012;31:564–569.
60. Sangwan VS, Basu S, Vemuganti GK, et al. Clinical outcomes of xenofree autologous cultivated limbal epithelial transplantation: a 10-year study. *Br J Ophthalmol.* 2011;95:1525–1529.
61. Sejpal K, Ali MH, Maddileti S, et al. Cultivated limbal epithelial transplantation in children with ocular surface burns. *JAMA Ophthalmol.* 2013;131:731–736.
62. Dogru M, Tsubota K. Current concepts in ocular surface reconstruction. *Semin Ophthalmol.* 2005;20:75–93.
63. Ganger A, Vanathi M, Mohanty S, et al. Long-term outcomes of cultivated limbal epithelial transplantation: evaluation and comparison of results in children and adults. *Biomed Res Int.* 2015;2015: 6 pages.
64. Basu S, Mohamed A, Chaurasia S, et al. Clinical outcomes of penetrating keratoplasty after autologous cultivated limbal epithelial transplantation for ocular surface burns. *Am J Ophthalmol.* 2011;152:917–924.e911.
65. Utheim TP, Aass Utheim O, Salvanos P, et al. Concise review: altered versus unaltered amniotic membrane as a substrate for limbal epithelial cells. *STEM CELLS TRANSLATIONAL MEDICINE.* 2018;7:415–427.
66. Nishida K, Yamato M, Hayashida Y, et al. Corneal reconstruction with tissue-engineered cell sheets composed of autologous oral mucosal epithelium. *N Engl J Med.* 2004;351:1187–1196.
67. Rama P, Matuska S, Paganoni G, et al. Limbal stem-cell therapy and long-term corneal regeneration. *N Engl J Med.* 2010;363:147–155.

SUPPORTING INFORMATION

Additional supporting information may be found online in the Supporting Information section.

How to cite this article: Jackson CJ, Myklebust Ernø IT, Ringstad H, Tønseth KA, Dartt DA, Utheim TP. Simple limbal epithelial transplantation: Current status and future perspectives. *STEM CELLS Transl Med.* 2020;9:316–327. <https://doi.org/10.1002/sctm.19-0203>