

Name: _____ # Examiner: _____ Day Month Year
 Oral mucosa: Location: _____ 9= not recorded.
 0=none; 1= leukoplakia; 2= lichen planus; 3= ulceration; 4= NUG; 5=abscess; 6=granuloma; 7= other

DMFS (sound; 1=decayed; 2=filled with decay; 3=filled no decay; 4=missing caries; 5=missing due to perio; 6=missing other reason)

17	16	15	14	13	12	11	22	23	24	25	26	27
D	B	M	D	B	M	D	B	M	D	B	M	D
47	46	45	44	43	42	41	32	33	34	35	36	37
D	B	M	D	B	M	D	B	M	D	B	M	D

Calculus

17	16	15	14	13	12	11	22	23	24	25	26	27
D	B	M	D	B	M	D	B	M	D	B	M	D
47	46	45	44	43	42	41	32	33	34	35	36	37
D	B	M	D	B	M	D	B	M	D	B	M	D
D	L	M	D	L	M	D	L	M	D	L	M	D

Plaque index

17	16	15	14	13	12	11	22	23	24	25	26	27
D	B	M	D	B	M	D	B	M	D	B	M	D
47	46	45	44	43	42	41	32	33	34	35	36	37
D	B	M	D	B	M	D	B	M	D	B	M	D
D	L	M	D	L	M	D	L	M	D	L	M	D

Recession

17	16											
D	B	M	D	B	M	D	B	M	D	B	M	D
47	46											
D	B	M	D	B	M	D	B	M	D	B	M	D
D	L	M	D	L	M	D	L	M	D	L	M	D

Probing depth

17	16											
D	B	M	D	B	M	D	B	M	D	B	M	D
47	46											
D	B	M	D	B	M	D	B	M	D	B	M	D
D	L	M	D	L	M	D	L	M	D	L	M	D

Bleeding on probing

17	16											
D	B	M	D	B	M	D	B	M	D	B	M	D
47	46											
D	B	M	D	B	M	D	B	M	D	B	M	D
D	L	M	D	L	M	D	L	M	D	L	M	D

Periodontal attachment loss

17	16											
D	B	M	D	B	M	D	B	M	D	B	M	D
47	46											
D	B	M	D	B	M	D	B	M	D	B	M	D
D	L	M	D	L	M	D	L	M	D	L	M	D

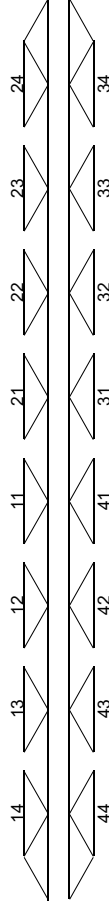
26	27				
M	B	D	M	B	D
36	37				
M	B	D	M	B	D
M	L	D	M	L	D

26	27				
M	B	D	M	B	D
36	37				
M	B	D	M	B	D
M	L	D	M	L	D

26	27				
M	B	D	M	B	D
36	37				
M	B	D	M	B	D
M	L	D	M	L	D

26	27				
M	B	D	M	B	D
36	37				
M	B	D	M	B	D
M	L	D	M	L	D

Gingival enlargement



Diagnosis