

BRIEF REPORT

Unsubstantiated belief in the diagnostic accuracy of the triad of abusive head trauma may lead to incorrect diagnoses of alleged abuse cases

Benign external hydrocephalus (BEH) is a subtype of hydrocephalus. It is common in boys and characterised by rapid increases in head circumference (HC), enlarged subarachnoid spaces and normal or moderately enlarged ventricles.^{1,2} Most infants with BEH are born with a normal HC that starts to grow too rapidly after birth.^{3,4} BEH predisposes infants for increased intracranial pressure, subdural haematoma (SDH), retinal haemorrhages and epileptic seizures.⁵

BEH and abusive head trauma (AHT) peak during the first six months after birth and have similar age and sex distributions. Some infants diagnosed with AHT due to violent shaking might actually have BEH.⁵ This paper reports premature male monozygotic twins with typical BEH findings, who were misdiagnosed with AHT. Swedish law does not require ethical approval for case studies.

The twins were delivered vaginally at 36 weeks and 5 days with normal HCs of 34 cm and 35 cm.

Soon after birth, both boys showed rapid increases in HC. Twin 1 increased from 34 cm to three standard deviations at the uncorrected age of two months (Figure 1A). Family photographs revealed that twin 1 exhibited sunset gaze at four weeks and two months, but twin 2 did not. This means that twin 1 displayed clinical signs of increased intracranial pressure one month before suspected AHT.

Because of his rapidly increasing HC, twin 1 was referred to a paediatric hospital two months and one week after birth. On admission, he was irritable, drowsy and anaemic, with a moderately low albumin concentration and a bulging, tense fontanelle. He started crying as soon as he was laid down on his back.

A computed tomography scan 11 hours after admission showed radiological characteristics typical of BEH: bilateral chronic SDH (Figure 1B), slightly dilated ventricles, normal cortical convolutions and increased interhemispheric distance. A whole-body X-ray revealed no fractures.

Shortly after the initial scan, he was rushed to intensive care, due to epileptic seizures that started in his right side and rapidly became generalised. These signs of encephalopathy developed after he had been hospitalised and under surveillance for several hours. Hospital staff personnel witnessed the symptom debut and the lack of preceding shaking or abuse. His epilepsy proved therapy resistant, and he was intubated, sedated and on assisted ventilation for nearly two

weeks. Repeated electroencephalographic recordings revealed seizure activity compatible with status epilepticus.

Ophthalmoscopy revealed widespread, bilateral retinal haemorrhages 15 hours after the first seizures. He had all the findings of the triad without signs of external trauma: SDH, retinal haemorrhages and encephalopathy. The paediatric ophthalmologist immediately stated that AHT needed to be excluded, and 30 minutes later, the phrase suspected non-accidental cause appeared on his medical records, based purely on the presence of the triad. As these findings were regarded as highly probable for shaken baby syndrome and AHT, social services and the police were notified the same day. The parents were arrested, interrogated by the police, detained in custody and restricted to meeting with their children for several months.

Two days after admission, a magnetic resonance imaging (MRI) scan confirmed chronic SDH and showed radiological characteristics of BEH (Figure 1C), which, however, were not noticed or described. Ischaemic lesions were confirmed in both hemispheres and the pattern suggested a hypoxic, ischaemic pathogenesis (Figure 1D).

The case was discussed by a multidisciplinary team on day three, including a paediatric intensivist, a paediatric acute medicine specialist, paediatric neurologists, neurosurgeons, a neuroradiologist, a neuro-ophthalmologist, a child protection team physician and forensic pathologists. They suspected a non-accidental injury, as extensive examinations had not revealed any underlying medical explanation for his condition, and a formal AHT diagnosis was recorded six weeks later.

After assisted ventilation ceased, he woke up with clinical and radiological signs of permanent hypoxic ischaemia.

Twin 2 also had a rapidly increasing HC and macrocephaly at two months of age (Figure 1A). An MRI scan revealed radiological characteristics of BEH, complicated by chronic SDH that was a few millimetres thick. He never exhibited any other symptoms of raised intracranial pressure and lacked external signs of trauma, but the multidisciplinary team decided he had been violently shaken.

Twin 1 had the epidemiological, clinical and radiological findings typical of BEH complicated by increased intracranial pressure, SDH and retinal haemorrhages. He was male, premature, a twin and had a

Abbreviations: AHT, abusive head trauma; BEH, benign external hydrocephalus; HC, head circumference; SDH, subdural haematoma.

This is an open access article under the terms of the Creative Commons Attribution-NonCommercial-NoDerivs License, which permits use and distribution in any medium, provided the original work is properly cited, the use is non-commercial and no modifications or adaptations are made.

© 2021 The Authors. *Acta Paediatrica* published by John Wiley & Sons Ltd on behalf of Foundation Acta Paediatrica.

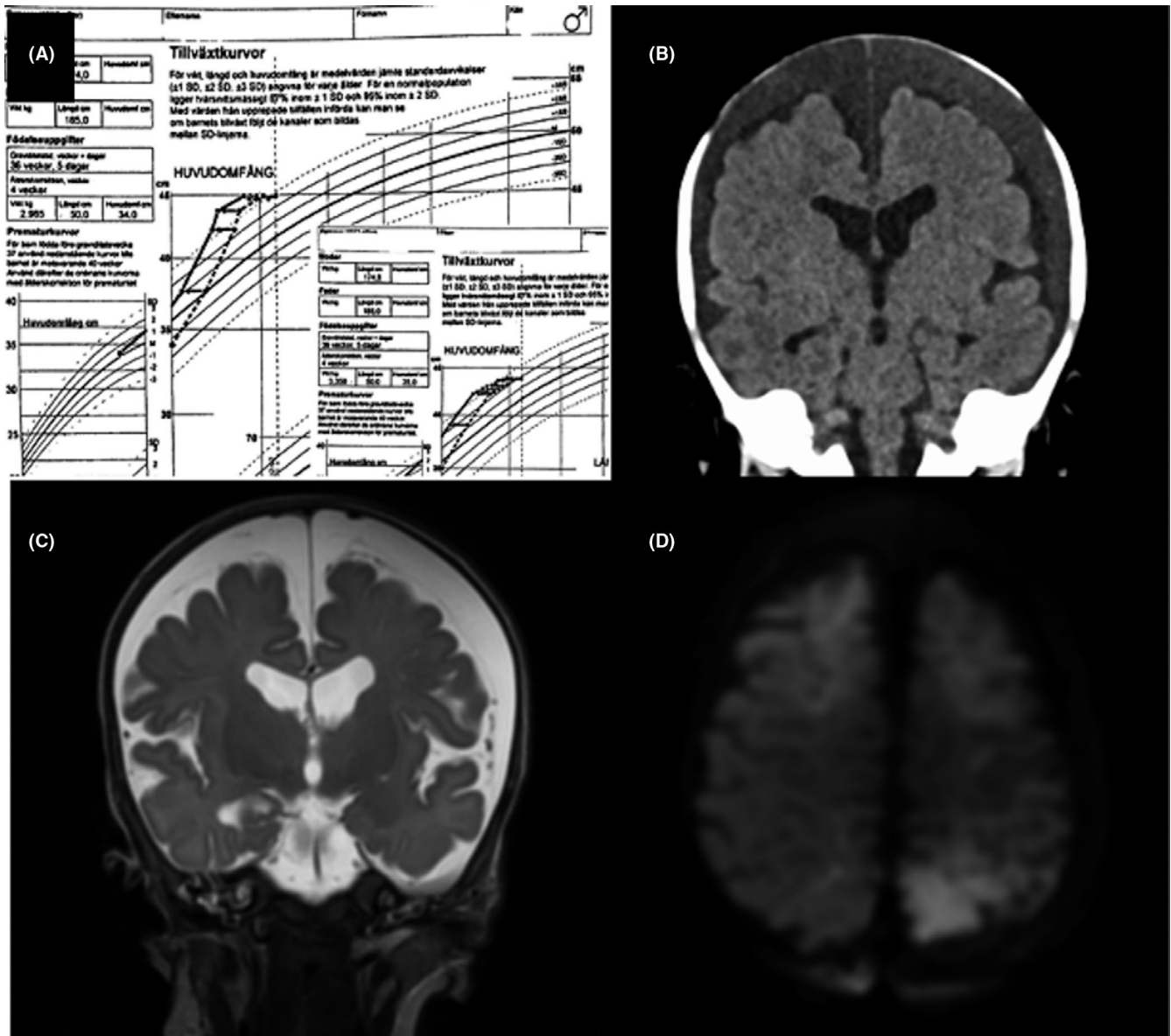


FIGURE 1 (A) Twin 1 and 2. Head circumference (HC) charts for both twins. Left, larger chart: twin 1. Lower right—inserted smaller chart: twin 2. Stippled lines: HC development since birth. Solid lines: HC adjusted for age. First thin vertical line indicates three months of age. (B) Twin 1. Coronal computed tomography scan obtained shortly after admission, with bilateral low-attenuating subdural fluid compatible with chronic subdural haematoma (chronic SDH), but a preserved subarachnoid space and non-compressed cortex. The interhemispheric width is larger than normal. (C–D) Images from MR examination two days after admission. Coronal T2 weighted image (C), clearly shows wide subarachnoid spaces despite the overlying chronic SDH, compatible with benign external hydrocephalus. Diffusion-weighted image (D) shows left-sided parietal and bilateral superior frontal hypoxic/ischaemic lesions

rapidly growing HC and chronic SDH that did not flatten the cortical surface. He also had visible layer of cerebrospinal fluid between the brain and the chronic SDH, with moderately enlarged lateral ventricles and markedly increased craniocortical width, sinocortical width and interhemispheric distance.^{2,3} Despite these typical features of BEH, hydrocephalus was never mentioned in the hospital records, even though staff were aware of the rapid increase in HC. The diagnosis at discharge was AHT, based solely on the triad.

We question the clinical management of such cases, including automatically alerting social services and the police when triad

findings are detected. These decisions have negative effects on families and incorrect AHT diagnoses may delay, or even hamper, BEH treatment. It is important that case histories are carefully assessed, and open-ended investigations of obvious and plausible diagnoses are evaluated to ensure adequate treatment is started.

CONFLICTS OF INTEREST

KW, JW and AE have served as mostly unpaid expert witnesses on AHT in court proceedings. AE and NL were co-authors of the SBU report (www.sbu.se).

Knut Wester¹ 
Johan Wikström² 
Niels Lynøe³ 
Anders Eriksson⁴ 

¹Department of Clinical Medicine, University of Bergen, Bergen,
Norway

²Department of Surgical Sciences, Radiology, Uppsala
University, Uppsala, Sweden

³Centre for Healthcare Ethics, Karolinska Institutet, Stockholm,
Sweden

⁴Department of Community Medicine and Rehabilitation,
Forensic Medicine, Umeå University, Umeå, Sweden

Correspondence

Knut Wester, Department of Clinical Medicine, University of
Bergen, Svingen 42, NO-0196 Oslo, Norway.
Email: knut.wester@gmail.com

ORCID

Knut Wester  <https://orcid.org/0000-0001-8489-3931>

Johan Wikström  <https://orcid.org/0000-0002-9481-6857>

Niels Lynøe  <https://orcid.org/0000-0002-2978-3331>

Anders Eriksson  <https://orcid.org/0000-0001-7026-5061>

REFERENCES

1. Alvarez LA, Maytal J, Shinnar S. Idiopathic external hydrocephalus: natural history and relationship to benign familial macrocephaly. *Pediatrics*. 1986;77(6):901-907.
2. Zahl SM, Egge A, Helseth E, Wester K. Benign external hydrocephalus: a review, with emphasis on management. *Neurosurg Rev*. 2011;34(4):417-432.
3. Wiig US, Zahl SM, Egge A, Helseth E, Wester K. Epidemiology of benign external hydrocephalus in Norway - A population-based study. *Pediatr Neurol*. 2017;73:36-41.
4. Zahl SM, Egge A, Helseth E, Wester K. Clinical, radiological, and demographic details of benign external hydrocephalus: A population-based study. *Pediatr Neurol*. 2019;96:53-57.
5. Wester K. Two infant boys misdiagnosed as "Shaken Baby" and their twin sisters: A cautionary tale. *Pediatr Neurol*. 2019;97:3-11.