

Single Case

A Rare Case of Unilateral Renal Cortical Necrosis

Yngvar Lunde Haaskjold^a Kim Nylund^{b, c} Rannveig Skrunes^{a, b}

^aDepartment of Medicine, Haukeland University Hospital, Bergen, Norway; ^bDepartment of Clinical Medicine, University of Bergen, Bergen, Norway; ^cNational Centre for Ultrasound in Gastroenterology, Haukeland University Hospital, Bergen, Norway

Keywords

Acute kidney injury · Antiphospholipid syndrome · Contrast-enhanced ultrasound · Renal ischemia · Unilateral cortical necrosis

Abstract

Unilateral cortical necrosis is a rare condition, and only described in a few case reports. We present a case of a previously healthy 24-year-old male with acute unilateral cortical necrosis, where contrast-enhanced ultrasound (CEUS) became a valuable diagnostic tool. Antiphospholipid syndrome was subsequently diagnosed. Primary antiphospholipid syndrome is a well-known, but rare cause of cortical necrosis. It promotes thrombosis in renal arteries, capillaries and veins, and usually affects both kidneys. Unilateral cortical necrosis due to antiphospholipid syndrome has, to our knowledge, not been previously described.

© 2021 The Author(s)
Published by S. Karger AG, Basel

Background

Cortical necrosis is a condition with acute, ischaemic damage to the renal cortex. It is in most cases bilateral, caused by severe bleeding or septic shock [1, 2]. Unilateral cortical necrosis is rare, and only described in a few case reports. Most case reports describe septic shock or disseminated intravascular coagulation (DIC) and contralateral hydronephrosis [3] as the

underlying aetiology. We present a case report describing acute unilateral cortical necrosis in a previously healthy 24-year-old male, who initially presented to the surgical department with acute abdominal pain.

Case Presentation

The patient was admitted to hospital with acute right lower quadrant abdominal pain and tenderness over McBurney's point. He was afebrile with blood pressure of 136/84 mm Hg, regular pulse 50/min and a respiratory rate of 16/min. Urine dipstick: protein +1, blood 0, leukocytes 0, ketones +1 and glucose 0. Blood samples: C-reactive protein (CRP) <5 mg/L (ref. <5) and serum creatinine 98 $\mu\text{mol/L}$ (ref. 85–105 $\mu\text{mol/L}$). Based on symptoms and clinical examination, appendicitis was suspected, and the patient underwent a laparoscopic appendectomy. The appendix did not show any signs of inflammation, and he was discharged from hospital the following day.

He was readmitted to hospital the day after discharge, with diffuse abdominal pain and fever of 38.1°C, blood pressure of 148/77 mm Hg, pulse 90/min, respiratory rate of 22/min. CRP was 137 mg/L, leukocytes $16.4 \times 10^9/\text{L}$ (ref. 3.5–11.0) and serum creatinine was 123 $\mu\text{mol/L}$. Urine dip-stick: protein +3, blood +3, leukocytes 0, ketones +2, glucose 0. An abdominal contrast-enhanced computer tomography scan (CT) indicated possible renal infarction or severe pyelonephritis in the right kidney (Fig. 1). Based on the radiological findings, he was anticoagulated with low molecular weight heparin (LMWH) and antibiotic therapy with piperacillin/tazobactam was initiated. Urine culture from the day of the CT examination was negative, as were blood cultures. The patient was subsequently transferred to a university hospital for further diagnostic assessment.

Initially, lupus anticoagulant was marginally increased at 1.28 (ref. <1.28). Interference with LMWH was suspected. Lupus coagulant was repeated several times over a 12-month period, with values ranging from 1.22 to 1.45. Platelet count, activated partial thromboplastin time, anti-beta2-glycoprotein 1 IgG and IgM, anti-cardiolipin IgG and IgM, protein C, protein S and prothrombin III were all within the normal range, as were anti-neutrophil cytoplasmic antibody (ANCA), antinuclear antibody (ANA) and anti-glomerular basement membrane antibody (anti-GMB), C3 and C4. Lactate dehydrogenase was elevated, at 1,716 U/L (ref. 105–205). Echocardiography and 24 h Holter monitoring were normal.

Ultrasound of the kidney with contrast-enhanced ultrasound (CEUS) 10 days after the initial CT examination showed the renal cortex in the lower part of the kidney to be hypoechoic, as compared to the upper pole. Vessel density by colour Doppler was also clearly reduced. To investigate perfusion, 1.2 mL of Sonovue (Bracco, Milan, Italy) was injected as a bolus in the left cubital vein. In the cortical phase, parts of the cortex did not enhance with contrast, a sector in the upper pole of the kidney was however still perfused. In comparison, there were no perfusion defects in the left kidney. These findings were consistent with unilateral cortical necrosis (Fig. 2).

The patient was anticoagulated with LMWH for 3 months, followed by a repeated examination with CEUS. Atrophy of the right kidney from 10.5 to 7.6 cm was seen. After contrast injection, a cortical area with preserved circulation still remained in the upper pole of the right kidney. S-creatinine was 97 $\mu\text{mol/L}$. The combination of elevated levels of lupus anticoagulant and a vascular event in the right kidney prompted the diagnosis of antiphospholipid syndrome, and long-term anticoagulation with warfarin was initiated.

Discussion

We report the case of a 24-year-old man with unilateral cortical necrosis, who initially presented to the surgical department with suspected appendicitis. A diagnosis of acute unilateral cortical necrosis was subsequently made by CEUS. Cortical necrosis is a rare cause of acute kidney injury in developed countries, it is most often bilateral, and more commonly reported as an obstetric complication [4, 5]. In both obstetric and non-obstetric patients, the aetiology is often severe hypovolaemia due to bleeding or septic shock, with or without DIC [1, 2]. Unilateral cortical necrosis has also been described after trauma [6]. The diagnosis relies on contrast-enhanced CT, or indeed a kidney biopsy as described by Chugh et al. and Prakash et al. [1, 2, 7]. On presentation, our patient had no history of trauma, hypovolaemia or immediately preceding infection. An abdominal CT examination suggested pyelonephritis or renal infarction as differential diagnoses; however, CEUS performed a few days later was able to show discrete contrast sparing of the right renal cortex, suggesting cortical necrosis. CEUS is a new non-invasive method for diagnosing cortical necrosis, avoiding ionizing radiation and the inherent risks of a kidney biopsy. CEUS is relatively inexpensive, and can be used to make a bedside diagnosis. According to the European Federation of Societies for Ultrasound in Medicine and Biology guidelines, the spatial resolution of CEUS is suited to differentiating renal infarctions from cortical necrosis, as cortical necrosis appears as a non-enhancing area with preserved hilar vascularity [8].

The cause of unilateral cortical necrosis in this young man may be antiphospholipid syndrome. Lupus anticoagulant was measured several times over a 12-month period, with values ranging from normal to mildly elevated. He was anticoagulated with LMWH for the first 3 months after diagnosis, and the varying results were initially attributed to analysis interference with heparin. Primary antiphospholipid syndrome affects the kidneys in a minority of patients; however, it can affect renal vessels of all sizes [9]. Our patient fulfils the diagnostic criteria: laboratory finding with detection of lupus anticoagulant in plasma combined with small vessel thrombosis [10]. It is extraordinary to have thrombosis in several of arteries supplying the right renal cortex, but we have not found any other plausible cause of unilateral cortical necrosis in this patient. Bilateral cortical necrosis is associated with a high risk of chronic kidney disease and end-stage renal disease [1, 2]. Our patient has lost most of the function in his right kidney; however, eGFR remains intact with 94 mL/min/1.73 m² without proteinuria, and he is normotensive. The recovery of renal function is probably due to compensatory hyperfiltration of the right kidney. He will receive regular follow-up with respect to kidney function, development of hypertension and proteinuria at his local hospital, in addition to long-term anticoagulation with warfarin.

Statement of Ethics

Written informed consent from the patient has been obtained for publication including images. The research was conducted ethically in accordance with the World Medical Association Declaration of Helsinki.

Conflict of Interest Statement

The authors have no conflicts of interest to declare.

Funding Sources

No particular funding was obtained for this case report.

Author Contributions

Yngvar Lunde Haaskjold was responsible for the clinical investigation and contributed to the preparation of the manuscript. Rannveig Skrunes was responsible for the clinical investigation and contributed to the preparation of the manuscript. Kim Nylund performed the ultrasonographic examination and prepared the images. He also contributed to the preparation of the manuscript.

References

- 1 Chugh KS, Jha V, Sakhuja V, Joshi K. Acute renal cortical necrosis—a study of 113 patients. *Ren Fail*. 1994;16(1):37–47.
- 2 Prakash J, Vohra R, Wani IA, Murthy AS, Srivastva PK, Tripathi K, et al. Decreasing incidence of renal cortical necrosis in patients with acute renal failure in developing countries: a single-centre experience of 22 years from Eastern India. *Nephrol Dial Transplant*. 2007 Apr;22(4):1213–7.
- 3 Quin R, Moliere S, Rust E, Ohana M, Roy C. Unilateral renal cortical necrosis: report of a case. *Diagn Interv Imaging*. 2013 Apr;94(4):463–5.
- 4 Fakhouri F, Vercel C, Frémeaux-Bacchi V. Obstetric nephrology: AKI and thrombotic microangiopathies in pregnancy. *Clin J Am Soc Nephrol*. 2012 Dec;7(12):2100–6.
- 5 Frimat M, Decambon M, Lebas C, Moktefi A, Lemaitre L, Gnemmi V, et al. Renal cortical necrosis in postpartum hemorrhage: a case series. *Am J Kidney Dis*. 2016 Jul;68(1):50–7.
- 6 Yusuf GT, Sellars ME, Huang DY, Deganello A, Sidhu PS. Cortical necrosis secondary to trauma in a child: contrast-enhanced ultrasound comparable to magnetic resonance imaging. *Pediatr Radiol*. 2014 Apr;44(4):484–7.
- 7 Fogo AB, Lusco MA, Najafian B, Alpers CE. AJKD Atlas of Renal Pathology: cortical Necrosis. *Am J Kidney Dis*. 2016 May;67(5):e27–8.
- 8 Sidhu PS, Cantisani V, Dietrich CF, Gilja OH, Saftoiu A, Bartels E, et al. The EFSUMB guidelines and recommendations for the clinical practice of contrast-enhanced ultrasound (CEUS) in non-hepatic applications: update 2017 (long version). *Ultraschall Med*. 2018 Apr;39(2):e2–44.
- 9 Nzerue CM, Hewan-Lowe K, Pierangeli S, Harris EN. “Black swan in the kidney”: renal involvement in the antiphospholipid antibody syndrome. *Kidney Int*. 2002 Sep;62(3):733–44.
- 10 Keeling D, Mackie I, Moore GW, Greer IA, Greaves M; British Committee for Standards in Haematology. Guidelines on the investigation and management of antiphospholipid syndrome. *Br J Haematol*. 2012 Apr;157(1):47–58.

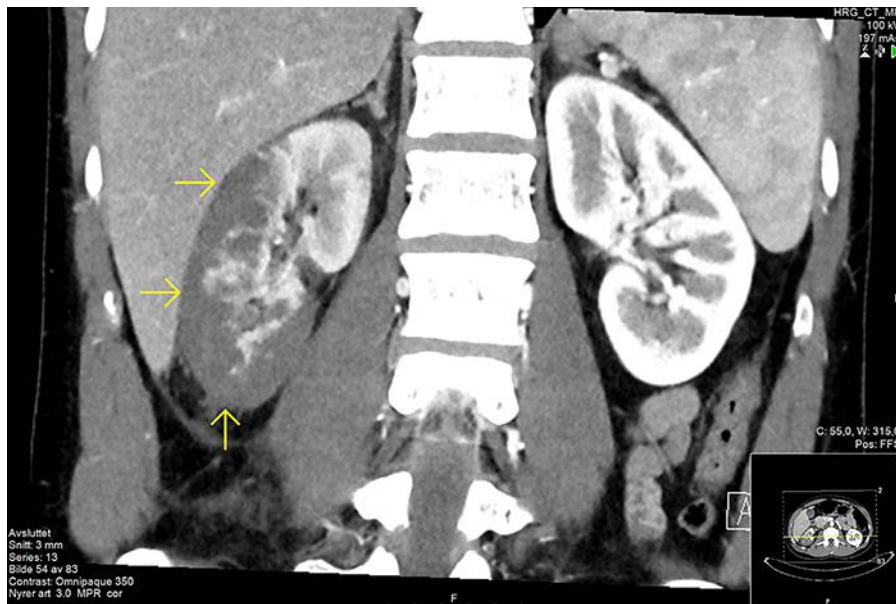

Fig. 1. Lack of contrast enhancement in the peripheral parts of the right kidney and fat stranding in the surrounding tissue could be consistent with severe pyelonephritis or renal infarction.

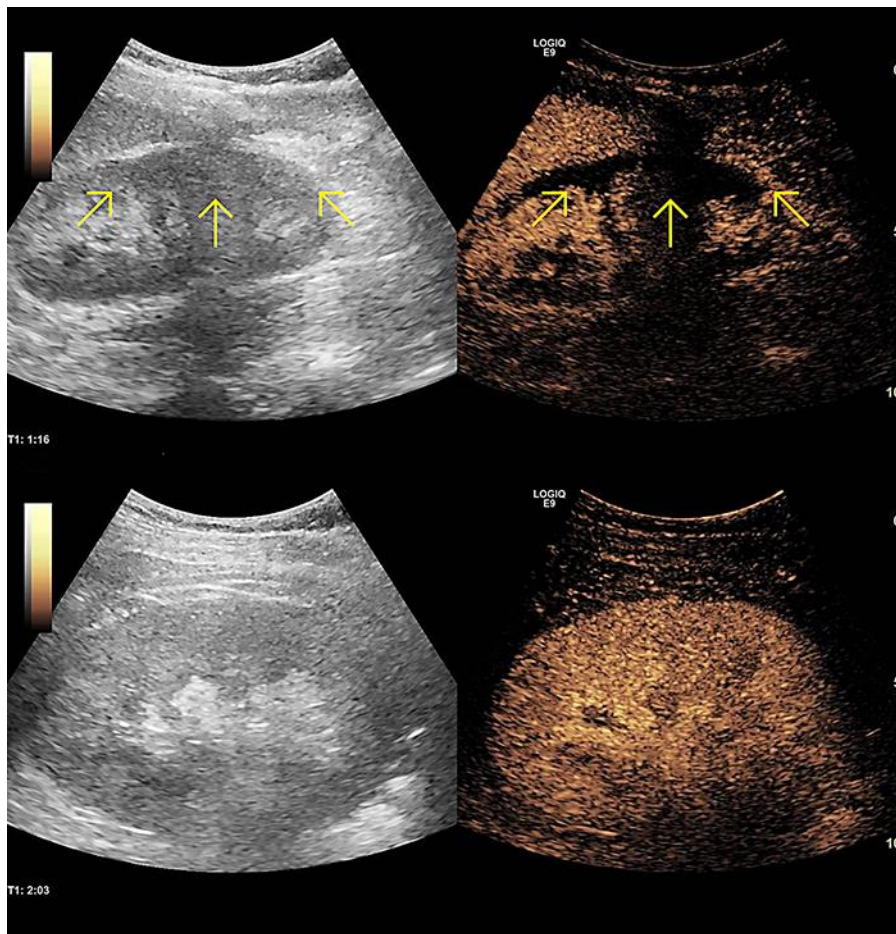


Fig. 2. B-mode and contrast image of the right kidney (upper images) compared to the left kidney (lower images). Both images were obtained in the medullary phase at 76 and 123 s, respectively. The black segments in the cortex of the right kidney represent areas with no circulation.