

Global Coronary Artery Plaque Area is Associated with Myocardial Hypoperfusion in Women with Non-ST Elevation Myocardial Infarction

Ingeborg Eskerud, Eva Gerdt, MD, PhD, Jan Erik Nordrehaug, MD, PhD,
and Mai Tone Lønnebakken, MD, PhD

Abstract

Background: Women with non-ST elevation myocardial infarction (NSTEMI) have similar extent of myocardial ischemia but less obstructive coronary artery disease (CAD) than their male counterparts. We tested the impact of global coronary artery plaque area and artery tortuosity on myocardial perfusion in NSTEMI patients. **Methods:** Coronary artery plaque area was determined by quantitative angiography in 108 patients (32% women) with NSTEMI. Myocardial perfusion was assessed by contrast echocardiography in the 17 individual left ventricular segments. Artery tortuosity was defined as ≥ 3 curves $>45^\circ$ in a main coronary artery. **Results:** Age, prevalence of hypertension, and diabetes did not differ between sexes (all nonsignificant). Women had lower prevalence of $\geq 50\%$ coronary artery stenosis (74% vs. 91%, $p < 0.05$), while global coronary plaque area (35 ± 22 vs. $43 \pm 21 \text{ mm}^2$) and the number of segments with hypoperfusion (6.9 ± 3.7 vs. 7.2 ± 3.4) did not differ between sexes (both $p > 0.07$). In multivariate analysis, larger coronary artery plaque area was associated with a 35% higher risk for having severe myocardial hypoperfusion (odds ratio 1.35 [95% confidence interval 1.01–1.80], $p < 0.05$) in the total study population, while no association between artery tortuosity and myocardial ischemia was found. Similar results were obtained in separate analysis among women and men. **Conclusion:** In women and men with NSTEMI, the global coronary artery plaque area was an important determinant of the severity of myocardial hypoperfusion at rest independent of presence of significant coronary stenoses. These findings may expand current understanding of NSTEMI in patients with nonobstructive CAD.

Introduction

SEX DIFFERENCES in coronary artery disease (CAD) pathophysiology have previously been demonstrated both in autopsy-based and clinical studies,^{1–3} including differences in coronary artery plaque composition and distribution as well as coronary artery tortuosity.^{4–9} In particular, non-obstructive CAD on angiography is found more often in women compared to men, irrespective of clinical presentation of the coronary artery disease.⁵

Previous studies using contrast echocardiography or cardiac magnetic resonance imaging have demonstrated that ischemic burden measured by these techniques is an important prognosticator in particular in women with nonobstructive

CAD.^{10,11} In a smaller study, we recently demonstrated that the extent of myocardial hypoperfusion in patients with non-ST elevation myocardial infarction (NSTEMI) was comparable in women and men despite less obstructive CAD in women.⁷ However, it is not clear whether coronary artery plaque area may influence myocardial perfusion in NSTEMI patients independent of presence of significant coronary artery stenoses. Furthermore, others have suggested that also artery tortuosity may influence coronary perfusion.⁹ The aim of this study was therefore to explore if coronary plaque area and arterial tortuosity impacted myocardial perfusion in NSTEMI patients, and thereby could explain the mismatch between extent of myocardial hypoperfusion and presence of significant CAD previously reported in NSTEMI women.

Department of Clinical Science, University of Bergen, Bergen, Norway.
Clinical Trial Registration: www.clinicaltrials.gov NCT01122069.

© Ingeborg Eskerud, et al. 2015; Published by Mary Ann Liebert, Inc. This Open Access article is distributed under the terms of the Creative Commons Attribution Noncommercial License (<http://creativecommons.org/licenses/by-nc/4.0/>) which permits any noncommercial use, distribution, and reproduction in any medium, provided the original author(s) and the source are credited.

Materials and Methods

Study population

A total of 126 consecutive patients diagnosed with acute NSTEMI, defined as the combination of chest pain and troponin T elevation, hospitalized at the Department of Heart Disease, Haukeland University Hospital, from March through December 2008 and scheduled for acute coronary angiography within 72 hours after admittance were eligible for the study. Excluding patients with hemodynamically unstable disease, mechanical valve prostheses or severe pulmonary disease, a total of 110 patients signed informed consent and all of them underwent myocardial contrast echocardiography prior to scheduled coronary angiography.¹²

For the present post-hoc analysis, reanalyzing the angiograms in this previous series with quantitative coronary angiography, two of the 110 patients were excluded because all native coronary arteries were occluded, leaving 108 patients for the present study population. Clinical risk assessment was performed in all patients using the thrombolysis in myocardial infarction (TIMI) risk score model.¹³ The study was approved by the regional ethical committee and performed in accordance with the Helsinki declaration.

Quantitative coronary angiography

Quantitative coronary angiography was performed offline by a single reader (IE) blinded to clinical data and myocardial perfusion assessment using a digitalized automatic edge detecting analysis software (QAngio® XA 7.1, MEDIS Medical Imaging Systems, Leiden, The Netherlands) (Fig. 1, panel A).

The coronary artery tree was divided into 17 segments, following the modified American Heart Association model.¹⁴ The tip of the catheter was used for calibration. Stenosis severity and plaque area assessed as lumen diameter reduction was determined in all vessel segments with a diameter > 1.5 mm. Global coronary artery plaque area was calculated as the sum of plaque area in all segments. A coronary artery lumen diameter reduction of $\geq 50\%$ on the angiogram was considered a significant stenosis.

Coronary artery tortuosity was measured in the three main coronary arteries in standardized views: The left anterior descending artery in the right anterior oblique view with cranial angulation, the left circumflex artery in the left anterior oblique with caudal angulation and the right coronary artery in the right anterior oblique view.⁹ Coronary tortuosity

was regarded present if ≥ 3 curves $>45^\circ$ was found in the same artery (Fig. 1, panel B).

Echocardiography

Quantitative echocardiography was performed following the joint European Association of Echocardiography and American Society of Echocardiography guidelines.¹⁵ Left ventricular (LV) ejection fraction was assessed by the modified biplane Simpson formula and regional LV function by wall motion scoring.¹⁵ Wall motion score was assessed in apical 2-, 3-, and 4-chamber views using a 17-segment LV model as recommended in current quantitation guidelines.¹⁵ The average wall motion score value was taken as wall motion score index in the individual patients. Methods and results from myocardial contrast echocardiography have previously been reported in details.^{7,12} In short, myocardial contrast echocardiography was performed at rest by real-time low-mechanical index imaging and destruction–replenishment using Cadance Contrast Pulse Sequencing technology (Acuson Sequoia C512, Siemens, Mountain View, CA, echocardiograph). An intravenous bolus dosage of 0.3 mL Perflutren Lipid Microsphere ultrasound contrast (Luminity®, Lantheus Medical Imaging, North Billerica, MA) was given before perfusion imaging. The bolus dosage was repeated if necessary to ensure a stable contrast concentration and avoid contrast swirling during image acquisition. Regional myocardial perfusion was scored visually as normal (contrast replenishment within five heart beats) or hypoperfusion (delayed contrast replenishment after more than five heart beats) using the guideline-recommended 17 segment LV model (Fig. 2).^{15,16} The extent of myocardial perfusion abnormalities was assessed as the number of segments with hypoperfusion. Severe myocardial hypoperfusion was considered present if hypoperfusion was detected in ≥ 6 LV segments.¹²

Statistics

Data management and statistical analysis were performed by the IBM SPSS statistical program version 20.0 (IBM SPSS, Chicago, IL). The study had 80% power to detect a 30% difference in coronary artery stenosis between women and men at a statistical level of 0.05. Continuous variables are reported as mean and standard deviation and categorical variables as numbers and percentages. Comparisons between groups were performed by unpaired *t*-test or chi-squared

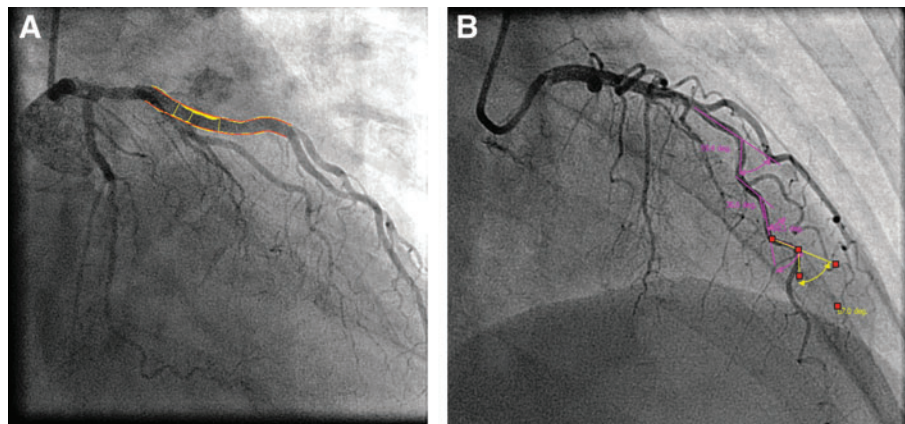


FIG. 1. Quantitative coronary angiography. Coronary artery plaque area (A) and coronary artery tortuosity (B) assessed in the left anterior descending artery.

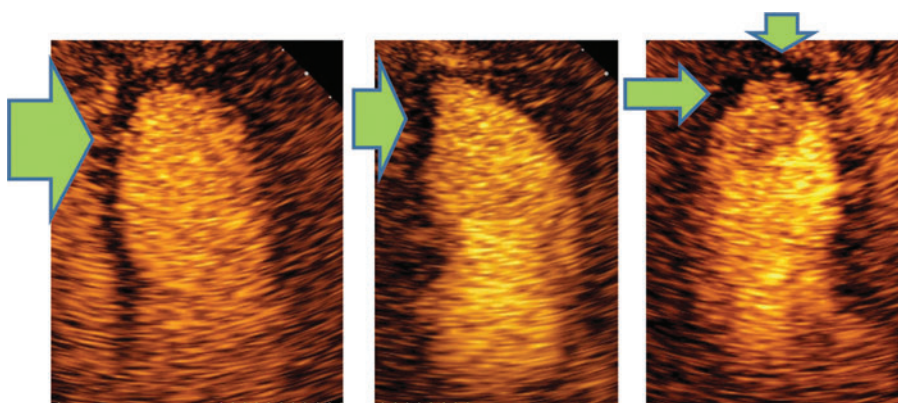


FIG. 2. Myocardial contrast echocardiography. Apical 4-chamber, 2-chamber and long axis view images taken five beats post flash demonstrating subendocardial and transmural hypoperfusion in the apical left ventricular segments marked with green arrows.

statistics as appropriate. Covariates of global coronary artery plaque area and tortuosity were identified by Pearson's correlation coefficient and logistic regression analysis as appropriate. Independent covariates of the extent of myocardial hypoperfusion were identified in multiple linear regression analysis. Covariates of severe hypoperfusion (involving ≥ 6 LV segments) were identified in multiple logistic regression analysis. The associations of presence of severe myocardial hypoperfusion with global coronary artery plaque area and presence of significant coronary artery stenosis were tested in receiver operator characteristics curve analysis. A p value < 0.05 was considered statistical significant. The intraobserver variability of myocardial perfusion assessment and of coronary artery plaque area measurement was calculated separately from echocardiographic and angiographic images, respectively, in 11 patients analyzed twice and reported as intraclass correlation coefficient.

Results

Patient characteristics

The proportion of patients > 65 years of age was significantly higher among women, while mean age, troponin T levels

and TIMI risk score did not differ between women and men (Table 1). There were no sex differences in anti-ischemic treatment at study entrance. None of the women were on hormone replacement therapy. The extent of wall motion abnormalities and myocardial hypoperfusion did not differ between women and men, reflecting comparable myocardial infarct size (Table 2). The mean time between contrast echocardiography and angiography was 1.87 ± 2.6 days, with a median of 1.0 day. There were no adverse events from contrast infusions, except for three patients who experienced transient lower back pain.

Coronary artery plaque area

A total of 35 main arteries had proximal total occlusion. From the total of 1422 coronary artery segments visible on the angiograms, 69 segments were excluded from analysis due to poor image quality and vessel overlap, and another 170 segments were excluded due to luminal diameter ≤ 1.5 mm, which cannot be analyzed with our method, leaving a total of 1252 (88% of visible segments on the angiogram) for assessment of coronary artery plaque area.

Reproducibility of myocardial perfusion score by intraclass correlation coefficient was 0.95 (95% confidence

TABLE 1. CLINICAL CHARACTERISTICS OF THE TOTAL STUDY POPULATION AND GROUPS OF WOMEN AND MEN

	Total (n=108)	Women (n=34)	Men (n=74)	p
Age (years)	67 \pm 12	70 \pm 12	66 \pm 12	0.160
Age > 65 years (%)	56.5	70.6	50.0	0.045
BMI (kg/m ²)	27 \pm 5	27 \pm 5	27 \pm 4	0.973
Systolic blood pressure (mmHg)	150 \pm 24	150 \pm 22	150 \pm 25	0.906
Diastolic blood pressure (mmHg)	85 \pm 13	85 \pm 13	85 \pm 13	0.917
TIMI risk score	3.24 \pm 1.41	3.47 \pm 1.44	3.14 \pm 1.39	0.252
Family history of premature CAD (%)	40	41	39	0.854
Hypertension (%)	44	44	43	0.932
Hypercholesterolemia (%)	49	65	42	0.028
Diabetes mellitus (%)	19	21	19	0.839
Current smoker (%)	28	15	34	0.040
Peak troponin T level (ng/L)	680 \pm 1170	530 \pm 660	750 \pm 1300	0.353
Previous myocardial infarction (%)	29	29	29	0.912
Betablocker use (%)	33	32	34	0.884
Calcium channel blockers use (%)	11	9	12	0.608
Statin use (%)	41	32	45	0.229
Acetylsalicylic acid use (%)	42	47	39	0.441

BMI, body mass index; CAD, coronary artery disease; TIMI, thrombolysis in myocardial infarction risk score.

TABLE 2. ECHOCARDIOGRAPHIC AND ANGIOGRAPHIC FINDINGS IN THE TOTAL STUDY POPULATION AND SEPARATELY IN WOMEN AND MEN

	Total (n=108)	Women (n=34)	Men (n=74)	p
LV end-diastolic diameter (cm)	5.09±0.65	4.76±0.56	5.25±0.65	<0.001
LV end-systolic diameter (cm)	3.65±0.73	3.36±0.64	3.79±0.73	0.004
Intraventricular septum thickness (cm)	1.20±0.18	1.12±0.20	1.21±0.17	0.737
Posterior wall thickness (cm)	1.02±0.13	0.99±0.12	1.03±0.13	0.140
LV ejection fraction (%)	56±12	58±12	54±11	0.165
Extent of wall motion abnormality (segments)	3.6±3.7	3.7±4.1	3.6±3.5	0.893
Extent of hypoperfusion (segments)	7.1±3.5	6.9±3.7	7.2±3.4	0.747
Severe hypoperfusion (%)	63.9	64.7	63.5	0.905
Significant stenosis (%)	85	74	91	0.021
Total coronary artery occlusion (%)	34	35	34	0.878
Wall motion score index	1.22±0.23	1.23±0.26	1.22±0.23	0.880
Multivessel disease (%)	49	35	55	0.052
Coronary artery tortuosity (%)	68	82	61	0.026
Coronary artery plaque area (mm ²)	41±22	35±22	43±21	0.071

LV, left ventricular.

interval [CI] 0.90–0.98) and for coronary artery plaque area 0.86 (95% CI 0.75–0.91).

Global coronary artery plaque area did not differ significantly between women and men despite lower prevalence of significant coronary artery stenoses and multivessel disease

in women (Table 2). In receiver operating characteristic curve analysis, global coronary artery plaque area was significantly associated with having severe myocardial hypoperfusion in both women and men, while presence of significant coronary artery stenosis was significantly

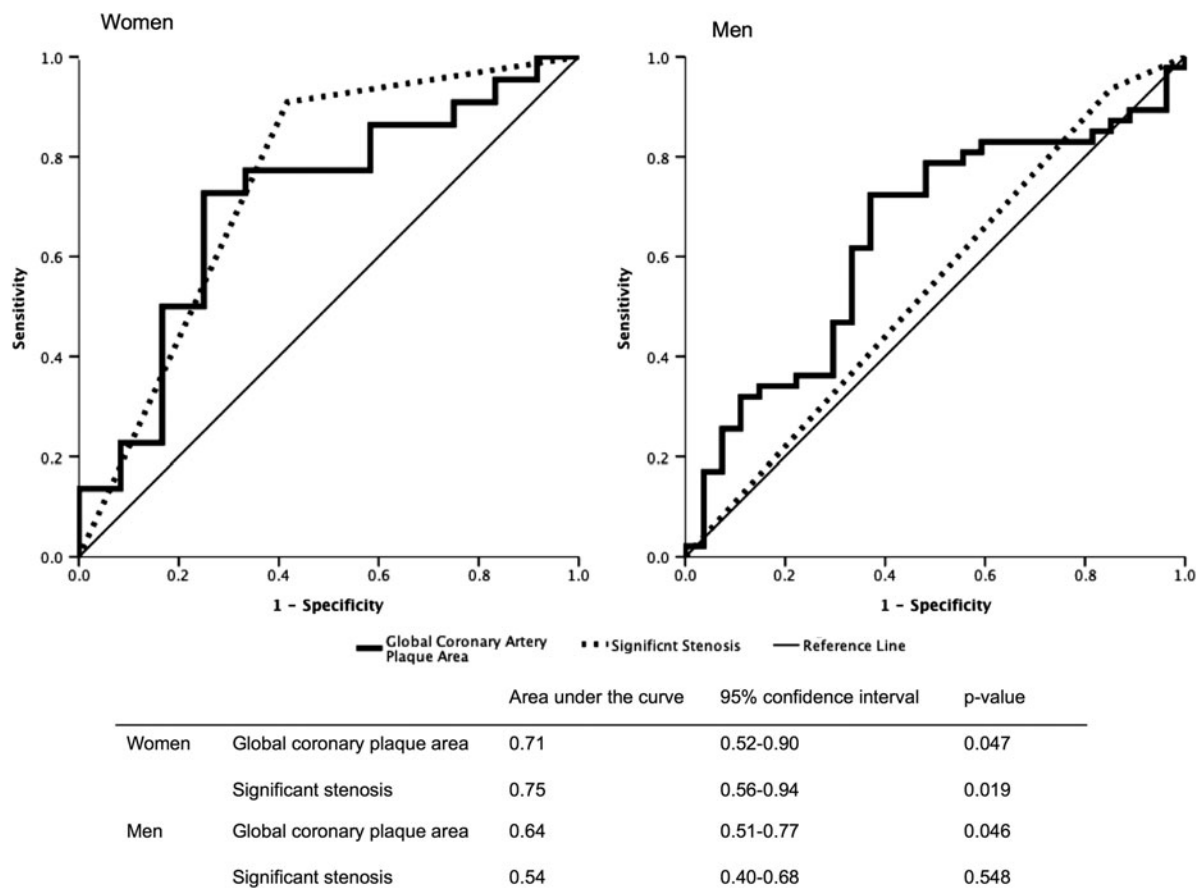


FIG. 3. Global coronary artery plaque area and severe myocardial hypoperfusion. Receiver operating curve analysis of the univariate association of presence of severe myocardial hypoperfusion with global coronary plaque area and presence of significant coronary artery stenosis in women and men.

TABLE 3. PREDICTORS OF SEVERE MYOCARDIAL HYPOPERFUSION (≥ 6 LV MYOCARDIAL SEGMENTS) IDENTIFIED IN UNIVARIATE AND MULTIVARIATE LOGISTIC REGRESSION ANALYSES

Independent variable	Univariate analysis			Multivariate analysis		
	OR	95% CI	p	OR	95% CI	p
Global coronary plaque area (per 10mm ²)	1.32	(1.05–1.66)	0.019	1.35	(1.01–1.80)	0.047
Significant stenosis	5.03	(1.60–15.83)	0.006	5.14	(1.29–20.54)	0.021
Age > 65 years	3.82	(1.67–8.73)	0.002	3.99	(1.51–10.55)	0.005
Female sex	1.05	(0.45–2.46)	0.905	1.72	(0.57–5.23)	0.339
Coronary tortuosity	0.50	(0.27–1.21)	0.123	0.49	(0.17–1.37)	0.173
Hypertension	0.61	(0.28–1.35)	0.22	0.51	(0.20–1.34)	0.173
Diabetes mellitus	0.70	(0.27–1.85)	0.48	0.47	(0.14–1.54)	0.213
Hypercholesterolemia	0.87	(0.40–1.91)	0.73	0.70	(0.26–1.86)	0.473

95% CI, 95% confidence interval; OR, odds ratio.

associated with severe myocardial hypoperfusion only in women, probably reflecting the low prevalence of non-obstructive CAD in men (Fig. 3).

Coronary artery tortuosity

A total of 273 native main coronary arteries were visible on the coronary angiograms. Of these, 34 were excluded due to low image quality, leaving 239 (88%) available for analysis of tortuosity. All three main coronary arteries could be assessed in 65 patients, two in 31 patients, and one in 7 patients. Tortuosity was more prevalent among women than men (Table 3). Global coronary artery plaque area did not differ between patients with tortuous and non-tortuous coronary arteries (42.0 ± 23.5 vs. 38.0 ± 17.4 mm², $p=0.367$). Tortuosity was not associated with the extent of myocardial hypoperfusion in the total study population or in men and women analyzed separately.

Determinants of myocardial hypoperfusion

A significant association was found between global coronary plaque area and both severity and extent of myocardial hypoperfusion in univariate analyses (both $p < 0.05$) (Tables 3, 4). In multiple logistic regression analysis, adjusting for known confounders of hypoperfusion, a 10 mm² higher global plaque area was associated with a 35% higher risk for having severe myocardial hypoperfusion on the echocardiogram (odds ratio 1.35; 95% CI 1.01–1.80, $p=0.047$), independent of presence of significant coronary artery stenosis

(Table 3). However, the association of larger global coronary plaque area with larger extent of myocardial hypoperfusion was attenuated and became borderline statistically significant when adjusted for confounders in multivariate analysis ($\beta=0.18$, $p=0.057$) (Table 4).

Discussion

The present study demonstrates that global coronary artery plaque area is an important determinant of the severity of myocardial hypoperfusion in NSTEMI patients, independent of presence of significant coronary artery stenoses. Of note, global coronary artery plaque area did not differ between sexes despite lower prevalence of obstructive CAD in women. In fact, nonobstructive CAD was nearly 3-fold more prevalent in women than in men in the present study, in accordance with previous reports from registries and meta-analyses.^{5,6} Although computer tomography coronary angiography is recognized as a superior method for assessment of coronary artery plaque area, invasive coronary angiography is the preferred diagnostic technique for diagnosis of CAD in current management guidelines for NSTEMI patients.¹⁷ Therefore, our findings are relevant for clinical practice.

Distinct sex differences in coronary atherosclerosis are well described.² Typically, women have more diffuse atherosclerosis, smaller arteries and more microvascular involvement.^{2,18} These factors may contribute to the reported sex difference in treatment procedures and outcome among CAD patients.^{19,20} Intravascular ultrasound in women with

TABLE 4. INDEPENDENT COVARIATES OF THE EXTENT OF LV MYOCARDIAL HYPOPERFUSION IN MULTIVARIATE LINEAR REGRESSION ANALYSIS (MULTIPLE $R^2=0.28$, $p < 0.01$)

Independent variable	Univariate analysis		Multivariate analysis			
	Beta coefficient	p	Beta coefficient	p	Tolerance	VIF
Global coronary plaque area (mm ²)	0.27	0.005	0.18	0.057	0.852	1.173
Age > 65 years	0.34	<0.001	0.28	0.003	0.885	1.130
Significant stenosis	0.37	<0.001	0.31	0.001	0.836	1.196
Coronary tortuosity	-0.16	0.094	-0.12	0.191	0.886	1.128
Female sex	-0.03	0.747	-0.06	0.523	0.799	1.251
Hypertension	-0.03	0.792	-0.05	0.616	0.905	1.105
Diabetes mellitus	0.02	0.843	-0.03	0.714	0.861	1.161
Hypercholesterolemia	-0.03	0.726	-0.10	0.308	0.841	1.189

VIF, variance inflation factor.

chest pain and nonobstructive CAD has demonstrated a high prevalence of atherosclerosis with positive remodeling and preserved lumen size.^{21,22} This emphasizes the limitation of the present study using angiography to estimate the coronary artery plaque area, since only the luminal narrowing is visualized on the angiogram. In addition, it was not possible to measure plaque area in coronary arteries < 1.5 mm in diameter with our method. Consequently, global coronary artery plaque area may have been underestimated, in particular in women in our study, due to the combination of more positive remodeling and smaller coronary artery diameter. Furthermore, angiographic normal reference segments often contain mild to moderate diffuse atherosclerosis, possibly leading to an underestimation of the true lumen diameter, and thereby of the plaque area.²³ Still, as demonstrated, reproducibility of global coronary plaque area measurement by our method was good.

The prognostic importance of the ischemic burden assessed by contrast echocardiography at rest has been documented in patients with acute chest pain.^{11,24} The use of contrast stress echocardiography in assessment of CAD risk in menopausal women is currently under evaluation.²⁵ In patients with myocardial infarction, larger extent of myocardial hypoperfusion by contrast echocardiography at rest has been demonstrated to predict unfavorable LV remodeling and impaired prognosis.^{24,26} Similarly, previous studies assessing myocardial perfusion by magnetic resonance imaging have reported increased morbidity, in particular hospitalizations for angina pectoris, in women with chest pain and nonobstructive CAD.^{10,27} Consequently, extent and severity of the perfusion abnormalities are important prognosticators in patients with different types of acute coronary syndromes.

It was recently demonstrated in a numerical simulation study that coronary artery tortuosity may induce myocardial ischemia through a reduction in coronary artery perfusion pressure.²⁸ Typically, coronary artery tortuosity is more prevalent in women and in patients with hypertension.⁹ In this study, tortuosity was indeed more prevalent in women, but not associated with hypertension. Coronary artery tortuosity was not associated with myocardial hypoperfusion at rest neither in women nor men. Thus, the clinical relevance of coronary tortuosity in NSTEMI remains to be established.

Finally, endothelial dysfunction, vessel inflammation and microvascular disease may all contribute to myocardial hypoperfusion in NSTEMI patients with nonobstructive CAD beyond the global coronary artery plaque area.^{2,29,30} However, these factors were not measured in the present study. On the other hand, hypertension and diabetes, comorbidities known to be associated with endothelial dysfunction did not differ between women and men, and also did not predict the extent of myocardial hypoperfusion in the present study.³¹

Conclusions

In women and men with NSTEMI, the global coronary artery plaque area was an important determinant of the severity of myocardial hypoperfusion at rest independent of presence of significant coronary stenoses. These findings may expand current understanding of NSTEMI in patients with nonobstructive CAD.

Author Disclosure Statement

No competing financial interests exist.

References

1. Qureshi W, Blaha MJ, Nasir K, Al-Mallah MH. Gender differences in coronary plaque composition and burden detected in symptomatic patients referred for coronary computed tomographic angiography. *Int J Cardiovasc Imaging* 2013;29:463–469.
2. Shaw LJ, Bugiardini R, Merz CN. Women and ischemic heart disease: Evolving knowledge. *J Am Coll Cardiol* 2009;54:1561–1575.
3. Falk E, Nakano M, Bentzon JF, Finn AV, Virmani R. Update on acute coronary syndromes: the pathologists' view. *Eur Heart J* 2013;34:719–728.
4. Sedlak TL, Lee M, Izadnegahdar M, Merz CN, Gao M, Humphries KH. Sex differences in clinical outcomes in patients with stable angina and no obstructive coronary artery disease. *Am Heart J* 2013;166:38–44.
5. Gehrie ER, Reynolds HR, Chen AY, et al. Characterization and outcomes of women and men with non-ST-segment elevation myocardial infarction and nonobstructive coronary artery disease: Results from the Can Rapid Risk Stratification of Unstable Angina Patients Suppress Adverse Outcomes with Early Implementation of the ACC/AHA Guidelines (CRUSADE) quality improvement initiative. *Am Heart J* 2009;158:688–694.
6. Berger JS, Elliott L, Gallup D, et al. Sex differences in mortality following acute coronary syndromes. *JAMA* 2009;302:874–882.
7. Lonnebakk MT, Nordrehaug JE, Gerdt E. No gender difference in the extent of myocardial ischemia in non-ST elevation myocardial infarction. *Eur J Prev Cardiol* 2014;21:123–129.
8. Lansky AJ, Ng VG, Maehara A, et al. Gender and the extent of coronary atherosclerosis, plaque composition, and clinical outcomes in acute coronary syndromes. *JACC Cardiovasc Imaging* 2012;5:S62–S72.
9. Li Y, Shen C, Ji Y, Feng Y, Ma G, Liu N. Clinical implication of coronary tortuosity in patients with coronary artery disease. *PLoS One* 2011;6:e24232.
10. Doyle M, Weinberg N, Pohost GM, et al. Prognostic value of global MR myocardial perfusion imaging in women with suspected myocardial ischemia and no obstructive coronary disease: results from the NHLBI-sponsored WISE (Women's Ischemia Syndrome Evaluation) study. *JACC Cardiovasc Imaging* 2010;3:1030–1036.
11. Anantharam B, Janardhanan R, Hayat S, Senior R. Ischaemic burden determined by myocardial contrast echocardiography predicts mortality in patients with new-onset shortness of breath, suspected heart failure and no previous coronary artery disease. *Int J Cardiol* 2013;168:1670–1671.
12. Lonnebakk MT, Staal EM, Nordrehaug JE, Gerdt E. Usefulness of contrast echocardiography for predicting the severity of angiographic coronary disease in non-ST-elevation myocardial infarction. *Am J Cardiol* 2011;107:1262–1267.
13. Antman EM, Cohen M, Bernink PJ, et al. The TIMI risk score for unstable angina/non-ST elevation MI: A method for prognostication and therapeutic decision making. *JAMA* 2000;284:835–842.
14. Austen WG, Edwards JE, Frye RL, et al. A reporting system on patients evaluated for coronary artery disease. Re-

- port of the Ad Hoc Committee for Grading of Coronary Artery Disease, Council on Cardiovascular Surgery, American Heart Association. *Circulation* 1975;51:5–40.
15. Lang RM, Bierig M, Devereux RB, et al. Recommendations for chamber quantification. *Eur J Echocardiogr* 2006; 7:79–108.
 16. Senior R, Becher H, Monaghan M, et al. Contrast echocardiography: evidence-based recommendations by European Association of Echocardiography. *Eur J Echocardiogr* 2009;10:194–212.
 17. Hamm CW, Bassand JP, Agewall S, et al. ESC Guidelines for the management of acute coronary syndromes in patients presenting without persistent ST-segment elevation: The Task Force for the management of acute coronary syndromes (ACS) in patients presenting without persistent ST-segment elevation of the European Society of Cardiology (ESC). *Eur Heart J* 2011;32:2999–3054.
 18. Johnston N, Schenck-Gustafsson K, Lagerqvist B. Are we using cardiovascular medications and coronary angiography appropriately in men and women with chest pain? *Eur Heart J* 2011 Jun;32:1331–1336.
 19. Poon S, Goodman SG, Yan RT, et al. Bridging the gender gap: Insights from a contemporary analysis of sex-related differences in the treatment and outcomes of patients with acute coronary syndromes. *Am Heart J* 2012;163:66–73.
 20. Trienekens MP, Mass AH, Timman ST, Van Swieten HA, Noyez L. Sex differences in patient and procedural characteristics and early outcomes following cardiac surgery. *J Cardiovasc Surg (Torino)* 2014. Epub ahead of print.
 21. Khuddus MA, Pepine CJ, Handberg EM, et al. An intravascular ultrasound analysis in women experiencing chest pain in the absence of obstructive coronary artery disease: A substudy from the National Heart, Lung and Blood Institute-Sponsored Women's Ischemia Syndrome Evaluation (WISE). *J Interv Cardiol* 2010;23:511–519.
 22. Al-Khalili F, Svane B, Di Mario C, et al. Intracoronary ultrasound in women with myocardial infarction without significant coronary lesions. *Coron Artery Dis* 2000;11: 579–584.
 23. Mintz GS, Painter JA, Pichard AD, et al. Atherosclerosis in angiographically “normal” coronary artery reference segments: an intravascular ultrasound study with clinical correlations. *J Am Coll Cardiol* 1995;25:1479–1485.
 24. Wei K, Peters D, Belcik T, et al. A predictive instrument using contrast echocardiography in patients presenting to the emergency department with chest pain and without ST-segment elevation. *J Am Soc Echocardiogr* 2010;23: 636–642.
 25. Abdelmoneim SS, Bernier M, Hagen ME, et al. A multicenter, prospective study to evaluate the use of contrast stress echocardiography in early menopausal women at risk for coronary artery disease: Trial design and baseline findings. *J Womens Health (Larchmt)* 2013; 22:173–183.
 26. Dwivedi G, Janardhanan R, Hayat SA, Swinburn JM, Senior R. Prognostic value of myocardial viability detected by myocardial contrast echocardiography early after acute myocardial infarction. *J Am Coll Cardiol* 2007;50:327–334.
 27. Johnson BD, Shaw LJ, Buchthal SD, et al. Prognosis in women with myocardial ischemia in the absence of obstructive coronary disease: Results from the National Institutes of Health-National Heart, Lung, and Blood Institute-Sponsored Women's Ischemia Syndrome Evaluation (WISE). *Circulation* 2004;109:2993–2999.
 28. Li Y, Shi Z, Cai Y, et al. Impact of coronary tortuosity on coronary pressure: Numerical simulation study. *PLoS One* 2012;7:e42558.
 29. Crea F, Camici PG, Bairey Merz CN. Coronary microvascular dysfunction: An update. *Eur Heart J* 2014;35: 1101–1111.
 30. Wang HX, Leineweber C, Kirkeeide R et al. Psychosocial stress and atherosclerosis. Family and work stress accelerates progression of coronary disease in women. The Stockholm Female Coronary Angiography Study. *J Int Med* 2007;261:245–254.
 31. Munzel T, Sinning C, Post F, Warnholtz A, Schulz E. Pathophysiology, diagnosis and prognostic implications of endothelial dysfunction. *Ann Med* 2008;40:180–196.

Address correspondence to:
Mai Tone Lønnebakken, MD, PhD
Department of Clinical Science
University of Bergen
5021 Bergen
Norway

E-mail: mai.lonnebakken@k2.uib.no