

Combined endorectal ultrasonography and strain elastography for the staging of early rectal cancer

J. E. R. Waage*†, S. P. Bach‡, F. Pfeffer*†, S. Leh†§, R. F. Havre†¶, S. Ødegaard†¶ and G. Baatrup†**††

*Department of Surgery, Haukeland University Hospital, Bergen, Norway, †Department of Clinical Medicine, University of Bergen, Bergen, Norway, ‡Academic Department of Surgery, Queen Elizabeth Hospital, Edgbaston, Birmingham, UK, §Department of Pathology, Haukeland University Hospital, Bergen, Norway, ¶National Centre for Ultrasound in Gastroenterology, Department of Medicine, Haukeland University Hospital, Bergen, Norway, **Department of Surgery A, Odense University Hospital, Svendborg, Denmark and ††Institute of Regional Health Science, University of Southern Denmark, Odense, Denmark

Received 30 April 2014; accepted 27 June 2014; Accepted Article online 1 September 2014

Abstract

Aim Strain elastography is a novel approach to rectal tumour evaluation. The primary aim of this study was to correlate elastography to pT stages of rectal tumours and to assess the ability of the method to differentiate rectal adenomas (pT0) from early rectal cancer (pT1–2). Secondary aims were to compare elastography with endorectal ultrasonography (ERUS) and to propose a combined strain elastography and ERUS staging algorithm.

Method In all, 120 consecutive patients with a suspected rectal tumour were examined in this staging study. Patients receiving surgery without neoadjuvant radiotherapy were included ($n = 59$). All patients were examined with ERUS and elastography. Treatment decisions were made by multidisciplinary team (MDT) assessment, without considering the strain elastography examination.

Results Histopathology identified 21 adenomas, 13 pT1, 9 pT2, 15 pT3 and one pT4. Mean elastography strain ratios were predictive of T stage ($P = 0.01$). Differentiation of adenomas from early rectal cancer (pT1–2) had sensitivity, specificity and accuracy of 0.82, 0.86 and 0.84 for elastography and 0.82, 0.62 and 0.72 for

ERUS. A combined staging algorithm was developed to identify tumours eligible for local resection. Based on MDT evaluation 32% of tumours later identified as pT0 or pT1 were treated with total mesorectal excision, even though a local excision might have sufficed. Combined ERUS and elastography evaluation would have significantly reduced this number to 9% ($P = 0.008$).

Conclusion Elastography may improve the staging of adenomas and early rectal cancer compared with ERUS alone. Combined ERUS and elastography assessment is likely to further improve the selection of patients for local resection.

Keywords Rectal cancer, early-stage rectal neoplasms, elastography, strain ratio, endorectal ultrasound

What does this paper add to the literature?

This paper is to our knowledge the first to demonstrate the ability of endorectal elastography to improve staging of pT0, pT1 and pT2 rectal tumours, proposing a combined ERUS and elastography approach to early rectal cancer staging.

Correspondence to: Jo Erling Riise Waage MD, Department of Surgery, Helse Bergen HF, Haukeland University Hospital, NO-5021 Bergen, Norway.
E-mail: dr.waage@gmail.com

Preliminary results have been presented as poster presentations at the European Colorectal Congress, St Gallen, 28 November to 2 December 2011, and the European Multidisciplinary Colorectal Cancer Congress, Prague, 15–17 April 2012, and as an oral presentation at the Scandinavian TEM and Early Rectal Cancer Conference, Bergen, 1–3 May 2013.

The copyright line for this article was changed on 6th November, 2015 after original online publication.

Introduction

Bowel cancer screening programmes have increased early diagnosis of rectal neoplasia [1,2]. Benign adenomas and early rectal cancers confined to the submucosa (pT1) are most appropriately offered endoluminal resection as the primary treatment [3–5] and all early cancers (pT1/pT2) may be considered for trials of multimodal, minimal invasive therapy [6–13]. The ability to distinguish adenomas (pT0) from early rectal cancers (pT1–2, N0) has therefore become a priority, in addition to differentiating pT1 tumours eligible for local resection

from pT2 tumours more appropriately treated with resectional surgery/total mesorectal excision.

MRI is currently unable to discriminate adenomas from early rectal cancer [14], and even biopsies under-stage a significant proportion of early cancers due to intra-tumour heterogeneity [15–17]. Endorectal ultrasonography (ERUS) currently forms the best basis for early rectal cancer T staging. While meta-analyses suggest high precision for ERUS T staging [18,19], discriminating rectal adenomas from early rectal cancer often remains difficult [20–24].

Strain elastography [25,26] is a novel approach to rectal tumour evaluation. The semi-quantification of tissue hardness is enabled by using a quasi-static autocorrelation real time elastography method as previously described [21,27–29]. Strains of insonified tissue are calculated from the frame-to-frame movement of tissue echoes under a relatively slow compression and decompression. Clinical application for the differentiation of benign and malignant tumours has been validated in several organs [30–34]. There are few studies on the evaluation of elastography of rectal tumours [21,35] and to our knowledge no previous study has been published assessing elastography staging of early-stage rectal neoplasia.

The primary aim of this study was to correlate strain ratio with pT stage and to assess the ability of endorectal strain elastography to improve the staging of early-stage rectal neoplasia compared with ERUS. As the elastography algorithm is based on the information provided by ERUS B-mode images, it should be regarded as an adjunct to ERUS examination in clinical practice. Consequently a secondary aim was to compose a combined elastography and ERUS algorithm for the assessment of early rectal cancer.

Method

Patients

One hundred and twenty consecutive patients referred to Haukeland University Hospital for diagnostic evaluation

and staging of suspected rectal tumour were considered in this study. Results are presented from 59 patients who were not treated with preoperative radiotherapy. Inclusion criteria were (i) patients presenting with a sessile rectal adenoma or adenocarcinoma, (ii) distal border ≤ 15 cm above the anal verge by rigid rectosigmoidoscopy, (iii) subsequent surgical excision and (iv) no use of neoadjuvant radiation therapy. Patients who had had previous rectal surgery or pelvic radiotherapy were also excluded. Informed consent was mandatory. Patient characteristics are summarized in Table 1.

ERUS and endorectal strain elastography

We used a standard ultrasonography scanner equipped with software for elastography (Hitachi EUB-8500, software version V16-04A; Hitachi Medical Corporation, Kashiva, Japan). Ultrasound imaging and elastography were performed with a rigid 360° rectal ultrasound probe (Hitachi EUP-R54AW-19) at 10 MHz.

The patients were subjected to a same-session standardized clinical examination, ERUS and strain elastography as described previously [21]. All examinations were performed by a single examiner. ERUS T staging was based on tumour growth through the rectal wall layers according to the TNM classification system and conclusions were recorded before elastography evaluation was initiated. In one patient (pT2) the ERUS and elastography were technically not feasible according to protocol. A predefined strain ratio (SR) cut-off [21] was used to distinguish adenomas from early rectal cancer.

A graded set of elastography SR cut-off levels based on a receiver operator characteristics (ROC) analysis was used for the combined elastography and ERUS assessment. Based on the ROC analysis SR ≤ 0.80 identified only T0 tumours and an SR interval from 0.81 to 1.60 identified only T0–1 tumours. The latter could be sub-stratified into intervals of SR 0.81–1.10 and SR 1.11–1.60. Finally SR ≥ 1.61 identified T2–4 tumours

Table 1 Characteristics of the 59 included patients. Mean tumour size and location above the anal verge were measured by rigid rectoscopy.

	Total	pT0	pT1	pT2	pT3	pT4
Included patients	59 (100%)	21 (36%)	13 (22%)	9 (15%)	15 (25%)	1 (2%)
Age (years), mean	69	69	66	77	66	77
Treatment						
TEM	23	18	5	0	0	0
Major surgery	36	3	8	9	15	1
Mean tumour location above anal verge (cm)	8	8	6	10	10	14
Mean tumour size (cm)	3	2	2	2	4	3

TEM, transanal endoscopic microsurgery.

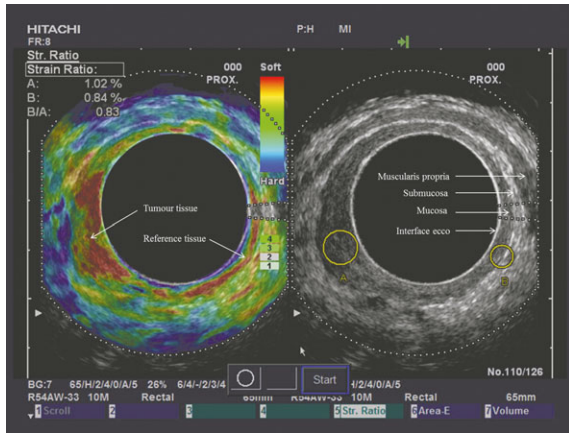


Figure 1 A pT0 tumour situated 5–7 cm above the anal verge involving a circumference from 7 to 10 o'clock. The split screen image shows a B-mode image with strain ratio regions of interest on the right-hand side and an elastogram on the left-hand side. The tumour appears softer (more red) than the same-depth reference tissue on the elastogram, and the strain ratio (B/A) (SR = 0.83) is displayed in the upper left-hand corner.

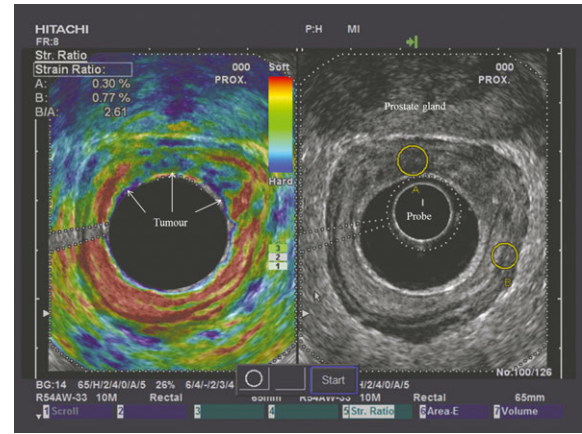


Figure 2 A pT2 tumour situated 6–9 cm above the anal verge, involving a circumference from 11 to 3 o'clock. The split screen image shows a B-mode image on the right-hand side, with strain ratio regions of interest (A, tumour tissue; B, reference tissue). An elastogram is displayed on the left-hand side, with tumour tissue appearing harder (more blue) than the same-depth reference tissue on the elastogram. A strain ratio (B/A) of 2.61 is displayed in the upper left-hand corner.

but also included some T0 and T1 tumours. These intervals were combined with ERUS T staging into a combined ERUS and elastography staging algorithm (Figs. 1–3).

Histopathological evaluation

The examiner was not aware of any biopsy result prior to the ERUS or elastography examination. Transanal endoscopic microsurgery (TEM) specimens were pinned on a plate, fixed, serially sectioned at 2–3 mm intervals

and completely embedded. Rectum resection specimens were sliced at 3–4 mm intervals and representative sections were selected for microscopy. Tissue sections were stained with haematoxylin and eosin.

Statistical analysis

An SR cut-off defining malignancy as $SR \geq 1.25$ was derived from pilot work in a discovery set of tumours [21] for the initial comparison of strain elastography and ERUS. The test validity parameters sensitivity, specificity, accuracy, negative predictive value and positive

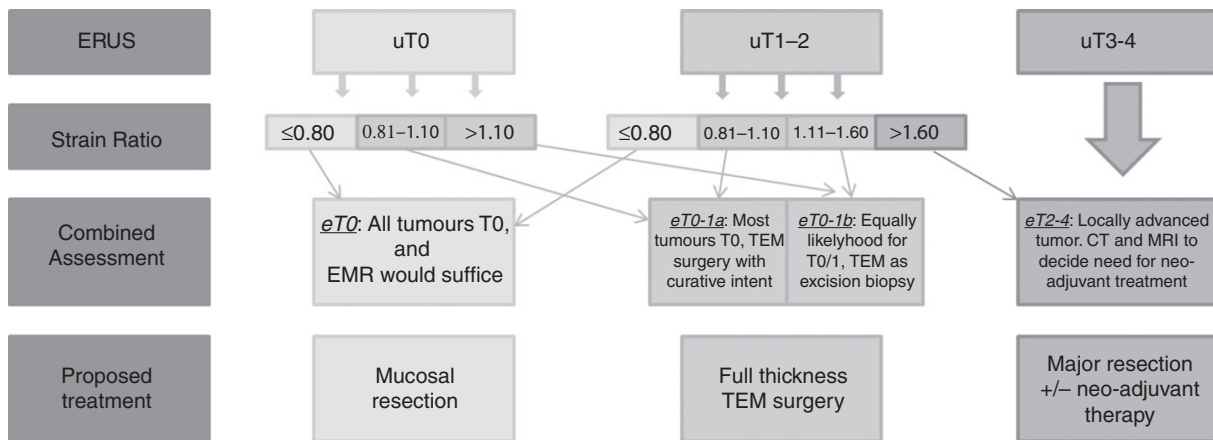


Figure 3 Flow-chart showing the combined ERUS and elastography T stage (eT) and proposed treatment, illustrating the potential of strain ratio assessment combined with ERUS uT staging. Note that all tumours confidently defined as uT0 are eligible for local resection regardless of strain ratio. Tumours confidently defined as uT3 or uT4 do not have any added staging benefit from combined assessment and elastography can be omitted.

predictive value were calculated for elastography SR evaluation, ERUS evaluation, the combined assessment algorithm and multidisciplinary team (MDT) assessment.

Histopathology of the resection specimens was used as reference standard.

One-way ANOVA was used to test for differences in SR values between T stages. The Blyth–Still–Casella procedure was chosen to calculate confidence intervals (CI) of test validity parameters [36,37]. An ROC curve analysis was performed to identify the SR cut-off for the combined ERUS elastography T staging algorithm. The SPSS® version 21.0 (SPSS, Chicago, IL, USA), STATXACT 9.0 (Cytel Software Corporation, Cambridge, MA, USA) and Excel (Microsoft® Office Excel 2003, Microsoft Corporation, Redmond, WA, USA) were used for data analysis.

Ethics

All patients received oral and written information according to the Helsinki Declaration prior to signing the consent form. The study was approved by the Regional Committee for Medical and Health Research Ethics of Western Norway.

Results

Histopathology tumour stages

Tumour stage was verified by histopathological assessment as 21 adenomas (pT0), 13 pT1 tumours, nine pT2 tumours, 15 pT3 tumours and one pT4 tumour. One ERUS/strain elastography examination of a pT2 tumour was technically not feasible. Consequently a total of 58 patients were included in the statistical analyses and 42 in the sub-analysis of adenomas (pT0) and early rectal cancers (pT1–2).

Elastography SR assessment

The elastography SR of different pT stages was significantly different ($P = 0.01$, one-way ANOVA) with a mean SR (95% CI) for individual T stages of T0, 1.03 (0.88–1.22); T1, 2.44 (1.67–3.33); T2, 6.29 (2.30–11.55); and T3, 4.52 (2.92–11.01).

Using the predefined SR cut-off defining ≥ 1.25 as adenocarcinomas and < 1.25 as adenomas to differentiate T0 from T1–2 yielded a sensitivity of 0.82 (95% CI 0.61–0.94), a specificity of 0.86 (95% CI 0.66–0.96), an accuracy of 0.84 (95% CI 0.71–0.93), a positive predictive value of 0.84 (95% CI 0.71–0.93) and a negative predictive value of 0.82 (95% CI 0.61–0.94).

ERUS assessment

The isolated ERUS evaluation correctly staged 13/21 (62%) of pT0 tumours, 6/13 (46%) of pT1 tumours, 1/8 (13%) of pT2 tumours and 14/15 (93%) of pT3 tumours. Eight pT0 tumours were overstaged as either uT1 or uT2; three pT1 were overstaged as uT2 or uT3 and four pT1 was understaged as uT0. Although 7/8 pT2 tumours were overstaged as uT3, these were interpreted as ‘not uT0’ for the purpose of differentiating adenomas (pT0) from early rectal cancer (pT1–2). Consequently the isolated ERUS differentiation of pT0 from pT1–2 yielded a sensitivity of 0.82 (95% CI 0.61–0.94), a specificity of 0.62 (95% CI 0.40–0.80), an accuracy of 0.72 (95% CI 0.58–0.85), a positive predictive value of 0.69 (95% CI 0.49–0.85) and a negative predictive value of 0.76 (95% CI 0.51–0.92).

Combined ERUS and graded elastography SR assessment

The proposed algorithm for a combined ERUS and elastography assessment T stage (eT) is shown in Fig. 3. The combined eT0 assessment did not understage any adenocarcinoma as pT0 while correctly identifying 7/21 pT0 tumours. The eT0–1a and eT0–1b included all remaining adenomas and 10/13 pT1 tumours. No pT2–4 tumours were understaged with the combined assessment. In the patient series in this study 11/34 (32.4%) of tumours subsequently identified as pT0 or pT1 were treated with major resection based on MDT evaluation. If the proposed combined ERUS elastography eT staging algorithm had been applied this number of potentially ‘unnecessary’ major resections of the rectum would have been significantly reduced to 3/34 (8.8%, $P = 0.008$). Validity parameters are summarized in Table 3.

Discussion

The current study is, to our knowledge, the first to evaluate the benefit of endorectal elastography SR measurements in the staging of adenomas and early rectal cancer. Strain elastography SR measurements were significantly different between different T stages ($P > 0.001$, one-way ANOVA). However, this difference does not seem to pertain to the SRs of pT2 and pT3 tumours, as demonstrated by their relatively wide and overlapping confidence intervals.

Consequently the potential benefit of elastography assessment is most likely to be related to early-stage neoplasia. Although ERUS is recognized as the most accurate staging modality for the early tumour [18,19], the

differentiation of stages T0–T2 is challenging and depends on both examination technique and interpretation of the acquired images [20–24]. Our reported accuracy of ERUS (0.72; 95% CI 0.49–0.85) is consistent with the literature, as the higher reported accuracies are commonly associated with a high number of pT3 tumours and few or no pT0 tumours. When the predefined cut-off value of 1.25 was used to separate T0 tumours from T1–2 tumours, the accuracy improved compared with the assessment by ERUS (0.84; 95% CI 0.71–0.93) (Table 2). Consequently using a simple dichotomous cut-off based on SR measurements may improve the ability of ERUS to identify adenomas eligible for local resection.

The isolated comparison of ERUS and elastography SR assessment is not as clinically relevant as a combined assessment. The continuous nature of SR measurements enables a graded approach to tumour assessment and as elastography evaluation in clinical practice is an add-on to the ERUS assessment a combined assessment strategy is a more sensible approach than regarding them as two distinctly separate methods. As explained in detail in the Method section, a graded set of elastography SR cut-off levels was deduced based on an ROC curve analysis and combined with the preceding ERUS uT stage. The combined ERUS and elastography T stage (eT) is shown in Fig. 3. The algorithm was designed to stage tumours as eT0, eT0–1a, eT0–1b or eT2–4 (Fig. 3), combining the strengths of the two methods. If a confident distinction between uT0 and uT1 can be made based on the ERUS assessment, a local resection should be performed regardless of SR measurements, but if a well-defined full-thickness submucosa is not clearly depicted throughout the tumour the combined eT stage should be used to decide whether a local resection would be appropriate. Also, the tendency to under-stage T1 tumours as uT0 suggests that only tumours with $SR \leq 0.80$ should be considered for endoscopic

Table 2 Elastography strain ratio and ERUS differentiation of adenomas (pT0) and early rectal cancer (pT1–2) (95% confidence interval in parentheses, Blyth–Still–Casella) using a strain ratio of 1.25 as the cut-off value.

	ERUS (<i>n</i> = 42)	Elastography (<i>n</i> = 42)
Sensitivity	0.82 (0.61, 0.94)	0.82 (0.61, 0.94)
Specificity	0.62 (0.40, 0.80)	0.86 (0.66, 0.96)
Accuracy	0.72 (0.58, 0.85)	0.84 (0.71, 0.93)
PPV	0.69 (0.49, 0.85)	0.86 (0.66, 0.96)
NPV	0.76 (0.51, 0.92)	0.82 (0.61, 0.94)

PPV, positive predictive value; NPV, negative predictive values; ERUS, endorectal ultrasonography.

Table 3 Validity parameters for combined strain elastography and ERUS differentiation compared with MDT assessment. Positive state was a tumour suitable for resectional surgery (pT2–4) and negative state was a tumour suitable for local resection (pT0–1). The reference standard was histopathological evaluation of the surgical specimen.

	Combined elastography/ ERUS assessment (<i>n</i> = 59)	MDT assessment (<i>n</i> = 59)
Sensitivity	1.00 (0.91, 1.00)	0.88 (0.70, 0.97)
Specificity	0.88 (0.70, 0.97)	0.68 (0.50, 0.81)
Accuracy	0.95 (0.86, 0.99)	0.76 (0.64, 0.86)
PPV	0.92 (0.79, 0.98)	0.67 (0.48, 0.81)
NPV	1.00 (0.87, 1.00)	0.88 (0.70, 0.97)

PPV, positive predictive value; NPV, negative predictive value; ERUS, endorectal ultrasonography; MDT, multidisciplinary team.

removal with a high likelihood of a piece-meal resection specimen.

Our results suggest that tumours confidently defined as uT3 or uT4 do not have any added staging benefit from combined assessment, and elastography can consequently be omitted. The suggested treatment categories were chosen based on national and local guidelines and would potentially differ based on the available treatment modalities in different centres or ongoing study protocols.

In this study 11/34 (32.4%) patients were treated with resectional surgery when on the basis of pathology (pT0 or pT1) a local excision might have been sufficient surgical treatment. This could be considered overtreatment and demonstrates the hazards of overstaging by the combined assessment of biopsies, endoscopy, CT, ERUS and MRI examination. Based on the proposed combined ERUS and elastography assessment this number would have been significantly reduced to 3/34 (8.8%, $P = 0.008$), whilst at the same time allocating all pT2–4 tumours for resectional surgery.

Other tumour characteristics such as size and location of tumour, histopathological features such as degree of differentiation, invasion in blood or lymphatic vessels and tumour budding in addition to patient related factors such as comorbidity, age and patient preferences are also important as part of the clinical decision-making process. Some pT1 tumours treated by TEM will be offered salvage surgery in the form of a total mesorectal excision based upon the presence of these risk factors in the resected TEM specimen. We recognize that all these factors should be taken into account in future decision-making.

The identification and evaluation of mesorectal lymph nodes are an important part of the treatment

decision, but elastography evaluation of lymph nodes was beyond the scope of this study.

Although a rigorous protocol for choosing tumour tissue and reference tissue on the B-mode pictures before elastography was applied to minimize bias, all elastography examinations was performed by one examiner immediately following the ERUS examination. Consequently an observer bias is possible. A sampling algorithm for SR evaluation was designed to avoid this, ensuring that only a grey-scale B-mode image was visible when regions of interest were chosen. Due to technical limitations regarding the format of saved elastography video loops and images, a blinded SR re-examination was not possible, making a reliability evaluation of elastography SR measurements unattainable.

In this study we have used a strain imaging method (extended combined autocorrelation method). Other elastography methods are available in combination with ultrasound imaging, based on vibration or shear-wave speed measurements. These algorithms have not been available, however, with probes designed for 360° imaging of rectal structures. It is important to note that other elastography algorithms or even updated software versions of strain elastography may produce different cut-off values. Definite cut-off values should be validated before being applied in clinical practice, but our findings suggest that the differences in strain patterns are due to morphological differences between adenomas, early rectal cancers and locally advanced cancers and as such the principle of eT staging is most probably applicable to other elastography algorithms.

In conclusion, the evaluation of rectal neoplasms by strain elastography may improve the preoperative staging of adenomas and early rectal cancer. A combined ERUS and elastography T staging seems able to improve the selection of patients for local resection. Future studies should be aimed at assessing the combined ERUS and elastography assessment as an integral part of the pretreatment algorithm to evaluate the actual impact on treatment decisions.

Acknowledgements

The study was founded by Helse Vest Research Foundation and the Grieg Foundation, but neither played any part in the development or approval of this paper. We would like to thank Professor Geir Egil Eide for valuable statistical advice.

Author contributions

Jo Erling Riise Waage: Conception and design of the study, acquisition of data, analysis and interpretation of

data, drafting and revising the article, final approval of the submitted manuscript. Simon P. Bach: Substantial contributions to conception and design, data interpretation, critical revision of the article and final approval of the submitted manuscript. Frank Pfeffer: Substantial contributions to design, data interpretation, critical revision of the article and final approval of the submitted manuscript. Sabine Leh: Preparation of protocol, acquisition of pathology data, data interpretation, critical revision of the article and final approval of the submitted manuscript. Roald Flesland Havre: Substantial contributions to conception and design, data interpretation, critical revision of the article and final approval of the submitted manuscript. Svein Ødegaard: Substantial contributions to conception and design, data interpretation, critical revision of the article and final approval of the submitted manuscript. Gunnar Baatrup: Substantial contributions to conception and design, data interpretation, critical revision of the article and final approval of the submitted manuscript.

Conflicts of interest

None.

References

- 1 Steele RJ, McClements P, Watling C *et al.* Interval cancers in a FOBT-based colorectal cancer population screening programme: implications for stage, gender and tumour site. *Gut* 2012; **61**: 576–81.
- 2 Atkin WS, Edwards R, Kralj-Hans I *et al.* Once-only flexible sigmoidoscopy screening in prevention of colorectal cancer: a multicentre randomised controlled trial. *Lancet* 2010; **375**: 1624–33.
- 3 Tytherleigh MG, Warren BF, Mortensen NJ. Management of early rectal cancer. *Br J Surg* 2008; **95**: 409–23.
- 4 Darwood RJ, Wheeler JM, Borley NR. Transanal endoscopic microsurgery is a safe and reliable technique even for complex rectal lesions. *Br J Surg* 2008; **95**: 915–8.
- 5 Baatrup G, Breum B, Qvist N *et al.* Transanal endoscopic microsurgery in 143 consecutive patients with rectal adenocarcinoma: results from a Danish multicenter study. *Colorectal Dis* 2009; **11**: 270–5.
- 6 Habr-Gama A, Perez RO. Non-operative management of rectal cancer after neoadjuvant chemoradiation. *Br J Surg* 2009; **96**: 125–7.
- 7 Glynne-Jones R, Hughes R. Critical appraisal of the 'wait and see' approach in rectal cancer for clinical complete responders after chemoradiation. *Br J Surg* 2012; **99**: 897–909.
- 8 Maas M, Beets-Tan RG, Lambregts DM *et al.* Wait-and-see policy for clinical complete responders after chemoradiation for rectal cancer. *J Clin Oncol* 2011; **29**: 4633–40.

- 9 Garcia-Aguilar J, Shi Q, Thomas CR Jr *et al.* A phase II trial of neoadjuvant chemoradiation and local excision for T2N0 rectal cancer: preliminary results of the ACOSOG Z6041 trial. *Ann Surg Oncol* 2012; **19**: 384–91.
- 10 Bach S, Morton D, Monson J *et al.* TREC TRIAL PROTOCOL – a randomised phase II feasibility study to compare radical TME surgery versus short course preoperative radiotherapy with delayed local excision for treatment of early rectal cancer, 2012; <http://www.birmingham.ac.uk/Documents/college-mds/trials/bctu/trec/TREC-protocol-v2.pdf>.
- 11 Bokkerink GM, de Graaf EJ, Punt CJ *et al.* The CARTS study: chemoradiation therapy for rectal cancer in the distal rectum followed by organ-sparing transanal endoscopic microsurgery. *BMC Surg* 2011; **11**: 34.
- 12 Lezoche E, Baldarelli M, Lezoche G, Paganini AM, Gesuita R, Guerrieri M. Randomized clinical trial of endoluminal locoregional resection versus laparoscopic total mesorectal excision for T2 rectal cancer after neoadjuvant therapy. *Br J Surg* 2012; **99**: 1211–8.
- 13 Lezoche G, Guerrieri M, Baldarelli M *et al.* Transanal endoscopic microsurgery for 135 patients with small non-advanced low rectal cancer (iT1–iT2, iN0): short- and long-term results. *Surg Endosc* 2011; **25**: 1222–9.
- 14 Kaur H, Choi H, You YN *et al.* MR imaging for preoperative evaluation of primary rectal cancer: practical considerations. *Radiographics* 2012; **32**: 389–409.
- 15 Brouwer R, MacDonald A, Matthews R, Gunn J, Monson JR, Hartley JE. Brush cytology for the diagnosis of colorectal cancer. *Dis Colon Rectum* 2009; **52**: 598–601.
- 16 Collepriest BJ, Marden PF, Linehan JD. What is the optimal number of biopsies to diagnose a tumor found during colonoscopy? *J Clin Gastroenterol* 2009; **43**: 1012–3.
- 17 Baatrup G, Elbrond H, Hesselfeldt P *et al.* Rectal adenocarcinoma and transanal endoscopic microsurgery. Diagnostic challenges, indications and short term results in 142 consecutive patients. *Int J Colorectal Dis* 2007; **22**: 1347–52.
- 18 Puli SR, Bechtold ML, Reddy JB, Choudhary A, Antillon MR, Brugge WR. How good is endoscopic ultrasound in differentiating various T stages of rectal cancer? Meta-analysis and systematic review. *Ann Surg Oncol* 2009; **16**: 254–65.
- 19 Bipat S, Glas AS, Slors FJ, Zwinderman AH, Bossuyt PM, Stoker J. Rectal cancer: local staging and assessment of lymph node involvement with endoluminal US, CT, and MR imaging – a meta-analysis. *Radiology* 2004; **232**: 773–83.
- 20 Ashraf S, Hompes R, Slater A *et al.* A critical appraisal of endorectal ultrasound and transanal endoscopic microsurgery and decision-making in early rectal cancer. *Colorectal Dis* 2012; **14**: 821–6.
- 21 Waage JE, Havre RF, Odegaard S, Leh S, Eide GE, Baatrup G. Endorectal elastography in the evaluation of rectal tumours. *Colorectal Dis* 2011; **13**: 1130–7.
- 22 Doornebosch PG, Bronkhorst PJ, Hop WC, Bode WA, Sing AK, de Graaf EJ. The role of endorectal ultrasound in therapeutic decision-making for local vs. transabdominal resection of rectal tumors. *Dis Colon Rectum* 2008; **51**: 38–42.
- 23 Puli SR, Bechtold ML, Reddy JB, Choudhary A, Antillon MR. Can endoscopic ultrasound predict early rectal cancers that can be resected endoscopically? A meta-analysis and systematic review. *Dig Dis Sci* 2010; **55**: 1221–9.
- 24 Kwok H, Bissett IP, Hill GL. Preoperative staging of rectal cancer. *Int J Colorectal Dis* 2000; **15**: 9–20.
- 25 Cosgrove D, Piscaglia F, Bamber J *et al.* EFSUMB guidelines and recommendations on the clinical use of ultrasound elastography. Part 2: Clinical applications. *Ultraschall Med* 2013; **34**: 238–53.
- 26 Bamber J, Cosgrove D, Dietrich CF *et al.* EFSUMB guidelines and recommendations on the clinical use of ultrasound elastography. Part 1: Basic principles and technology. *Ultraschall Med* 2013; **34**: 169–84.
- 27 Havre RF, Leh S, Gilja OH *et al.* Strain assessment in surgically resected inflammatory and neoplastic bowel lesions. *Ultraschall Med* 2014; **35**: 149–58.
- 28 Havre RF, Elde E, Gilja OH *et al.* Freehand real-time elastography: impact of scanning parameters on image quality and *in vitro* intra- and interobserver validations. *Ultrasound Med Biol* 2008; **34**: 1638–50.
- 29 Havre RF, Waage JR, Gilja OH, Odegaard S, Nesje LB. Real-time elastography: strain ratio measurements are influenced by the position of the reference area. *Ultraschall Med* 2011; doi: 10.1055/s-0031-1273247. [Epub ahead of print].
- 30 Alhabshi SM, Rahmat K, Abdul Halim N *et al.* Semi-quantitative and qualitative assessment of breast ultrasound elastography in differentiating between malignant and benign lesions. *Ultrasound Med Biol* 2013; **39**: 568–78.
- 31 Saftoiu A, Vilman P, Gorunescu F *et al.* Accuracy of endoscopic ultrasound elastography used for differential diagnosis of focal pancreatic masses: a multicenter study. *Endoscopy* 2011; **43**: 596–603.
- 32 Onur MR, Poyraz AK, Ucak EE, Bozgeyik Z, Ozercan IH, Ogur E. Semiquantitative strain elastography of liver masses. *J Ultrasound Med* 2012; **31**: 1061–7.
- 33 Junker D, Schafer G, Aigner F *et al.* Potentials and limitations of real-time elastography for prostate cancer detection: a whole-mount step section analysis. *Scientific World Journal* 2012; **2012**: 193213.
- 34 Lyshchik A, Higashi T, Asato R *et al.* Thyroid gland tumor diagnosis at US elastography. *Radiology* 2005; **237**: 202–11.
- 35 Rafaelsen SR, Vagn-Hansen C, Sorensen T, Lindebjerg J, Ploen J, Jakobsen A. Ultrasound elastography in patients with rectal cancer treated with chemoradiation. *Eur J Radiol* 2013; **82**: 913–7.
- 36 Casella G. Refining binomial confidence intervals. *Can J Stat* 1986; **14**: 113–29.
- 37 Blyth CR, Still HA. Binomial confidence intervals. *J Am Stat Assoc* 1983; **78**: 108–16.