


Hereditary phosphate balance disorders in Norwegian children

Silje Hjorth Rafaelsen



Dissertation for the degree of philosophiae doctor (PhD)
at the University of Bergen

2016

Dissertation date: 03.05.16

© Copyright Silje Hjorth Rafaelsen

The material in this publication is protected by copyright law.

Year: 2016

Title: Hereditary phosphate balance disorders in Norwegian children

Author: Silje Hjorth Rafaelsen

Print: AiT Bjerch AS / University of Bergen

Acknowledgements

First of all, I would like to thank all the patients and their families for participating in our study. Without their contribution the study would not have been possible.

The initial idea of the study came from my principal supervisor professor Robert Bjercknes, who works with this patient group in his clinical practice at Haukeland University Hospital, and who has connection throughout the community of Norwegian pediatricians. I am in great depth to Robert for inviting me to work with this study, and for his never ending patience during periods of slow progression. He has been essential for conducting this study, and has given me invaluable academic and personal support.

The planning of the study was made in collaboration with professor Bjercknes, professor Helge Ræder and professor Stefan Johansson. Specifically Helge has contributed to linking concepts of clinical studies and genetic studies, and also reminded me of the necessity of perseverance during my time working in the laboratory. Also, Helge's international connections led to the collaboration with Thomas Oliver Carpenter, Consultant Pediatrician and Professor at the Yale University School of Medicine, USA.

I thank Stefan Johansson for introducing me to the Center for Medical Genetics and Molecular Medicine, Haukeland University Hospital, where I had my laboratory work. He has been invaluable during the planning and conduction of the genetic studies in this project. I would also like to thank professor Per Knappskog and professor Torunn Fiskerstrand from the Center for Medical Genetics and Molecular Medicine, Haukeland University Hospital, for accepting the invitation to collaborate in this study.

I thank Jorunn Bringsli for introducing me to and training me in practical laboratory work, specifically all steps of Sanger sequencing and computer procession of the

results. I would also like to thank Guri Matre and Hilde Eldevik Rusaas for practical support and conduction of analyses.

Liv Aasmul has been essential in receiving and storing of all blood samples and clinical forms, and has also isolated DNA for all genetic analyses.

There are also several collaborators at hospitals throughout Norway, who have contributed by including patients and supplying clinical information. I thus want to thank them for their time and cooperation: Jon Bland, Consultant Pediatrician, Stavanger University Hospital; Anne Grethe Myhre, Leif Brunvand, Cathrine Alsaker Heier and Martin Heier, Consultant Pediatricians, Oslo University Hospital, Oslo; Torstein B. Rø, and Gunhild Møllerløyken, Consultant Pediatricians, St. Olavs Hospital, Trondheim; Ketil Mevold and Dag Veimo, Consultant Pediatricians and Anne Kristine Fagerheim, Consultant Nephrologist, Nordland Hospital, Bodø; Eli Brevig Consultant Endocrinologist, Innlandet Hospital Trust, Kongsvinger,.

I would also like to thank my colleagues at Voss hospital for showing interest for my study.

Last, but not least I would like to than my family for all support during my work, and especially my son Sverre, for all his patience and for reminding me what really counts in life.

Abstract

Background: Hereditary hypophosphatemia (HH) is a group of diseases characterized by monogenic hypophosphatemia due to reduced tubular maximum reabsorption of phosphate per glomerular filtration rate (TmP/GFR). This group includes X-linked dominant hypophosphatemic rickets (XLHR), caused by deactivating mutations in *PHEX*, autosomal dominant HR (ADHR), caused by activating mutations in *FGF23* and autosomal recessive HR, caused by deactivating mutation in *DMP1* (ARHR1) or *ENPP1* (ARHR2), and all these conditions involve elevated levels of the phosphate regulating, bone-derived hormone FGF23. Combined therapy with phosphate and active vitamin D partially corrects rickets, osteomalacia and suboptimal growth in children, but the therapeutic window is narrow, with a risk of nephrocalcinosis and hyperparathyroidism.

Hyperphosphatemic familial tumoral calcinosis (HFTC) and hyperphosphatemia hyperostosis syndrome (HHS) are caused by reduced levels of FGF23, due to deactivating mutations in *FGF23*, *GALNT3* or *KL*. Phosphate lowering treatment only partially reduces the abnormal soft tissue calcifications characteristic for these conditions.

Aims: To study hereditary disorders of phosphate metabolism in Norwegian patients, including the prevalence, phenotype and outcome of hereditary hypophosphatemia (HH) in the Norwegian pediatric population. Moreover, to study the genetic causes, including mutations in novel genes, associated with hypo- or hyperphosphatemia in Norwegian families.

Materials and methods: Patients were recruited by contact with all pediatric and medical departments in Norwegian hospitals during the years 2009-2015. Inclusion criteria for HH were hypophosphatemia and reduced TmP/GFR, and for HFTC/HHS hyperphosphatemia and increased TmP/GFR. Clinical data were retrieved from the patients' medical records. If the genotype was not already known, we performed Sanger sequencing of the *PHEX*, *FGF23*, *DMP1*, *ENPP1*, *GALNT3*, *KL* and

FAM20C genes. Whole exome sequencing was performed in three families where the genetic screening was negative.

Results: In Paper I we found a prevalence of genetically verified XLHR in Norway of 1 in 60.000. *PHEX* mutations were confirmed in 21 of the 28 included patients with HH, *FAM20C* mutations in two, and *SLC34A3* mutations in one patient. We found a trend for XLHR males to be more growth restricted and more often having dental involvement than females. In XLHR children, 10 of 15 patients had elevated PTH before the start of treatment and nine of 21 had low-grade nephrocalcinosis during treatment with phosphate and alfacalcidol, but only one case of transiently compromised renal function.

In Paper II we identified novel combined heterozygous mutations in *FAM20C* in two male siblings with hyperphosphatemia and reduced TmP/GFR, and elevated levels of FGF23. They did not demonstrate rickets, but rather generalized osteosclerosis and intracerebral calcifications.

In Paper III we identified a novel homozygous mutation in *GALNT3* in two siblings with HFTC and HHS. We showed the phenotypic diversity within the same family, and the fluctuation of symptoms over time. We also reviewed all cases of genetically verified HFTC and HHS, and showed that the combined HFTC/HHS phenotype is more common than previously recognized.

Conclusions: We have shown that the prevalence of XLHR in Norwegian children seems to be lower than reported in other cohorts. In XLHR children, males seem to have a more severe mineralization phenotype than females. Adequate treatment partially corrects rickets, skeletal axis deviation and longitudinal growth, but gives an increased risk of low-grade nephrocalcinosis, although without renal dysfunction. We have also identified two patients with *FAM20C* mutations and shown that they have pathological serum levels of FGF23, and that *FAM20C* mutations are associated with autosomal recessive FGF23-dependent hereditary hypophosphatemia. Finally, we have brought further support to theory that HFTC and HHS are two syndromes in a clinical spectrum of FGF23 related hereditary hyperphosphatemias.

Contents

Abstract	5
Contents	7
List of publications	9
Abbreviations	10
1. Introduction	12
1.1 Historical perspective	12
1.2 Phosphate homeostasis	13
1.2.1 Phosphate in the body	13
1.2.2 Phosphate transporters	14
1.3 Regulation of phosphate	16
1.3.1 Parathyroid hormone.....	16
1.3.2 Vitamin D.....	19
1.3.3 FGF23	19
1.4 Bone metabolism.....	21
1.5 Hereditary hypophosphatemia	26
1.5.1 Hereditary hypophosphatemic rickets	26
1.5.2 Treatment and follow up.....	34
1.6 Hereditary hyperphosphatemia	37
1.6.1 Genetics in hereditary hyperphosphatemia.....	37
1.6.2 Clinical features in hereditary hyperphosphatemia	38
1.6.3 Treatment and follow-up	39
1.6.4 Complications and prognosis	40
1.7 Acquired disorders with elevated FGF23	40
2. Aims	42
3. Materials and methods	43
3.1 Patient population.....	43
3.2 Review of medical history.....	44
3.3 Genetic analysis	45
3.3.1 Sanger sequencing	46
3.3.2 Further genetic analyses	46

3.4	Statistics.....	47
3.5	Ethics and approvals.....	47
4.	Results.....	48
4.1.1	Overview of papers I-III.....	48
5.	Discussion	51
5.1	Methodological issues.....	51
5.1.1	Study design	51
5.1.2	Ethical considerations in genetic analyses	52
5.2	Discussion of results	52
5.2.1	Hereditary hypophosphatemia in Norwegian children – Paper I.....	52
5.2.2	<i>FAM20C</i> : novel association with hereditary FGF23 dependent hypophosphatemia – Paper II.....	61
5.2.3	Hereditary hyperphosphatemia illustrating the janus face of genes involved in phosphate regulation – Paper III	67
5.2.4	FGF23 dysregulation – new knowledge on pathophysiological mechanisms in mineralization	70
6.	Conclusions	72
7.	Future perspectives	73
8.	References	75

Appendix

Papers I- III

List of publications

1 Rafaelsen S, Johansson S, Raeder H, Bjerknes R. Hereditary hypophosphatemia in Norway; a retrospective population-based study of genotypes, phenotypes and treatment complications. *Eur J Endocrinol.* 2016;174(2):125-36.

2 Rafaelsen SH, Raeder H, Fagerheim AK, Knappskog P, Carpenter TO, Johansson S, Bjerknes R. Exome sequencing reveals *FAM20C* mutations associated with fibroblast growth factor 23-related hypophosphatemia, dental anomalies, and ectopic calcification. *J Bone Miner Res.* 2013;28(6):1378-85.

3 Rafaelsen S, Johansson S, Raeder H, Bjerknes R. Long-term clinical outcome and phenotypic variability in hyperphosphatemic familial tumoral calcinosis and hyperphosphatemic hyperostosis syndrome caused by a novel *GALNT3* mutation; case report and review of the literature. *BMC Genet.* 2014;15:98.

Abbreviations

1,25(OH) ₂ D:	1,25-dihydroxyvitamin D
25OHD:	25-hydroxyvitamin D
ADHR:	Autosomal dominant hypophosphatemic rickets
ADP:	Adenosine diphosphate
ALP:	Alkaline phosphatase
ARHR:	Autosomal recessive hypophosphatemic rickets
ASARM:	Acidic serine aspartate-rich MEPE-associated motif
ATP:	Adenosine triphosphate
BSP:	Bone sialoprotein
Ca:	Calcium
Ca/Crea-ratio:	Calcium/creatinine ratio
CaSR:	Calcium sensing receptor
CRF:	Chronic renal failure.
DMP1:	Dentin matrix protein 1
DPP:	Dentin phosphoprotein
DSP:	Dentin sialoprotein
DSPP:	Dentin sialophosphoprotein
ECM:	Extracellular matrix
ENPP1:	Ectonucleotide pyrophosphatase phosphodiesterase 1
ERK:	Extracellular signal-regulated kinase
FAM20C:	Family with sequence similarity 20, member C
FGF23:	Fibroblast growth factor 23
FGFR:	Fibroblast growth factor receptor
GACI:	Generalized arterial calcifications in infancy
GalNacT3:	UDP-N-Acetyl- α -D-Galactosamin:Polypeptide N-Acetylgalactosaminyltransferase 3
GEF-CK:	Golgi enriched fraction Casein kinase
HFTC:	Hyperphosphatemic familial tumoral calcinosis
HH:	Hereditary hypophosphatemia

HHRH:	Hereditary hypophosphatemic rickets with hypercalcuria
HHS:	Hyperphosphatemic hyperostosis syndrome
HPT:	Hyperparathyroidism
HR:	Hypophosphatemic rickets
KO:	Knockout
MEPE:	Matrix extracellular phosphoglycoprotein
MLPA:	Multiplex ligation-dependent probe amplification
MMP:	Matrix metalloproteinase
NaPi-IIa/c:	Sodium-Phosphate cotransporter type IIa/IIc
NHERF:	Sodium-Hydrogen exchanger regulatory factor
PHEX:	Phosphate regulating gene with homologies to endopeptidases on the X-chromosome.
OMIM:	Online Mendelian Inheritance in Man
OGD:	Osteoglophonic dysplasia
OPN:	Osteopontin
PTH:	Parathyroid hormone
PO ₄ :	Phosphate
SIBLING:	Small integrin-binding ligand, N-linked glycoprotein
SLC:	Solute carrier
SNP:	Single nucleotide polymorphism
SPC:	Subtilisin-like proprotein convertase
TGF:	Transforming growth factor
TIO:	Tumor induced osteomalacia
TmP/GFR:	Tubular maximum reabsorption of phosphate per glomerular filtration rate
TRP:	Tubular reabsorption of phosphate
TRPV:	Transient receptor potential cation channel, subfamily V
XLHR:	X-linked hypophosphatemic rickets

1. Introduction

X-linked hypophosphatemic rickets was first described by Fuller Albright in 1937, as rickets resistant to vitamin D therapy (1). Since then, the knowledge on the group of diseases known as hypophosphatemic rickets, as well as details in the regulation of phosphate mineral homeostasis, has greatly advanced.

1.1 Historical perspective

Rickets, a bone deforming disorder seen in children, emerged as a prevalent condition during the industrial revolution in Northern Europe in the 1600s, and was first described by Daniel Whistler in the year 1645 (2). The word “rickets” is of uncertain origin, but might come from the English word “wrick”, or the Swedish word “ricka” meaning to sway (3). It might also come from the Greek word meaning “in or of the spine”. The link between rickets and the lack of sun exposure to skin was described in 1822; the high degree of air pollution and high buildings in industrialized cities, combined with a vitamin D deficient diet, lead to evidence of rickets in 80-90 % of children in Northern Europe and Northeastern United states around year 1900 (4).

The introduction of vitamin D supplements and vitamin D fortified milk greatly reduced the prevalence of this condition. In Norway, consumption of cod-liver oil has traditionally been an important dietary source of vitamin D, leading to a relatively lower prevalence of vitamin D deficiency; A survey from 1931 showed that 50 % of children below two years of age in the northernmost county of Norway had clinical signs of rickets (5).

Rickets resistant to high doses of vitamin D was first described by Albright in 1937, and the familial occurrence of Vitamin D-resistant rickets (VDRR) was first recognized by Christensen in 1940 (6). An X-linked inheritance pattern was proposed by Winters et al. in 1958 (7), but later also autosomal dominant (8) and autosomal

recessive (9, 10) inheritance patterns were recognized. In 1976 Eicher et al. constructed the Hyp mouse, the murine model of X-linked hypophosphatemic rickets (XLHR) (11), and ten years later the disease was mapped to the short arm of chromosome X in humans (12). Since then, the knowledge on pathophysiology and genetic diversity has increased significantly.

1.2 Phosphate homeostasis

Until recently the regulation of body phosphorus was thought to be secondary to the regulation of serum-calcium (S-Ca). However, the identification of fibroblast growth factor 23 (FGF23) as a specific phosphate regulating substance, a phosphatonin, has contributed to increased understanding of phosphate regulation in health and disease.

1.2.1 Phosphate in the body

The adult human body contains about 700-900 g of phosphorus, of which 85 % is contained in bone tissue as hydroxyapatite [$\text{Ca}_5(\text{PO}_4)_3(\text{OH})$] (13). About 14 % is localized intracellularly as organic phosphate compounds serving important functions in cellular energy metabolism (adenosine triphosphate and adenosine diphosphate; ATP and ADP), as genetic material (DNA and RNA), in intracellular signaling cascades (e.g. cyclic adenosine monophosphate; cAMP) and as cellular structures such as phospholipids of the cellular membrane. Intracellular enzymatic activity and cell signaling are also regulated by phosphorylation and dephosphorylation. Inorganic phosphate ($\text{H}_2\text{PO}_4^-/\text{HPO}_4^{2-}$) is also the most important intracellular anion with an intracellular concentration of about 100 mmol/L, and serves as a buffer. Less than 1 % of total body phosphorus is found in extracellular fluids as phospholipids, phosphoesters and serum inorganic phosphate (S-P) (13). The concentration of S-P is approximately 1 mmol/L, depending on age and sex (Table 4, in the Appendix), and

the higher S-P in children is probably a physiological adaptation to ensure availability of phosphorus for mineralization of growing bone (14).

Phosphate is abundant in most foods, and the average adult ingests about 1 g of phosphate per day, of which 90 % is absorbed in the small intestine. The elimination of phosphorus from the body is through the kidneys. The filtered load of phosphorus is about 6 g per day, and most is reabsorbed in the proximal tubules. In steady state, the net excretion in urine equals intestinal absorption (13).

1.2.2 Phosphate transporters

The transportation of phosphate across cell membranes occurs through mainly two families of sodium phosphate cotransporters, type II and III sodium phosphate cotransporters (NaPi-II and NaPi-III) (15), encoded by the *solute carrier 34 (SLC34)* (16) and *SLC20* genes (17), respectively. Both families belong to the SLC superfamily of membrane transporters (18), and uses the inward electrochemical gradient for Na^+ , generated by the Na/K-ATPase, for secondary-active transport of phosphate. The *SLC17* (type I Na/Pi cotransporter) family was earlier thought to be important for phosphate membrane transport, but these transporters are not strictly Na/Pi cotransporters, and are implicated in transport of organic anions and amino acids (19).

SLC34/Type II Na/Pi cotransporters

The type II sodium phosphate cotransporter family includes three members, NaPi-IIa, NaPi-IIb and NaPi-IIc, encoded by the *SLC34A1*, *SLC34A2* and *SLC34A3* genes respectively. NaPi-IIa and NaPi-IIc are located in the apical membrane of kidney proximal tubule cells (20), and the cotransport of Na^+ and HPO_4^{2-} is coupled to the energy dependent Na/K-ATPase on the basolateral cell surface, generating an inward gradient for Na^+ , driving the transport of Na and HPO_4^{2-} on the apical surface.

The final step in the regulation of phosphate reabsorption is by regulating the expression of NaPi-IIa and NaPi-IIc in the brush border membrane in the proximal tubuli. Both parathyroid hormone (PTH) and FGF23 act on receptors on the basolateral cell surface, inducing intracellular signaling cascades leading to increased endocytosis and lysosomal degradation of the transporters (21). This decreases reabsorption of Pi from filtered urine, whereas hypophosphatemia and 1,25 dihydroxyvitamin D ($1,25(\text{OH})_2\text{D}$) stimulates phosphate reabsorption (21). There also seems to be a directly regulating effect of dietary Pi on Na/Pi cotransport in proximal tubules; feeding rats a high phosphate diet lead to internalization of NaPi-IIa and IIc from the renal brush border membrane within a few hours (22).

The NaPi-IIb is located to the apical surface of enterocytes of the small intestine, as well as in cells of the lung, liver, testes and colon (23). It is the most important transport system for active Pi absorption in the small intestine (24), and is up-regulated in response to a low-phosphate diet and $1,25(\text{OH})_2\text{D}$ (25). Homozygous mutations in *SLC34A2* have been associated with pulmonary alveolar microlithiasis (26, 27).

SLC20/Type III Na/Pi cotransporters

The type III sodium phosphate cotransporter family includes two members, Pi transporter 1 (PiT-1) and PiT-2, encoded by the *SLC20A1* and *SLC34A2* genes, respectively (17). They were first recognized as the retroviral receptors Glvr-1 and Ram-1, but were later shown to be Na/Pi cotransporters with a wide tissue distribution (17, 28), and they probably serve housekeeping functions of phosphate metabolism (18). Importantly, PiT-1 seems to play a role in transportation of inorganic phosphate into osteoblasts (29), and may thus serve important functions in the mineralization process. PiT-2 has been localized to the proximal tubule brush border membrane in rats, with the expression level regulated by dietary phosphate load (30). Thus, PiT-2 could explain the residual phosphate reabsorption in the proximal tubule of NaPi-IIa and NaPi-IIc double knockout mice (31), but the functional importance of PiT-2 in phosphate reabsorption remains unclear (18).

1.3 Regulation of phosphate

The important functions of phosphate in cell physiology discussed above, implies tight regulation of phosphate homeostasis. Short term regulation of serum phosphate is achieved by fast shifts of phosphate in and out of cells, while long term regulation of serum- and body phosphate is a complex interplay between several hormones and factors, including parathyroid hormone (PTH), $1,25(\text{OH})_2\text{D}$ and FGF23 (32). Proper mineralization of growing and remodeling bone is dependent on the availability of calcium and phosphorus, whereas to high levels of these to minerals in extracellular fluids poses a risk for ectopic calcifications. Calcium- and phosphorus regulation are therefore tightly coupled. However, in addition to the PTH/vitamin D-axis acting primarily to maintain normocalcemia (Figure 1), serum phosphate is regulated specifically by the FGF23 dependent bone/kidney axis (Figure 2).

1.3.1 Parathyroid hormone

PTH is a peptide hormone synthesized in and secreted by the chief cells of the four parathyroid glands to restore normocalcemia in response to small decrements in serum ionized calcium (33). Reduced binding of calcium to the seven-transmembrane G-coupled calcium sensing receptor (CaSR) located on the cell surface, increases PTH production and release, while binding of calcium to the CaSR leads to inhibition of PTH secretion. PTH promotes bone resorption and mobilizes calcium and phosphorus from bone, and also directly increases reabsorption of calcium from filtered urine through the TRPV5 (34). By stimulating the renal $1-\alpha$ -hydroxylase to increase conversion of 25OHD to $1,25(\text{OH})_2\text{D}$, PTH indirectly increase gastrointestinal absorption of calcium, and to a lesser degree phosphate (33).

PTH secretion is also regulated by several other factors involved in mineral metabolism. Reduced levels of $1,25(\text{OH})_2\text{D}$, via reduced intestinal calcium absorption, lead to increased synthesis and secretion of PTH, while increased levels of $1,25(\text{OH})_2\text{D}$ have a direct inhibitory effect on transcription of the *PTH* gene (33)

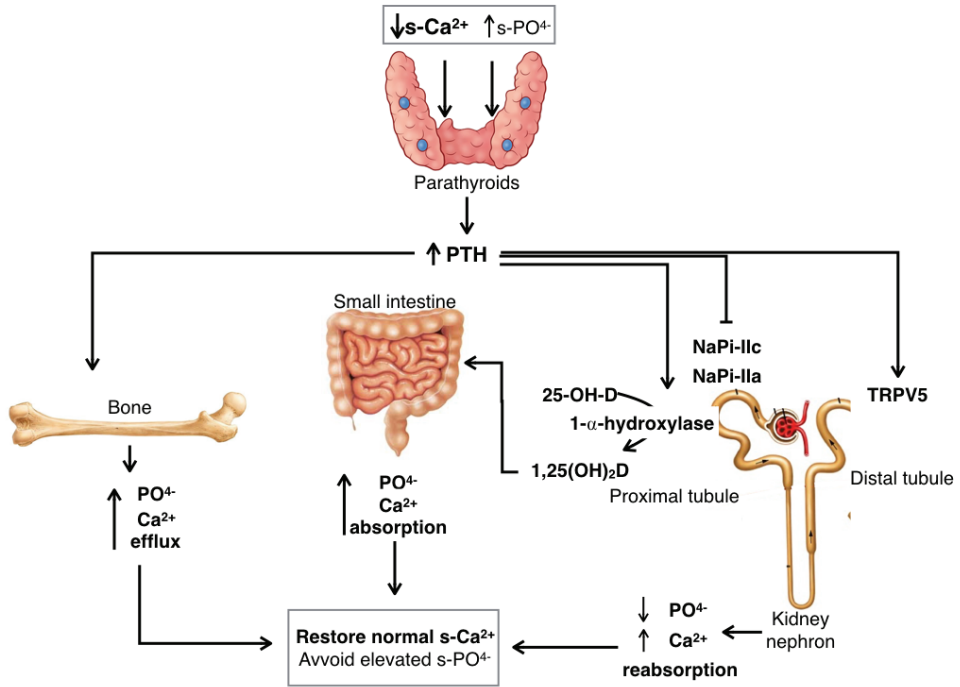


Figure 1 The parathyroid acts as a calciostat.

The primary stimulus for PTH secretion by the parathyroid gland is a reduced serum level of free ionized calcium (33). PTH act on bone to cause resorption with efflux of calcium and phosphorus, and act on the kidney to increase the activity of the alpha-hydroxylase, suppress phosphate reabsorption through the NaPi-IIa/c and increase the reabsorption of calcium through the TRPV5 (34). Increased level of $1,25(\text{OH})_2\text{D}$ leads to increased absorption of calcium and phosphorus from the gastrointestinal tract. The net result is to restore normocalcemia, while simultaneously avoiding hyperphosphatemia. The elevated level of S-Ca increases the activity of the CaSR, reducing PTH synthesis and secretion (33), closing the negative feedback loop.

The effect of PTH on body phosphate homeostasis is opposite of the effect on calcium; PTH down-regulates the expression of the NaPi-IIa and IIc cotransporters in the renal proximal tubules (35, 36), reducing renal reabsorption of phosphate, probably to counteract an elevation in the serum calcium-phosphate product and the risk of ectopic calcifications. Conversely, increased serum phosphate levels stimulate production and secretion of PTH, both due to phosphate binding of free calcium to decrease serum ionized calcium (37), as well as by a direct of phosphate on the

parathyroid gland (38). Secondary hyperparathyroidism is a well-known complication of chronic renal failure with chronically elevated serum phosphate levels.

The effect of PTH on bone tissue is dual; continuously elevated PTH has a catabolic effect on bone, while pulsatile elevation of PTH actually has anabolic effect (39).

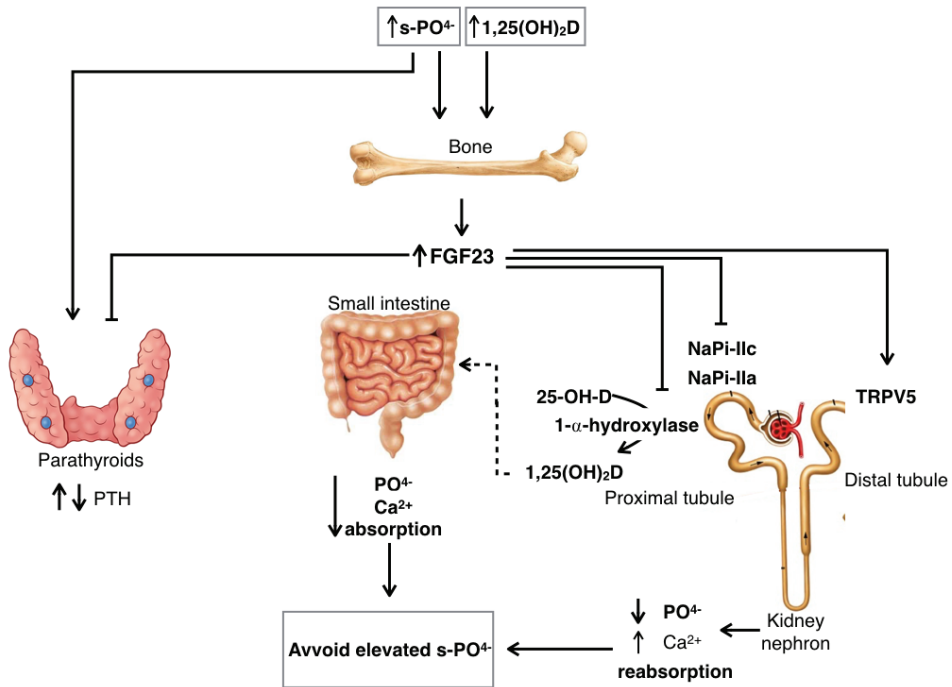


Figure 2 Bone acts as a phosphostat.

Secretion of FGF23 is stimulated by elevated levels of serum phosphate and $1,25(\text{OH})_2\text{D}$ (40). FGF23 binds to the $\text{FGFR1}/\alpha\text{-klotho}$ receptor complex in the proximal tubule of the kidney, leading to down-regulation of phosphate transporters NaPi-IIa and NaPi-IIc and inhibition of the $\alpha\text{-hydroxylase}$ (41). FGF23 also binds to $\text{FGFR1}/\alpha\text{-klotho}$ receptor in the distal convoluted tubule (42) to increase calcium reabsorption through the TRPV5 (43). The reduced levels of $1,25(\text{OH})_2\text{D}$ leads to reduced absorption of calcium and phosphorus in the small intestine.

1.3.2 Vitamin D

Vitamin D in its active form, 1,25(OH)₂D is an important intracellular hormone with a wide range of physiological effects, and vitamin D deficiency and insufficiency is thought to have implications for a wide range of diseases (44). Historically, however, vitamin D deficiency has been linked primarily to rickets, as 1,25(OH)₂D is important for absorption of calcium, and to a lesser degree phosphorus, from the small intestine.

In the skin, UVB irradiation converts 7-dehydrocholesterol to cholecalciferol and further to provitamin D. In the liver, provitamin D is hydroxylated in the 25-position to 25OHD (calcidiol) (44). However, the active metabolite of vitamin D is the 1,25(OH)₂D (calcitriol), which is produced by hydroxylation in the 1-position by 1- α -hydroxylase (CYP27B1) in the kidney proximal tubule cells.

1,25(OH)₂D acts intracellularly, and binds to Vitamin D responsive elements (VDRs) involved in gene regulation. In mineral metabolism, the main effect of 1,25(OH)₂D is to increase the absorption of Ca²⁺ (45) and to a lesser extent also PO₄³⁻ (25) in the small intestine. In vitamin D deficiency, however, there is initially a low serum calcium level while serum phosphate level remains normal. However, this hypocalcaemia leads to increased production and secretion of PTH, which stimulates the conversion of 25OHD to 1,25(OH)₂D and also inhibits renal reabsorption of phosphate. Thus, vitamin D deficiency negatively effects bone metabolism, most importantly through reducing availability of calcium and phosphate for skeletal mineralization (46), and through the negative effect of chronically elevated PTH on skeletal metabolism.

1.3.3 FGF23

FGF23 has emerged as a key hormone in the bone/kidney-axis of phosphate regulation, and the knowledge on the physiological and pathophysiological mechanisms involving FGF23 is rapidly increasing.

The 22 members of the human fibroblast growth factor (*FGF*) gene family can be categorized according to their mode of function, as intracrine/intracellular, paracrine/canonical and endocrine (47). The intracellular FGFs in the FGF11/12/13/14 subfamily, have no signal peptide sequence, and are therefore not secreted, but work intracellularly on voltage gated sodium channels to regulate the electrical excitability of neurons and possibly other cell types (48). The paracrine FGFs comprise the FGF1/2/5, FGF3/4/6, FGF8/17/18, FGF7/10/22 and FGF9/16/20 subfamilies. They harbor a signal peptide, and are thus exported from the cell, but also have binding sites for heparin and interact with heparin-like molecules in the extracellular environment, and do not enter systemic circulation (47). The paracrine FGFs are important in embryogenesis, as demonstrated in human diseases caused by loss-of-function mutations in some of these FGFs (49-51).

The endocrine FGF19, FGF21 and FGF23, also have an n-terminal signal peptide, but their affinity for heparin-like molecules is very low, and they therefore escape the extracellular matrix and enter systemic circulation (52). The fibroblast growth factor receptor (*FGFR*) gene family comprises four genes encoding FGFR1-4, and the actions of the endocrine FGFs are mediated mainly through binding FGFR1 and FGFR4, with α - and β -klotho, respectively, as obligate cofactors to increase receptor binding affinity (52).

FGF23 was first identified as a secreted protein expressed in the mouse brain (53), and mutations in the human *FGF23* gene were found to be associated with autosomal dominant hypophosphatemic rickets (ADHR) (54). It very soon became clear that FGF23 is the factor responsible for the phosphate wasting phenotype seen in tumor induced osteomalacia (TIO) (55), and that in ADHR, mutations altering the arginine residues in position 176 or 179 of the furin protease cleavage site, R¹⁷⁶XXR¹⁷⁹ in exon 3, make the protein resistant to enzymatic break down (56). Osteoblasts are the main source of FGF23 production (57), which is stimulated by increased levels of serum phosphate and 1,25(OH)₂D (40).

FGF23 mediate effects through binding to FGFR1c with α -klotho as an obligate cofactor (58). FGF23 may also bind to FGFR3 and FGF4 (59), but the functional significance of this binding is unknown (60). The organ and cell specificity of FGF23 action is determined by the tissue expression of FGFR1c and α -klotho. The most well defined actions of FGF23 are in the kidney; FGF23 binds to the FGFR1c/ α -klotho receptor complex expressed on the basolateral surface of proximal tubuli cells, activating the extracellular signal-regulated kinase 1/2 (ERK1/2) – serum/glucocorticoid-regulated kinase 1 (SGK1) intracellular signaling pathway (61). This leads to phosphorylation of Na⁺/H⁺ exchange regulatory factor (NHERF)-1 (61), a scaffolding protein responsible for binding NaPi-IIa and localizing the transporter on the luminal surface of the proximal tubuli cells (62). Phosphorylated NHERF-1 dissociates from the luminal cell membrane, leading to internalization and thus reduced expression of the NaPi-IIa on the luminal surface of the proximal tubuli cells (61). The FGF23/FGFR1c/ α -klotho complex also leads to down regulation of the kidney 1- α -hydroxylase (Cyp27b1) responsible for converting 25OHD into its active metabolite 1,25(OH)₂D (41), and up regulation of the 24-hydroxylase (CYP24A1) responsible for conversion of 25OHD to the inactive metabolite 24,25(OH)₂D (63).

1.4 Bone metabolism

Development

During embryogenesis the skeletal system develops mostly from mesodermal cells, but the facial skeleton is derived from neural crest cells of the embryo. The cells destined for skeletal development differentiate into fibroblasts, chondroblasts or osteoblasts. Bone can develop through two different processes. Intramembranous ossification is the process where mesenchyme in the dermis develops directly into bone tissue, as in the flat bones of the skull. Most of the skeleton, however, develops through endochondral ossification. In this process a cartilage model of the bone is first

laid down, with secondary apoptosis of chondrocytes and replacement by bone forming osteoblasts (64).

Growth

Skeletal growth occurs at the growth plates, physes, at the distal and proximal ends of long bones (Figure 3). As illustrated in Figure 4, the chondroblasts resting in the germinal zone will start proliferate and arrange in columns. Differentiation into mature chondrocytes with production of cartilage matrix occurs in this zone. In the hypertrophic zone, the chondrocytes fully mature and grow in size, increasing the length of the cartilage. However, as the chondrocyte hypertrophies the cartilage matrix diminishes and calcifies, resulting in chondrocyte apoptosis in the zone of enchondral ossification. Capillaries and osteoprogenitor cells invade the lacunae surrounding the apoptotic chondrocytes. Osteoblasts differentiate and lie down osteoid on the trabeculae of remaining cartilaginous matrix (65). As the bone grows in length, the bony trabeculae of the metaphysis are resorbed by osteoclasts, and the trabecular bone is substituted by lamellous, cortical bone of the diaphysis. In this way, the width of the metaphysis and epiphysis remains stable as the bone grows, while the diaphysis increases in length. Failure of apoptosis of the late hypertrophic chondrocytes of the physis leads to an expansion of the growth plate, seen clinically as the widening of the physis characteristic for rickets (66).

Remodeling

The hormonal changes associated with puberty make the growth plates mineralize, and longitudinal growth stops. However, bone is continuously renewed during life to accommodate the pattern of stress put on them, and also as a part of mineral metabolism, a process called remodeling. Remodeling is a cyclic process that takes place in small units. In the remodeling cycle, osteoclasts are activated and start resorption of old bone, before osteoblasts starts formation of new bone (67).

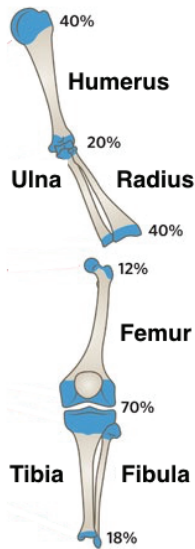


Figure 3 Growth plates

The figure gives an overview of the growth plates of the upper and lower limb, and their relative contribution to longitudinal growth (Based on figure from The Royal Children's Hospital Melbourne; <http://www.rch.org.au/fracture-education/remodelling/>).

Bone formation and mineralization

In the process of bone formation, the osteoblasts first synthesize new bone matrix, and then regulate matrix mineralization by releasing membrane bound vesicles containing calcium and phosphorus (68, 69). Bone matrix consists mainly of fibers of type I collagen arranged in a multiple layers with alternating orientation to increase bone strength. About 10 – 15 % of bone matrix consists of non-collagenous proteins, mostly osteoblast-derived, but also serum-derived. The non-collagenous proteins probably serve various functions in regulating bone mineralization, osteoblast- and osteoclast proliferation, differentiation and activity (70). Table 1 gives an overview of bone matrix proteins.

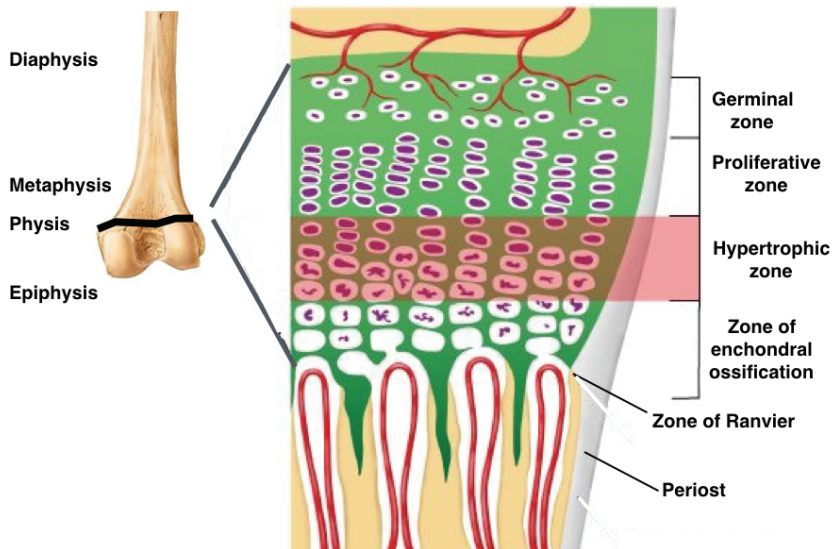


Figure 4 The growth plate

The figure gives a schematic overview of the growth plate. Chondroblasts rest in the germinal zone. In the proliferative zone, the chondrocytes arrange in columns, with surrounding cartilage matrix. In the hypertrophic zone, the chondrocytes mature and grow in size, increasing the length of the cartilage. However, as the chondrocyte hypertrophies the cartilage matrix diminishes and calcifies, resulting in chondrocyte apoptosis in the zone of enchondral ossification. Capillaries and osteoprogenitor cells invade the lacunae surrounding the apoptotic chondrocytes. Osteoblasts differentiate and lie down osteoid on the trabeculae of remaining cartilaginous matrix. Illustration adapted from <http://www.uptodate.com>.

Minerals, mainly hydroxyapatite, make up 50-70 % of bone (67). The solubility of hydroxyapatite makes bone resorption an important source of serum calcium and phosphate in the mineral homeostasis. Osteoblasts synthesize matrix extracellular vesicles in which the concentration of calcium and phosphate is much higher than in extracellular fluid (68). Proteins, phospholipids, calcium and phosphate in the vesicles complex to form a mineralization nucleation core, on which further growth of hydroxyapatite crystals can take place. The vesicles are deposited in the extracellular matrix, at the ends of the collagen fibrils. DMP1 and bone sialoprotein are known to be important for the development of the nucleation core of the matrix extracellular vesicles, and ALP, osteocalcin and osteopontin are also involved in regulation of matrix mineralization (67).

Table 1 Bone matrix proteins

Protein families	Proteins	Function
Collagen	Type I collagen	- Primary ECM component of bone tissue - Nucleation site for mineral - Influences post-yield behavior - Promotes osteogenesis - Osteoclast binding and degradation
	Type III collagen	- Promotes bone formation
Matricellular proteins	TSP 1	- Cell attachment
	TSP 2	- Cell attachment
	SPARC	- Collagen fibrillogenesis
	R-spondins	- Osteoblast regulating
SIBLING	BSP	- Promotes matrix mineralization
	DMP1	- Robust osteocyte marker - Regulates phosphate metabolism - Involved in osteocyte function
	MEPE	- Regulates phosphate metabolism
	Osteopontin	- Inhibits bone mineralization - Promotes bone resorption
	Osteocalcin	- Robust marker of osteoblast differentiation - Inhibits mineralization
Carboxylated proteins	MGP	- Inhibits mineralization
	Periostin	- Regulates SOST - Influences tenascin-C and fibronectin
SLRP	Asporin	- Promotes mineralization
	Biglycan	- Decreases active TGF-beta availability - Promotes normal collagen fibrillogenesis
	Decorin	- Decreases active TGF-beta availability - Promotes normal collagen fibrillogenesis
	Keratocan	- Regulates collagen fibrillogenesis - Regulates mineralization
MMP	MMP2	- ECM degradation for lacunar-canalicular network
	MMP14	- Differentiation of osteoblasts

Adapted from (70). Abbreviations: ECM = extracellular matrix; TSP = Thrombospondin; SPARC = secreted protein acidic and rich in cysteine; SIBLING = small integrin-binding ligand n-linked glycoprotein; BSP = bone sialoprotein; DMP1 = dentin matrix protein 1; MEPE = matrix extracellular phosphoglycoprotein; SOST = gene encoding Sclerostin; SLRP = small leucine rich proteoglycans; TGF = transforming growth factor; MMP = matrix metalloproteinase.

Defective mineralization; rickets and osteomalacia

Rickets is a disease of childhood, with defective mineralization of bone matrix at the growth plate, leading to skeletal growth disturbance. Inadequate mineralization of newly formed osteoid in bone remodeling, leads to softening of bones, osteomalacia, in both children and adults (66). Hypophosphatemia in the environment of the hypertrophic chondrocytes at the growth plate is the common denominator of all rickets (66). Hypophosphatemia inhibits apoptosis of hypertrophic chondrocytes. The growth plate will expand because of hypertrophy, and fail to mineralize. At the same time, there is osteomalacia, or failure to mineralize newly formed osteoid in the continuously remodeling skeleton. In children there will be both rickets and osteomalacia, while after closure of the epiphyses, there will only be osteomalacia (66).

1.5 Hereditary hypophosphatemia

Hereditary hypophosphatemia (HH) refers to a group of monogenic disorders characterized by hypophosphatemia caused by reduced tubular maximum reabsorption of phosphate per glomerular filtration rate. Historically, these conditions have been referred to as hypophosphatemic rickets. However, it has now become clear, that this group of disorders includes several disorders with similar pathophysiology, with or without rickets.

1.5.1 Hereditary hypophosphatemic rickets

X-linked hypophosphatemic rickets (XLHR) was first described as rickets resistant to vitamin D therapy (1). Since then, the discovery that mutation in several genes are associated with HR has given new insight into phosphate metabolism and the group of diseases known as hypophosphatemic rickets.

X-linked hypophosphatemic rickets

X-linked hypophosphatemic rickets (XLHR) is the most common variant of HR, with a reported prevalence of 1 in 20,000 (71, 72). The gene responsible for XLHR was identified by positional cloning in 1995 (73); inactivating mutations in the *PHEX* gene (Phosphate-regulating endopeptidase homolog on the X-chromosome; OMIM *300550) causes this X-linked dominant condition. The *PHEX* gene consists of 22 exons with large intronic regions (74) and encodes a transmembrane protein of the type II integral membrane zinc-dependent endopeptidase family. The highest expression is found in mature osteoblasts and odontoblasts, but the gene is also expressed in the kidney. XLHR is associated with elevated levels of fibroblast growth factor-23 (FGF-23) (75-77), but FGF23 is not a substrate for PHEX, and the exact mechanism for PHEX mutations leading to elevated FGF23 levels is not known. The C-terminal end of the mineralized matrix small integrin-binding ligand n-linked glycoproteins (SIBLINGs) contains an acidic serine aspartate-rich MEPE-associated motif (ASARM) (78). It has been shown that free ASARM peptides in the phosphorylated form (pASARM), inhibits mineralization of bone matrix by binding hydroxyapatite (79). Normally pASARM is a substrate for PHEX (79), and this could explain the hypomineralization of bone and dentin in XLHR. The Hyp mouse is a KO model of XLHR, with phenotypic features including osteomalacia, growth defects, down regulation of the mural kidney sodium-phosphate cotransporter type 2 (NPT2), and increased levels of serum FGF23 (80).

To date, over 300 different mutations in the *PHEX* gene has been reported in XLHR (*PHEX* mutation database: <http://www.phexdb.mcgill.ca/>), and includes missense, nonsense, splice mutations, small insertions or deletions, as well as large deletions or insertions of parts of or multiple exons. The mutations also seem to be fairly evenly distributed all over the coding part of the gene, but pathogenic mutations in the 5'UTR (81) and 3'UTR (82), as well as in the introns of the gene, have been reported.

The clinical presentation in XLHR is highly variable; in pedigrees with affected parents, affected children are often diagnosed in infancy upon screening for

hypophosphatemia combined with a low TmP/GFR, before development of symptoms (83). However, as many cases of XLHR represent de novo mutations, children may present with short stature, delayed walking, bone pain, a waddling gait and varus of the lower extremities (84). In these cases radiological examination often shows rickets of the wrists, knees and ankles. Dental involvement is evident as spontaneous periapical abscesses, and dental examination shows high pulp horns, intraglobular dentin, and mineralization defects of dentin. The primary teeth are most commonly affected, whereas adequate treatment can improve mineralization of permanent teeth in some cases (85). Adolescents and adults may complain of bone pain, and some develop enthesopathies (ectopic calcification of tendons). In addition to the combination of hypophosphatemia and hyperphosphaturia, the blood tests before the onset of treatment show a serum level of alkaline phosphatase that is often raised in children (86), the level of $1,25(\text{OH})_2\text{D}$ is low or inappropriately normal given the hypophosphatemia, whereas the levels of serum intact PTH is normal or slightly elevated, even before the onset of therapy (87-89). Serum calcium and urine calcium/creatinine ratio are normal before the start of treatment.

Autosomal recessive hypophosphatemic rickets

Earlier, only mutations in the *DMP1* gene (dentin matrix acidic phosphoprotein 1) were associated with autosomal recessive hypophosphatemic rickets (ARHR). However, recent research has shown that ARHR can also be caused by mutations in the *ENPP1* (ectonucleotide pyrophosphatase/phosphodiesterase 1) (90, 91), and these conditions are now referred to as ARHR1 and ARHR2, respectively.

ARHR1

The *DMP1* gene (OMIM * 600980) was identified as the cause of ARHR1 in 2006 (10), and since then only a few homozygous or compound heterozygous mutations have been reported (9, 10, 92-97). *DMP1* consists of 6 exons on chromosome 4q21, is highly expressed in osteocytes, and is a member of the 'SIBLING' (small integrin binding ligand n-linked glycoprotein) family of non-collagenous extracellular matrix proteins involved in bone mineralization (98). The *Dmp1* knockout model displays

rickets and osteomalacia with isolated renal phosphate wasting associated with elevated FGF23 levels and normal U-Ca/creatinine ratio (U-Ca/Crea-ratio) (9). The phenotype is similar to that seen in XLHR, but ectopic calcifications are more typical for this condition, with hyperostosis of the long bones and the skull base as well as calcifications of the posterior longitudinal ligament as prevalent findings (10, 92, 93, 96).

ARHR2

ARHR2 is caused by recessive mutations in *ENPP1* (90, 91), which has also been identified as the cause of the lethal condition generalized arterial calcifications of infancy (GACI) (99, 100). Identical mutations can cause GACI or FGF23-dependent hypophosphatemic rickets in different subjects within the same family (91), while some subjects display a combined phenotype with both arterial calcifications and simultaneous renal phosphate loss (101), leading to an attenuated GACI phenotype with prolonged survival.

The *ENPP1* gene (OMIM*173335) is located on chromosome 6q22-q23 and comprises 23 exons. ENPP1 is a type II transmembrane glycoprotein responsible for hydrolyzation of extracellular adenosine triphosphate (ATP) to generate inorganic pyrophosphate (PPi) and adenosine monophosphate (AMP) (102). PPi is an inhibitor of hydroxyapatite crystal growth (Figure 7) (103), and also suppress chondrogenesis (104). Recessive mutations in *ENPP1* thus lead to lower levels of PPi and a pro-mineralizing state, which is reflected by GACI and by ossification of the posterior longitudinal ligament seen in humans with ARHR2 (105) and in *Enpp1* mutant mice (106). Mutations in *ENPP1* have also been associated with susceptibility to insulin resistance and obesity (107).

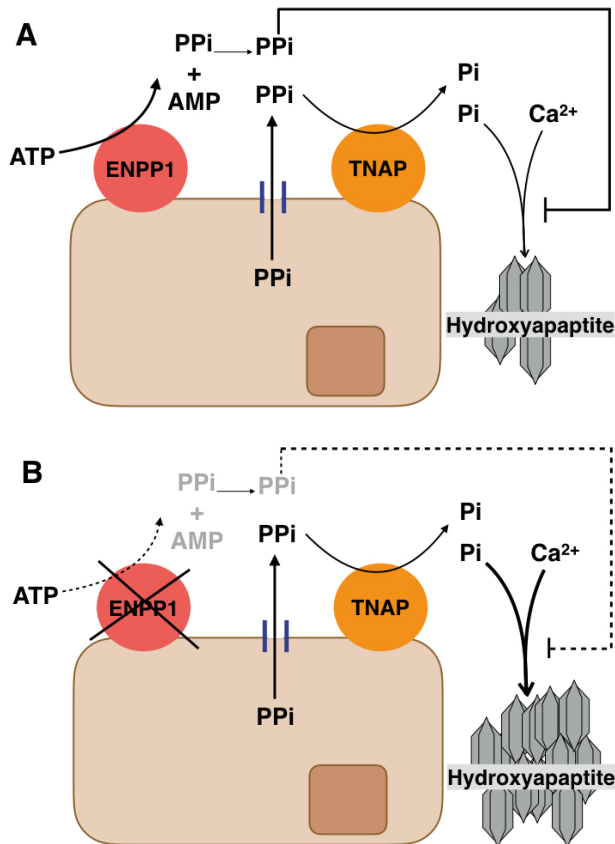


Figure 5 ENPP1 is involved in mineralization regulation.

A) In the physiological state ENPP1 hydrolyzes extracellular ATP to generate AMP and pyrophosphate (PPI). PPI is a substrate for the tissue nonspecific alkaline phosphatase (TNAP), which hydrolyses PPI to generate inorganic phosphate (Pi). Pi and calcium (Ca^{2+}) chelates in hydroxyapatite crystals, but PPI is an inhibitor of this mineralization process, and there is balanced mineralization. B) Mutations in *ENPP1* lead to lower levels of PPI and a pro-mineralizing state reflected by GACI and by ossification of the posterior longitudinal ligament seen in humans with ARHR2 and in the *Enpp1* mutant mice.

Autosomal dominant hypophosphatemic rickets

Autosomal dominant hypophosphatemic rickets (ADHR) was fully characterized as a separate entity in 1997 (108), and activating mutations in the *FGF23* gene (OMIM*605380) were later identified as the cause of this disorder (54). The *FGF23* gene is located on chromosome 12 and comprises 3 exons (Figure 6). Exon 3 harbors

a furin protease cleavage site, R¹⁷⁶XXR¹⁷⁹, and mutations altering the arginine residues in position 176 or 179 make the protein resistant to enzymatic break down (56). The resulting elevated levels of intact FGF23 (iFGF23) are responsible for the phenotype seen in ADHR, as well as in XLHR and ARHR, and the three conditions have a quite similar clinical presentation, as described above. Remarkable for ADHR, however, is the delayed onset of symptoms until after puberty or pregnancy observed in some females, as well as spontaneous remission of symptoms and biochemical disturbances after puberty observed in some males (108).

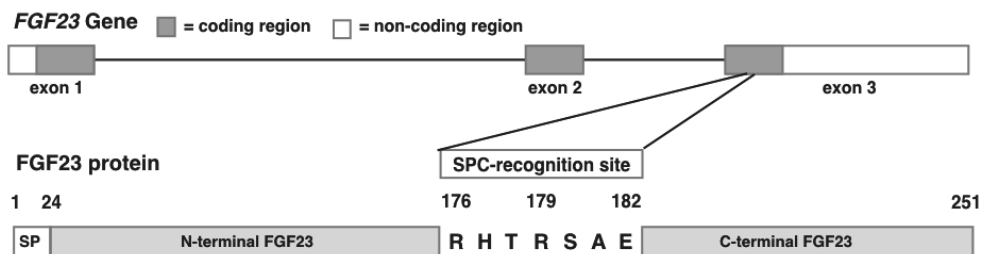


Figure 6 *FGF23* gene and protein structure.

The *FGF23* gene comprises 3 exons encoding the 251 amino acids of FGF23. The protein has a signal peptide encoded by exon 1. The subtilisin proprotein convertase (SPC) recognition site encoded by exon 3 contains the furin protease cleavage site. Mutations altering the arginine residues in position 176 or 179 make the protein resistant to enzymatic break down.

Hereditary hypophosphatemic rickets with hypercalcuria

Hereditary hypophosphatemic rickets with hypercalcuria (HHRH), first described in 1985 (109), is caused by homozygous or compound heterozygous mutations in the *SLC34A3* gene (OMIM*609826), encoding the type IIc sodium-phosphate cotransporter (NaPi-IIc) (110, 111). There is no general tubulopathy, but the hypophosphatemia leads to a compensatory up-regulation of 1,25(OH)₂D with increased intestinal absorption of calcium and phosphate, finally resulting in hypercalcuria. The level of intact FGF23 has been reported as suppressed (112) or low normal (113). Hypophosphatemia can lead to rickets and osteomalacia, and the high calcium-phosphate product in urine leads to nephrolithiasis and

nephrocalcinosis. However the phenotype is highly variable, including the degree of reduced phosphate reabsorption in individuals with heterozygous mutation.

Interestingly, while mutations in the murine orthologue of *SLC34A3* do not have a similar effect in animal models, NaPi-IIa double knockout mice have a phenotype resembling HHRH, except from rickets and osteomalacia (114). NaPi-IIc thus seems to play a less important role in murine proximal tubular phosphate resorption than in humans (115). In humans, there are a few reports of autosomal dominant mutations in *SLC34A1* (OMIM*182309), leading to a syndrome of hypophosphatemia, osteoporosis and nephrolithiasis (116). Very recently, autosomal recessive mutations in *SLC34A1* were shown to cause idiopathic infantile hypercalcemia (IIH) with hypophosphatemia and suppressed FGF23 levels (117).

Other forms of hereditary hypophosphatemia with and without rickets ***KL-associated hypophosphatemia.***

As described in section 1.3.3 α -klotho is a co-receptor for FGF23 at the FGFR1c, and increased stimulation of this receptor leads to phosphaturia and hypophosphatemia. A balanced translocation between chromosomes 9 and 13 (t(9,13)(q21.13;q13.1)) of the *KL* gene (OMIM+604824), leading to up regulation of *KL*-transcription, has been found in the only described case of *KL*-associated hypophosphatemia (118). The patient was a 1-year old girl with poor linear growth, increasing head circumference, clinical and radiological signs of rickets, hypophosphatemia, renal phosphate wasting and elevated levels of parathyroid hormone and alkaline phosphatase. She also had dysmorphic features of the face, and an Arnold-Chiari 1 malformation (118). Dental involvement was not described.

The α -klotho protein is considered an anti-aging hormone in mice (119). Accelerated aging has been observed in *KL* knockout mice, along with decreased insulin secretion and increased insulin sensitivity (120). Mice experimentally overexpressing *KL* have a prolonged life span (119). Human *KL* is expressed mainly in the kidney, and the secreted variant seems to dominate (121). Recent findings from mouse studies

suggest that α -klotho has endocrine, paracrine and autocrine effects independent of FGF23 (122).

FGFR1c-associated hypophosphatemia – Osteoglophonic dysplasia

Osteoglophonic dysplasia is a rare autosomal dominant condition caused by activating mutations in the *FGFR1* gene (OMIM*136315) (123). The patients present with dwarfism, facial dysmorphism and sometimes craniosynostosis. It has also been associated with hypophosphatemia (124) and dental involvement, with failure of tooth eruption and mandibular malformations (123). As described in section 1.3.3 the FGFR1c, with α -klotho as co-receptor, is the functional receptor for FGF23 (58), and activating mutations in the *FGFR1* gene leads to constitutive activation of the receptor and its intracellular tyrosine kinase domain. This has the same consequences as overexpression of FGF23.

FGFR1-3 is implicated in skeletal development, and various mutations in the corresponding genes are responsible for a number of skeletal dysplastic syndromes (125). In mice, the *Fgfr4* has been shown to be a functional receptor for the group of endocrine FGFs, including FGF23 (126), but clinical significance of this association is not known, and there are no reports of human phosphate regulation disorders related to mutations in the *FGFR4* gene.

***SLC9A3R1*-associated hypophosphatemia**

Autosomal dominant mutations in the *SLC9A3R1* gene (OMIM*604990) has been found in patients with nephrolithiasis associated with hypophosphatemia and reduced TmP/GFR, as well as osteoporosis or osteopenia (127, 128). The levels of 1,25(OH)₂D are elevated or in the upper normal range, while the FGF23 are normal or in the lower normal range (127, 128). *SLC9A3R1* encodes the sodium/hydrogen exchanger regulatory factor 1 (NHERF1), which is involved in maintenance of the cytoskeleton of renal tubular cells and other polarized cells with microvilli (129), and in mice has been shown to be involved in intracellular trafficking and plasma membrane localization of the NaPi-IIa (130).

1.5.2 Treatment and follow up

Treatment of hypophosphatemic rickets has evolved during the last 50 years. Initially high doses of vitamin D were used, with some improvement of rickets (7). In the seventies elemental phosphorus was added to the treatment, which improved growth, healing of rickets and reduction of bowing (131), but on the expense of nephrocalcinosis (132, 133) and hyperparathyroidism (131).

Modern treatment still involves oral phosphate supplements combined with active vitamin D, as calcitriol or alfacalcidol, and recently updated treatment recommendations have been published (32, 134). The aim of the treatment is to improve rickets and growth while at the same time avoiding hypercalcuria and hyperparathyroidism. The daily dose of phosphate has to be split in several smaller doses given 4-6 times daily, as the serum level of phosphate is back to the low steady state within a few hours after administration. Each dose of phosphate gives a stimulus for increased secretion of PTH, both due to the peak in serum phosphate itself (131), as well as a transient decrease in serum calcium upon phosphate administration. This transient hyperparathyroidism is counteracted by active vitamin D, which is administered twice daily. Combination therapy is started once the diagnosis has been made, and that the starting dose of phosphate is low, to reduce gastrointestinal side effects, which can make compliance to treatment difficult. The doses of phosphate and vitamin D are then titrated up to the least efficient doses, i.e. the lowest phosphate dose that leads to healing of rickets, improved growth, and straightening of lower extremity axis deviation. The recommended doses (32), along with dosing interval and administration form, are given in Table 2.

Combination therapy with phosphorus and calcitriol is recommended for all children with hypophosphatemic rickets (32, 135). In FGF23 dependent HH without rickets, treatment is not established. In FGF23 independent HR, as in HHRH, the production of $1,25(\text{OH})_2\text{D}$ is endogenously up-regulated, and thus only phosphorus supplement is recommended.

Treatment continues until the child has reached final height and the growth plates are closed. Correcting osteotomy is performed if severe/disabling skeletal axis deviation persists when longitudinal growth is complete. Treatment in adults is not routinely recommended, but combination therapy is recommended as preparation for orthopedic surgery, after fractures and in cases of disabling bone pain (134).

Table 2 Recommended treatment of hypophosphatemic rickets in children.

Substance	Formulation	Starting dose	Maintenance dose	Doses per day
Elemental phosphorus	Mixture Effervescent tablets	10 – 20 mg/kg/day	20 – 40 mg/kg/day	4
Calcitriol ¹	Tablets	10 – 15 ng/kg/day	20 – 30 ng/kg/day	2
Alphacalcidol ¹	Droplets Tablets	15 – 20 ng/kg/day	30 – 50 ng/kg/day	1

¹Active vitamin D is given as either calcitriol or alphacalcidol, and is recommended only for treatment of FGF23 dependent HR. Adapted from (32, 135).

Close therapeutic monitoring is essential to ensure adequate treatment and therapeutic compliance, and to avoid development of complications. Recommendations for monitoring of HR are presented in Table 3 ((32). Clinical and biochemical controls are recommended at least four times annually, with extra biochemical controls after adjusting the doses of phosphate of vitamin D. Skeletal X-rays of the wrist and lower extremities are performed every 2 years to ensure healing of rickets (32).

Normalization of growth rate and clinical and radiological healing of rickets are indicators of sufficient phosphorus supplementation. Serum phosphorus level is not a good indicator of treatment efficiency, but is used as a guidance to determine least efficient dose. This can be tested in a phosphate challenging test: Serum phosphate is measured in the fasting state in the morning, immediately before administration of phosphorus, and then every 30 minutes for 150 minutes after administration of the child's regular dose. The peak S-phosphate is recommended to reach lower reference

Table 3 Therapeutic monitoring of hypophosphatemic rickets

	Tests	Therapeutic goals	Interval	Therapeutic measure
Clinical exam	Growth Rickets	Normal growth Heal rickets	Every 3 months	Adjust phosphate and calcitriol doses
	Bowing Skeletal pain	No axis deviation No skeletal symptoms		
	Dental involvement	Avoid abscess		Refer for dental care
Blood tests	S-P	Low ¹	Every 3 months	High ALP: increase phosphate- and calcitriol doses. High PTH: reduce phosphate and/or increase calcitriol
	S-ALP	High normal		
	S-Creatinine	Normal		
	S-PTH	High normal		
	S-Ca	Normal		
	S-1,25(OH) ₂ D	Normal		
Urine analysis	U-Ca/Crea-ratio	< 0.87	Every 3 months	Reduce calcitriol dose in case of hypercalcuria
Phosphate challenge test ²	S-P	Delta S-P 0.5 mmol/L ²	Every 6 months	Adjust phosphate dose
Radiology	Knee X-ray	Healing of rickets	Every 2 years	Increase phosphate- and calcitriol dose
	Skeletal age	Normal growth		
	Renal ultrasound	Avoid nephrocalcinosis		Reduce phosphate and calcitriol dose

¹Based on recommendations in (32)

¹S-P is not used in therapeutic monitoring, except as part of the phosphate challenge test.

²S-P is measured in the fasting state, immediately before administration of the child's regular morning dose of phosphate, and then every 30 minutes for 150 minutes. The peak S-P is recommended to reach lower reference interval, and the difference in S-P between pre and post administration (delta S-P) is recommended to be about 0.5 mmol/L (6).

interval, and the difference in S-phosphate between pre and post administration is recommended to be about 0.5 mmol/L (6). This ensures a peak S-phosphate level sufficient for proper mineralization of bone, while at the same time reducing phosphate elicited PTH secretion. Monitoring for hypercalcuria and nephrocalcinosis

is effectuated by checking for hypercalcuria at every clinical visit. The U-Ca/Crea-ratio should be less than 0.87 mmol/mmol. Renal ultrasonography is performed every 2-5 years (136). As discussed above, the mildest degrees of nephrocalcinosis may not be of clinical significance, and if stable, vitamin D doses can be kept unchanged. However, if hypercalcuria increases or the ultrasonography shows increasing nephrocalcinosis, vitamin D doses should be reduced to avoid compromising renal function.

Elevated levels of PTH can be counteracted by reducing phosphorus dose, or if this worsens growth and rickets, by increasing the calcitriol dose. Urine calcium/creatinine ratio is measured to avoid hypercalcuria and risk of nephrocalcinosis. In this case, calcitriol dose must be lowered. In difficult cases of secondary hyperparathyroidism, where increase in calcitriol dose can not be done, the calcimimetic drug cinacalcet can be added to treatment (137).

1.6 Hereditary hyperphosphatemia

Hereditary hyperphosphatemia refers to two closely related conditions caused by reduced function of FGF23, namely hyperphosphatemic familial tumoral calcinosis (HFTC) and hyperphosphatemic hyperostosis syndrome (HHS). The clinical and biochemical phenotype in these conditions mirrors the phenotypes of hereditary hypophosphatemia.

1.6.1 Genetics in hereditary hyperphosphatemia

Mutations in three genes, *GALNT3*, *FGF23* and *KL*, have been associated with HFTC and HHS as described in the following.

GALNT3

Homozygous and compound heterozygous mutations in the *GALNT3* gene (OMIM *601756) were the first to be associated with HFTC (138) and HHS (139), and mutations in the first nine of all 10 exons have been described (140). *GALNT3* encodes the UDP-GalNAc:polypeptide N-acetylgalactosaminyltransferase3 (GalNAcT3) responsible for O-glycosylation serine and threonine residues of FGF23, making FGF23 less susceptible to proteolysis by furin proteases (141). Inactivating mutations in *GALNT3* thus leads to increased break down of FGF23 to inactive fragments (142).

FGF23

While mutations affecting the cleavage site in exon 3 stabilizes the FGF23 protein (see earlier section), homozygous or compound heterozygous mutations in other parts of the *FGF23* gene will destabilize FGF23 (143) and lead to increased proteolysis by the furin protease. Mutations associated with HFTC/HHS probably disturb the O-glycosylation of FGF23 by GalNAcT3 (142).

KL

As described earlier, because of the low receptor affinity of FGF23, α -klotho is an obligate co-receptor for the binding of FGF23 to its receptor, FGFR1. An inactivating mutation in *KL* has been described only once, in a severe case of HFTC (144).

1.6.2 Clinical features in hereditary hyperphosphatemia

Hyperphosphatemic familial tumoral calcinosis

HFTC was first described by Giard in 1898 (145), and usually presents as symptomatic soft tissue calcifications in proximity to large joints such as the hip or shoulder girdle. The tumors can increase in size to inhibit joint movement, or make overlying skin rupture, with emptying of a white matter composed of calcium-phosphate crystals. In addition there are reports of conjunctival and retinal

calcifications (146, 147), testicular microlithiasis (148), and vascular calcifications (149). Dental involvement, with short dental roots, obliterated pulp chambers and enamel defects, has also been described (150, 151). Biochemically, there is hyperphosphatemia with an increased TmP/GFR, as well as high normal or increased levels of 1,25(OH)₂D (152, 153), while serum calcium and PTH are usually in the normal range (148, 154). The combination of low serum or plasma levels of intact FGF23 and increased levels of c-terminal FGF23 is characteristic (155).

KL-associated hyperphosphatemia has been described only once, in a 13-year-old girl with severe soft tissue- and vascular calcifications. She had hypophosphaturic hyperphosphatemia, but also hypercalcemia, hyperparathyroidism and elevated levels of FGF23. Except for vascular calcifications, there were no signs of accelerated aging (144).

Hyperphosphatemic hyperostosis syndrome

Hyperphosphatemic hyperostosis syndrome was described by Melhem in 1970, as recurrent episodes of spontaneous painful swelling of limbs (156). Each episode affected one limb and was accompanied by fever and elevated blood sedimentation rate in the acute phase. The swellings disappeared without treatment during weeks to months. Skeletal x-ray shows areas of cortical hyperostosis with onionskin appearance and periosteal apposition corresponding to the swellings, and important clinical and radiological differential diagnoses are osteomyelitis and osteosarcoma. This phenotype has been described in children and young adults (139).

1.6.3 Treatment and follow-up

Treatment of HFTC is difficult and only partially successful. Different therapeutic approaches to reduce intestinal phosphate absorption and renal phosphate reabsorption are normally conducted, with limited success (157). Combination therapy with oral phosphate binders and acetazolamide, a carbonic anhydrase inhibitor, has been reported to lower serum phosphorus levels and reduce tumoral

masses in some patients (158). Surgical intervention with extirpation of the calcific tumors is rarely successful, as the tumors tend to recur at the site of surgery, sometimes with development of chronic fistulation. Future therapeutic possibilities may include direct targeting of blood FGF23 levels.

1.6.4 Complications and prognosis

HFTC/HHS is a chronic condition, and as stated above, treatment is only partially successful. Vascular calcifications as seen in our patient, and also described in the literature, points to a possible risk of premature cardiovascular disease. However, this has not been systematically examined, and the long-term prognosis and life expectancy for this condition is not known.

1.7 Acquired disorders with elevated FGF23

Tumor induced osteomalacia

Tumor induced osteomalacia (TIO) is a rare paraneoplastic phenomenon associated with mesenchymal tumors (159), and recently tumors causing TIO has been accepted as a formal tumor entity called Phosphaturic mesenchymal tumor (PMT) (160). This acquired form of osteomalacia was first described by McCane in 1947 (161), but it was not until 12 years later that the association to bone tumors was found (162). The patients have hypophosphatemia and reduced TmP/GFR caused by tumor production of FGF23. PMT is very rare in childhood (159), and will cause a clinical and biochemical phenotype similar to XLHR, ARHR and ADHR in growing children. A search for a tumor causing TIO might be considered in a child with relatively abrupt onset hypophosphatemia with reduced TmP/GFR, a low or low normal $1,25(\text{OH})_2\text{D}$, with a negative family history and mutation screening of *PHEX*, *FGF23*, *DMP1*, *ENPP1* and *FAM20C* has failed to identify any pathogenic mutation (163). However, the FGF23 producing tumors are often small and difficult to identify, and there is

often a diagnostic delay (164). Definite treatment of TIO is by complete removal of the tumor, but if the tumor cannot be localized, or is not available for surgery, the treatment is principally the same as in HR (163).

Chronic renal failure

Chronic renal failure (CRF) is another acquired condition associated with elevated levels of FGF23 (165, 166). The mechanism behind elevated FGF23 in CRF is not fully clarified; while the hyperphosphatemia of CRF will give a stimulus for increased production of FGF23, increased levels of FGF23 are found even before the development of hyperparathyroidism and hyperphosphatemia in CRF (166, 167). Furthermore FGF23 levels rise gradually corresponding to the decline in kidney function (168). Normally, most of the phosphate-regulating properties of FGF23 are dependent on α -klotho as a cofactor for FGFR1. In CRF the production of α -klotho from the distal kidney tubule is reduced (169), and this has been suggested as a mechanism for a compensatory over-production of FGF23 from bone (170). Hyperphosphatemia itself is associated with cardiovascular calcifications. In addition, the elevated levels of FGF23 are thought to have independent pathologic effects. Pathologically elevated levels of FGF23 have been associated with left ventricular hypertrophy (171, 172), endothelial dysfunction (173), atherosclerosis (174), retinopathy (175) and increased risk of mortality in chronic kidney disease (168) and persons with coronary heart disease (176).

2. Aims

The overall aim of this thesis was to study familial disorders of phosphate metabolism.

Specifically, we used data and samples from Norwegian patients to:

- Study the prevalence of hereditary hypophosphatemia in the Norwegian pediatric population.
- Study the phenotype and outcome of Norwegian children with hereditary hypophosphatemia.
- Study the genetic causes in Norwegian families with hypo- or hyperphosphatemia
- To identify novel genes associated with familial disorders of phosphate metabolism.

3. Materials and methods

3.1 Patient population

During 2009 all pediatric hospital departments in Norway were contacted to identify children with hypophosphatemic rickets. In addition, we retrieved anonymized data from the Norwegian Patient Registry (NPR), where all diagnosis codes from all national health institutions are linked to the personal identification number in the Norwegian Central Office of Civil Registration. NPR data was used to match the number of cases identified at the hospital departments with the number of patients younger than 18 years registered with the diagnosis code “E83.3 Disorders of phosphorus metabolism and phosphatases”, in the World Health Organization’s International Classification of Diseases version 10 (WHO ICD-10). Because the NPR data were anonymized, we were not able to identify cases, only the number of patients.

By contacting the hospital departments, we were able to identify 23 children diagnosed with hypophosphatemic rickets by December 31. 2009. The number of children in the National Patient Registry with the ICD-10 diagnosis “E83.3 Disorders of phosphate metabolism and phosphatases” were 32 by the end of 2009. All hospital departments were therefore contacted again, to clarify the diagnosis of the nine cases not reported on the first personal contact. Four of the patients had hypophosphatasia, and five had transient hypophosphatemia in the course of malignancy, premature birth, or other underlying condition. We identified another four patients during the period January 01 2010 until December 31 2013, two of which were immigrants during this period, one patient born to a XLHR mother, and one child born 2008 but not diagnosed until 2010. Despite repeated contact with the treating physician, one male patient with hereditary hypophosphatemia could not be included in the study. In addition, for two patients we were not able to review the patients’ medical records.

The patients were informed about and recruited to the study by the treating physician. A total of 28 hypophosphatemic patients gave written informed consent (Figure 7). Through contact with the hospitals, we also identified, and got the informed consent, from three adult patients with hyperphosphatemic tumoral calcinosis.

In cases where a genetic diagnosis could not be established with standard genetic analysis, also healthy family members of the index cases were included in the project. The diagnostic criteria for hereditary hypophosphatemia were hypophosphatemia combined with reduced TmP/GFR, normal serum calcium level, inappropriately normal or decreased levels of 1,25(OH)₂D, elevated alkaline phosphatase and normal or slightly elevated PTH (134). A family history or genetic diagnose was supportive, but not required for the diagnosis. We did not include patients with Fanconi syndrome or other tubulopathy, patients with vitamin D dependent rickets, tumor induced osteomalacia or vitamin D deficiency. Nor did we include patients with transient hypophosphatemia secondary to acute illness.

The diagnostic criteria for hyperphosphatemic tumoral calcinosis and hyperphosphatemic hyperostosis syndrome were a history of tumoral calcinosis or diaphysitis in patients with hyperphosphatemia combined with a high normal or elevated TmP/GFR (156, 177). We did not include patients with hyperphosphatemia and calcifications due to kidney failure, hypoparathyroidism and pseudohypoparathyroidism.

3.2 Review of medical history

The medical records of included patients were reviewed, and all data relevant for the phosphate balance disorder were recorded, including age at diagnosis, clinical and biochemical findings at diagnosis, treatment history and development of complications. Laboratory data from each visit from the time of diagnosis to the time of inclusion in the study, including serum levels of calcium, phosphorus, alkaline phosphatase, creatinine, parathyroid hormone and vitamin D status (25OHD and

1,25(OH)₂D) were also recorded, as well as results from kidney ultrasound and skeletal x-ray examinations.

3.3 Genetic analysis

For the purpose of genetic analyses and biobanking, in all included subjects genomic DNA was purified from blood using the QiaSymphony system (Qiagen, Hilden, Germany).

If mutation status was not already known, all exons and intron-exon boundaries of *PHEX* were sequenced in the index case of each family. If a disease causing mutation was not found, and the inheritance pattern suggested a sporadic case or X-linked dominant disease, we sent DNA for multiplex ligand-dependent probe amplification (MLPA) analysis of *PHEX* at the Molecular Genetics Laboratory, Royal Devon and Exeter Foundation NHS Trust, Exeter, Devon, UK. The *PHEX* MLPA analysis can identify mid-size deletions and insertions not detected by regular Sanger sequencing or chromosomal analysis.

In addition to *PHEX* analysis, we sequenced all exons and intron-exon boundaries of *FGF23*, *DMP1*, *KL* and *ENPP1* in successive order, in subjects without pathogenic *PHEX* mutations. After the identification of *FAM20C* mutations after whole exome sequencing in two siblings with hypophosphatemia, hyperphosphaturia, dental abscesses and osteosclerosis (178), we also screened *FAM20C* in patients without mutations in the aforementioned genes. In patients with hyperphosphatemic tumoral calcinosis we screened all exons and intron-exon boundaries of *FGF23*, *GALNT3* and *KL*.

3.3.1 Sanger sequencing

In short, DNA targets were first amplified by polymerase chain reaction (PCR) (list of primers available upon request) using the AmpliTaq Gold® DNA polymerase system (Applied biosystems, Life biosystems, Carlsbad, California, USA. PCR amplicons were purified with 2 µl of ExoSapIT®. Using the Big Dye Terminator® chemistry sequencing was performed on the 3730 DNA analyzer, (Applied biosystems) and analyzed using the SeqScape® software (Applied biosystems).

3.3.2 Further genetic analyses

In subjects without a genetic diagnose after screening of the genes known to cause hypophosphatemic rickets, further genetic analysis was considered if this was anticipated to have clinical and therapeutical relevance. Whole genome SNP genotyping was conducted if the pedigree was considered informative for this purpose. Whole exome sequencing was conducted after the patients had received genetic counseling and given specific written informed consent concerning whole exome sequencing. Genomic DNA was purified from blood using the QiaSymphony system (Qiagen, Hilden, Germany). Whole genome SNP genotyping was performed with GeneChip Human Mapping 6.0 array (Affymetrix, Santa Clara, USA). Whole Exome capture using Roche-Nimblegen's SeqCap EZ Exome v2 and sequencing on the Illumina HiSeq was performed at the HudsonAlpha Institute for Biotechnology (Huntsville, AL) to a median coverage of 154x according to manufacturer's protocol(179). The paired-end 100nt reads were analyzed with CASAVA v1.8 (Illumina Inc) followed by alignment with Burrows-Wheeler transformation(180). PCR duplicates were removed with PICARD (<http://picard.sourceforge.net>) and the Genome analysis toolkit (GATK) was used for base quality recalibration(139). SNPs and indels were called using the GATK unified genotyper using a minimum threshold of 8X sequencing depth and quality score ≥ 30 . Annovar (181) and in-house scripts were used for variant annotation.

3.4 Statistics

The prevalence of hypophosphatemic rickets was calculated based on the number of patients aged 0-17 years with this diagnose in 2009 and the total number of people in Norway aged 0-17 years by January 1.2010, obtained from the official Statistics Norway database (182). In the XLHR patients, we compared phenotypic, treatment and complication data in male versus female subjects. According to an earlier study (83), the XLHR patients were grouped depending on initiation of treatment before or after one year of age, and phenotypic and complication data were compared for these groups. Between-group comparisons of medians were performed using the independent samples Mann-Whitney U-test, and comparisons of proportions were performed with Fisher's exact test.

3.5 Ethics and approvals

Written informed consent was obtained from all study participants. The project was conducted according to the declaration of Helsinki and was approved by the Regional Committee for Medical and Health Research Ethics, Region West, Norway (REK number 2009/1140). The study was registered at www.ClinicalTrials.gov with registration number: NCT01057186. In cases where exome sequencing were offered, the patients received genetic counseling by a registered genic counselor before giving a specific written informed consent, and also after the results were ready, in concordance with the Norwegian Biotechnology Act (183). Children that were recruited before the age of 16 years, and who turned 16 years during the time of the ongoing study and biobanking, gave a new, written informed consent at the age of 16 years, according to the Norwegian Biotechnology Act.

4. Results

4.1.1 Overview of papers I-III

Paper I describes the cohort of Norwegian children with HH. This paper is the first to describe a complete national cohort of HH, including XLHR, and we show that the prevalence of XLHR in Norway is 1 in 60.000, as compared to the commonly reported international prevalence of 1 in 20.000 (71, 72). *PHEX* mutations were confirmed in 21 of the 28 included patients (Figure 8) from 13 different pedigrees, and nine of the 13 *PHEX* mutations were novel. In the non-XLHR patients we identified novel compound heterozygous mutations in *FAM20C* in two male siblings (Paper II), and novel compound heterozygous mutations in *SLC34A3* in a male with HH with hypercalcuria. In four of the children we could not identify the pathogenic mutation.

The median age for diagnosis of HH was 2.1 years and for XLHR 0.9 years, and treatment with oral phosphate and active vitamin D was started shortly after diagnosis in most. In XLHR patient we compared phenotypes based on gender and on treatment start before or after one year of age. Although none of our comparisons reached statistical significance, we were able to show trends, including a tendency for males being more growth restricted and more often have dental involvement than females. We found no effect on growth by early start of treatment, but early start of treatment and higher doses of phosphate supplement tended to be associated with a risk for the development of nephrocalcinosis.

Paper II describes the identification of a novel FGF23 dependent form of hereditary hypophosphatemia, associated with mutations in the *FAM20C* gene. Two male siblings with hypophosphatemia, hyperphosphaturia, severe dental complications, but with normal growth and no signs of rickets, also showed intracerebral calcifications and mild dysmorphic features. Exome sequencing revealed novel compound heterozygous mutations in the *FAM20C* gene. Three first-degree relatives

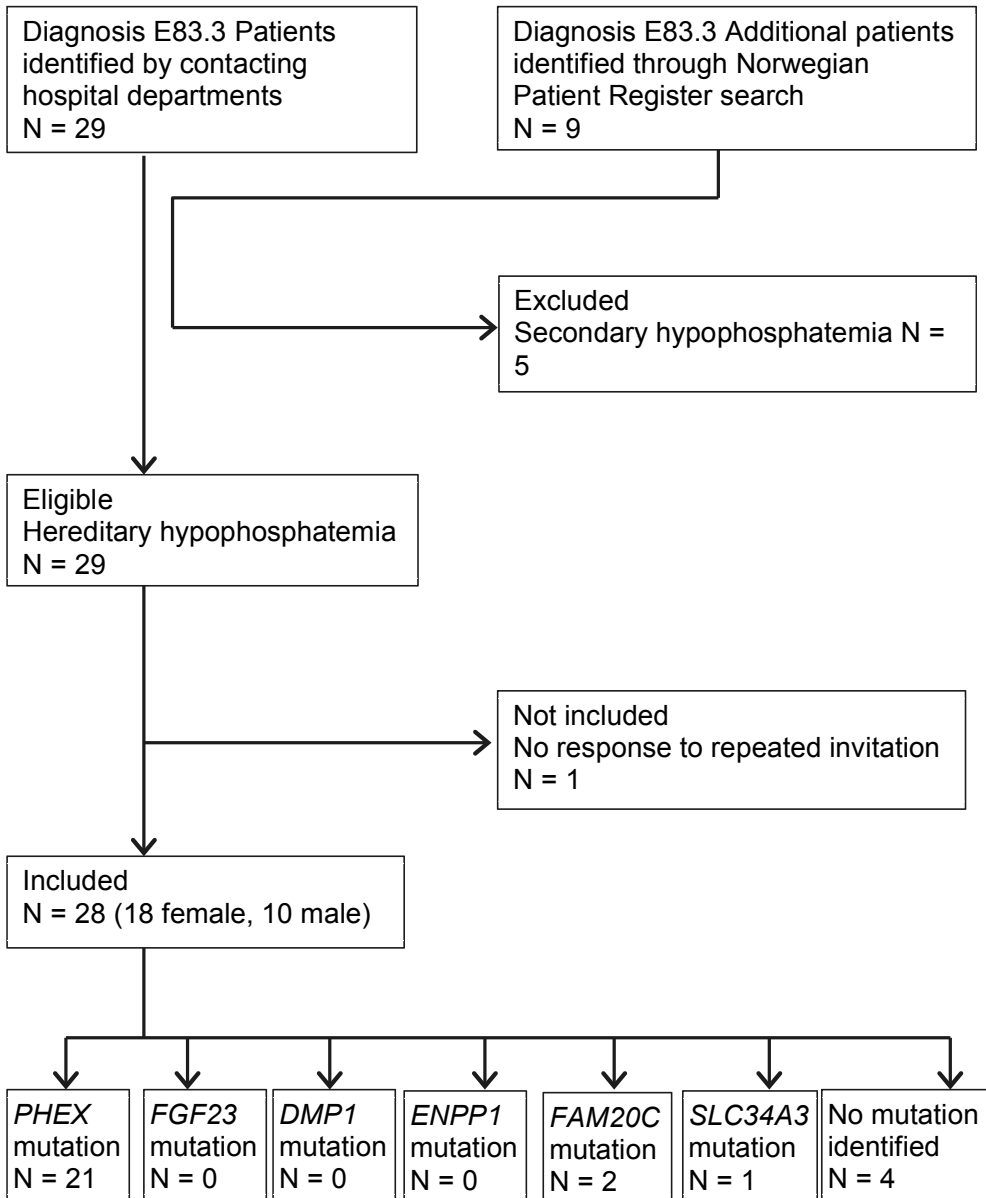


Figure 7 Inclusion of patients

heterozygous for the wild type allele, were unaffected. Mutations in *FAM20C* has earlier been associated with lethal and non-lethal variants of Raine syndrome, but we show for the first time, that the hypophosphatemia seen in many of these subjects is associated with inappropriately elevated levels of FGF23.

Paper III describes two adult siblings with hereditary hyperphosphatemia, and a phenotype of HFTC in the male and a combined phenotype of HFTC and HHS in the female. We identified a novel homozygous mutation in the *GALNT3* gene, and pedigree analysis revealed consanguinity, as the parents had a common ancestor eight generations back. They were diagnosed and started treatment at the ages of 37 and 50 years, respectively. In retrospect, they both had symptoms of disease in childhood and adolescence. The paper describes the natural evolution of the disease, with long symptom free intervals, and also describes novel phenotypic features and great phenotypic variability between the siblings. Finally, the paper reviews all 54 published cases of HFTC and HHS in which the pathogenic mutation had been identified, and shows that a combined phenotype of HFTC and HHS is more common than previously recognized.

5. Discussion

5.1 Methodological issues

5.1.1 Study design

The retrospective design of the study implies that registration of clinical data for children treated by different clinicians in different hospitals may show some variations. Furthermore, biochemical analysis has been performed in different hospital laboratories, and may thus have slight differences in reference intervals, despite use of equal methods and equipment throughout Norway.

In XLHR we wanted to explore the possible associations between gender, mutation type, age at start of treatment, and different phenotypic features. However the sample size was rather small, with only 21 patients, and several of these were first or second degree relatives. In some of the pedigrees, all the affected children were females, whereas in other families there were only males. Thus, when comparing the effect of gender on phenotype or genotype-phenotype associations, it is not possible to know whether it is gender or genotype that is most influential on phenotype. In three families, there were affected children of both genders, four females and three males. However, one of these families was immigrant, and the children were diagnosed very late, and we have no information on past medical history. Thus, with only three females and two males eligible for comparison, there would still be problems with the validity of the results of statistical analysis. Also, we have no information about treatment compliance that would be relevant for the data collected at the last registered consultation.

5.1.2 Ethical considerations in genetic analyses

In four patients, we were not able to find the genetic diagnose, despite extended genetic analyses. In two of these families we have proceeded with exome sequencing, but without finding a plausible candidate gene in either family.

Exome sequencing carries the risk of accidentally finding pathogenic mutations in genes associated with potentially serious diseases, but not subject of the current research. Therefore, if exome sequence was considered, patients were referred for genetic counseling at an approved hospital department before deciding to give consent for exome sequencing, and also after the results were ready. This is in line with the Norwegian Biotechnology Act, which regulates the use of genetic testing of children and adults.

5.2 Discussion of results

5.2.1 Hereditary hypophosphatemia in Norwegian children – Paper I

Prevalence of hereditary hypophosphatemia and hypophosphatemic rickets in Norway

We found a prevalence of XLHR of 1 in 60.000 Norwegian children. There are not many studies reporting the prevalence of XLHR in the population described; actually until recently, there is one commonly cited paper, reporting a prevalence of 1 in 20.000 (71). This number was recently confirmed by a study from the population of Southern Denmark (72). However, both these studies are regional, and the risk of selection bias cannot be ruled out. Another possible explanation of the lower prevalence of XLHR observed in our cohort might be sex-dependent differences in disease penetrance; Earlier studies of large pedigrees of XLHR patients found a lower penetrance of skeletal manifestations in hypophosphatemic females as compared to

full penetrance of skeletal manifestations in hypophosphatemic males (184, 185). It is thus possible that, in Norwegian families without affected males, there are undiagnosed hypophosphatemic females. In X-linked dominant disorders, the expected ratio of affected females to males is 2:1, whereas in our population the female to male ratio was 16 to 5, or 3:1. Hence, this does not support a theory of a large proportion of undiagnosed Norwegian XLHR females. Our study included only children already in contact with health care because of hereditary hypophosphatemia, and in most instances serum phosphorus had been measured in apparently healthy parents and siblings. Mutation screening of the *PHEX* gene in all first-degree relatives of the XLHR probands, even if they are symptom free and normophosphatemic could theoretically detect subclinical XLHR, but this raises difficult ethical considerations of predictive genetic testing, for which strict guidelines apply (183). Children with hypophosphatemic rickets were identified through direct contact with treating physicians at all pediatric hospital departments in Norway, and compared to data from the Norwegian Patient Registry (NPR), as described in Paper I. We did not contact general practitioners in the search for children with hereditary hypophosphatemia, and therefore cannot rule out the possibility of hereditary hypophosphatemia in asymptomatic children.

The true prevalence of XLHR in the Norwegian pediatric population might be higher than our study shows, but the prevalence of clinical significant XLHR is probably correctly reported in our study.

Genetics in hereditary hypophosphatemia

PHEX mutations were confirmed in 21 of the 28 included patients (Figure 8) from 13 different pedigrees, and comprised 87 % of the verified mutations. This supports recent reports from other cohorts (97), and confirms that XLHR is the most common variant of HR. Nine of the 13 *PHEX* mutations (69 %) were novel, not previously reported in the literature or found by searching the SNP database

(<http://www.ncbi.nlm.nih.gov/projects/SNP/index.html>), *PHEX* database

(<http://www.pahdb.mcgill.ca/cgi->

bin/phexdb/phexdb_mutQ1.cgi?field=ID_mut&value=) or the ExAC Browser (<http://exac.broadinstitute.org/gene/ENSG00000102174>). Our finding supports what has earlier been reported, that a high proportion of the mutations in this gene are unique to each pedigree (185). In the non-XLHR patients we identified novel compound heterozygous mutations in *FAM20C* in two male siblings, and novel compound heterozygous mutations in *SLC34A3* in a male with HH with hypercalcuria, while no likely pathogenic mutations were found in the *FGF23*, *DMP1*, *ENPP1* and *KL* genes. Although we could not identify the pathogenic mutation in four of the children, the mutation detection rate (24 of 28 included patients) is in line with recent reported cohorts of hypophosphatemic rickets (97, 186).

We identified one adolescent male with compound heterozygous mutations in the *SLC34A3* gene, suggestive of HHRH, but without any signs of rickets or other mineralization disorders. He had hypophosphatemia combined with a reduced TmP/GFR and hypercalcuria, detected during diagnostic work-up for recurrent kidney stones. He had a novel splice mutation in intron 7, affecting a conserved splice donor site and a previously reported intronic deletion mutation, (111). The lack of skeletal involvement is not unique in our case. Recent studies have shown that renal calcification was the only clinical manifestation of *SLC34A3* mutations in about 10 % of homozygous and 16 % of compound heterozygous carriers (187, 188). The phenotypic and genotypic diversity in conditions associated with *SLC34A3* mutation reported by others, is thus confirmed by our findings.

In four of the included patients, from four different pedigrees, we were not able to identify the likely pathogenic mutation by standard Sanger sequencing. However, as illustrated by our finding of *FAM20C* mutations, exome sequencing can sometimes help reveal novel associations between genotype and phenotype. In search for novel mutations in genes associated with pathways involving FGF23, phosphate reabsorption and tissue mineralization, we proceeded with exome sequencing in two of the patients without a genetic diagnosis, but without identifying any obvious

candidate genes likely to explain disease in either patient. This illustrates the limitations of exome sequencing in families with only one or two affected subjects. Although this method is currently becoming more efficient, more commonly available and cheaper, the challenges remain in processing of output files. After filtering against databases with common genetic variants, the list of genetic variants potentially associated with the disease in question includes almost 200 genes in an autosomal dominant model, 0-2 genes in a de novo-dominant model and 5-30 genes in a recessive model. Detailed knowledge on the physiological mechanisms and pathways is essential to reduce this list of candidate genes, but often the search for the likely disease-causing mutation ends without results. In addition, exome sequencing screens only the coding part of the human genome, while the non-coding parts of the genome includes important gene regulatory elements. Mutations in such elements has also been associated with disease, but would not be detected in exome sequencing. Whole genome sequencing on the other hand, is becoming feasible in terms of costs and would enable detection of non-coding and more complex genetic rearrangements. This would however, come at the expense of increased complexity, and being more computationally demanding and yielding large numbers of rare potential candidate variants from which it is no trivial quest to prioritize for further studies.

On the other hand, as illustrated by our finding of novel mutations in *FAM20C* (178), exome sequencing can give results that have implications for current understanding of pathophysiology and disease. Our finding of an association between *FAM20C* mutations and elevated levels of FGF23, confirmed findings in murine *Fam20c* KO models, and has been important for later research defining the role of FAM20C in phosphate- and mineralization homeostasis (see section 5.2.2).

Mineralization defects and growth in XLHR

Clinical or radiological signs of rickets or skeletal axis deviation were found in all children with XLHR, including seven children diagnosed before the age of one year through family screening, and starting treatment before development of symptoms.

Early start of treatment and adequate doses of phosphate did not seem to prevent growth restriction or persisting skeletal axis deviation at the last registered consultation.

Growth was complete in six of 21 patients at the last registered consultation, and two of these, both males, had correcting osteotomy after longitudinal growth had completed, while in two females and one male, the axis deviation had not persisted (data missing for one female). One of the males needing correcting osteotomy was immigrant to Norway at age 15.5 years, and had not received any medical treatment for his condition before this. The other male with persisting axis deviation after cessation of growth, had been treated with adequate doses of phosphate (mean 32 mg/kg/day) and alphacalcidol (mean 54 ng/kg/day) from the age of 6 months. The two female patients without axis deviation had received phosphate doses above the recommended range (mean 61 and 74 mg/kg/day) and had signs of nephrocalcinosis on renal ultrasound, while the male without axis deviation had received an adequate phosphate dose (mean 39 mg/kg/day) and had no signs of nephrocalcinosis. This indicates a trend for more aggressive treatment in the patients without persisting axis deviation, but with an increased risk of nephrocalcinosis.

There was a trend for a higher proportion of dental involvement in males (4 of 5) than females (5 of 15), and also a trend for less dental involvement in children who started treatment before the age of one year. These findings support previous reports of more severe dental phenotype in post pubertal males than females (189, 190), and observations that dental involvement can, to some extent, be prevented by starting treatment before one year of age, suggesting the importance of proper mineralization of dentin prior to the eruption of teeth (191).

Without treatment, hypophosphatemic rickets is associated with short stature, both because of skeletal axis deviation in the lower extremities, but also because of poor linear growth (84). In our material the two immigrant children with XLHR, who had not received medical treatment until the ages of 6.5 and 15.5 years, and had height z-

scores of -6.5 and -5.1, respectively, exemplify this. Treatment with phosphate and active vitamin D will correct axis deviation and facilitate growth, but most often the correction is not complete. In our material, if excluding the two immigrant children and one with missing data, 16 of 18 patients had negative height z-score at the last registered consultation, and in five of 18 the height z-score was -2 or lower, despite treatment with adequate doses of phosphate and alphacalcidol. While some studies argue for a positive effect on linear growth by starting treatment before the age of one year (83, 192), we did not find trends for this in our cohort; early start of treatment was associated with both positive and negative change of the height z-score, while in children who started treatment after one year of age, this change was less pronounced. This probably reflects that height z-score at birth reflects to a large extent the intrauterine conditions for growth, and change during the first year of life z-score depending on the genetic growth potential and postnatal environment, also in healthy children (193).

Gender, genotype and phenotype in XLHR

As discussed above, persistent bowing, dental involvement as well as growth restriction tended to be more prevalent in males than females. Studies have shown that both hypophosphatemia (194, 195) and skeletal manifestations (196) seem more pronounced in males, and that some XLHR females may actually show only slight hypophosphatemia and no, or only a very mild, skeletal phenotype (195, 197). Conversely, some studies report no difference in skeletal phenotype between males and females (189, 198). Recent reports suggest that estrogen, which plays an important role in skeletal health, stimulates the production of FGF23 in bone, and estrogen therapy is associated with increased bone mineral density, as well as reduced serum levels of phosphate, PTH and calcitriol, probably via increased levels of FGF23 (199, 200). It has also been shown that estrogen therapy down-regulates the kidney proximal tubule type IIa sodium phosphate cotransporter in rats (201). These findings support the observations made in ADHR, where in some females the disease becomes clinically evident after puberty or in pregnancy (108), as estrogen levels are increasing. However, this cannot explain a milder phenotype in XLHR females, and

the influence of estrogen on FGF23 production in states of FGF23 dysregulation, needs further clarification.

In line with an earlier study (186), the patients were grouped according to the effect of the *PHEX* mutation being either highly likely complete loss-of-function variants, i.e. non-sense mutations and mutations resulting in a truncated protein, or likely to reduce protein function, i.e. missense mutations. When comparing height z-scores, prevalences of rickets and bowing, and the prevalence of dental involvement, we did not find any differences between the two groups, and this supports what was found in a recent study (186). Other studies have found a more severe skeletal phenotype in patients with truncating mutations (202-204). However, observations from our cohort, confirming reports from others (189, 205), show that even in patients from the same family and thus carrying the same mutation, the skeletal phenotype can be very different. What individual factors responsible for this diversity in growth and bone mineralization is not fully clarified, but it could be due both to modifying genetic variants elsewhere in the genome, epigenetic or environmental factors. Recent reports have shown associations between the *FGF23* sequence variant c.C716T (p.T239M, rs7955866) and lower levels of serum phosphate and lower renal tubular maximum reabsorption rate of phosphate to glomerular filtration rate (TmP/GFR) (206), and lower plasma intact PTH in healthy children and adults (207). In neither of these studies, the levels of serum intact FGF23 were higher in individuals homozygous or heterozygous for the c.C716T variant as compared to individuals with only the wild-type allele, and this points to a possible functional importance of this variant. There are several monogenic of phosphate balance disorders described, but probably many yet unidentified allelic variants influencing phosphate metabolism and bone mineralization, collectively accounting for the phenotypic heterogeneity of these disorders.

Treatment and complications in hypophosphatemic rickets

Twenty-six of 28 included patients had been treated with phosphate and calcitriol during childhood. The two patients not treated had not been diagnosed until the

inclusion in the study, and therefore treatment had not yet started. Detailed treatment data was available for most of the patients, and these are presented in appendix Table 5 and 6 of the Appendix.

Nephrocalcinosis is a very prevalent complication of phosphate treatment in HR, and treatment is monitored and adjusted in order to avoid this complication. In our material, nine of the 21 XLHR patients developed nephrocalcinosis. However, of the 12 patients without nephrocalcinosis, only four had been treated with phosphate and vitamin D for a sufficient period of time for nephrocalcinosis to develop. We set this cut off to 5 years, as the nephrocalcinosis was detected within five years of start of treatment in all children with this complication. Unfortunately, nephrocalcinosis was not graded according to recommended classification in all patients, and thus we were not able further classify the severity of nephrocalcinosis. However, renal function was retained in all patients with nephrocalcinosis, except in one female XLHR patient with high-grade nephrocalcinosis, who also developed tertiary hyperparathyroidism (see below) (208). She had transient, mild deterioration in renal function that responded well to adjustment of treatment. This points to an important consideration for the therapeutic management of nephrocalcinosis: Nephrocalcinosis is quite common in phosphate- and vitamin D treated HR patients, with reported prevalences of 33 to 80 % (83, 132, 133, 192, 209-213), and is not seen in patients not treated with phosphate (209, 211, 212). However, it is mostly mild, and rarely leads to renal failure (211). This raises the question of the clinical relevance of mild nephrocalcinosis in HR children who are phosphate dependent to assure growth and healing of rickets. This is also reflected in recently published treatment guidelines (see below); earlier a calcium/creatinine ratio < 0.6 mmol/mmol has been considered safe considering the risk of nephrocalcinosis. Current guidelines consider a calcium/creatinine ratio < 0.87 mmol/mmol as within the safety range (32).

Elevated levels of PTH was found in all the patients in our cohort at some point during treatment, supporting that secondary hyperparathyroidism (HPT) is a common complication to phosphate treatment in HR, explained by the small surges in serum

phosphate following each dose of phosphate, triggers increased production and release of PTH (131). Secondary HPT is also a well-known complication in other conditions of chronic hyperphosphatemia, as for instance chronic renal failure (CRF) (214), while in healthy individuals, hypophosphatemia leads to reduced PTH-levels through an increase in $1,25(\text{OH})_2\text{D}$ (215). However, in HR and CRF, the elevated level of FGF23 inhibits production of $1,25(\text{OH})_2\text{D}$. More interesting, however, is the observation that 10 of 15 XLHR children had PTH levels above the upper age appropriate reference range already before the start of treatment, supporting earlier reports of PTH levels often being slightly elevated in HR patients also before the start of phosphate treatment (87-89). There is evidence suggesting an inhibitory effect of FGF23 on PTH production (216), but as FGF23 levels are elevated in FGF23 dependent HR, the mechanism behind elevated PTH in HR becomes even more difficult to understand. Thus, the inappropriate PTH response in untreated HR, and the interplay between phosphate, FGF23 and PTH, still need to be explored.

In our cohort, two patients developed tertiary HPT, which is a complication of long standing secondary HPT, where the parathyroid glands become autonomous and do not respond appropriately to negative feedback aiming to reduce PTH production and secretion. A female XLHR patient, had received relatively high doses of phosphate and relatively low doses of calcitriol for more than 10 years before the development of tertiary HPT. Through literature search, we were able to find 36 reported cases of tertiary HPT in individuals with hypophosphatemic rickets (208, 217-226). Long duration and high doses of phosphate supplementations were identified as risk factors (217, 221). The calcimimetic cinacalcet has been reported to successfully treat tertiary HPT in both children (208, 227) and adults (228, 229). Recently however, the US Food And Drug Administration stopped all further clinical trials investigating the effects of cinacalcet in children after the report of the death of an adolescent study participant (230). The vitamin D analog paricalcitol has recently been shown to suppress elevated PTH in XLHR (231).

One male patient was treated with growth hormone from the age of 11.8 years, and the treatment showed a positive effect; his height z-score improved from - 3.24 before initiation of growth hormone (average of measurements from age 3.5-10.8 years) to average -2.32 from age 11.8 to age 16 years. His final height at age 16 is -2.0 SD, while both his parents are above average height. Three studies, one in pre-pubertal (232) and two in pubertal (233, 234) XLHR children, have shown a positive effect of growth hormone on catch up growth. Especially, growth hormone therapy in severely stunted children was shown to decrease the disproportion between trunk and lower extremity length (232). Also, growth hormone stimulated renal phosphate reabsorption and diminished nephrocalcinosis in XLHR (232). Other studies (235-237) show conflicting results of growth hormone therapy, but this might be due to differences in anthropometric methods. Our case illustrates that, although the short stature cannot be completely corrected, growth hormone might prove beneficial for some patients, and should be considered in cases of severely reduced anticipated final height.

5.2.2 *FAM20C*: novel association with hereditary FGF23 dependent hypophosphatemia – Paper II.

We identified two novel mutations in the *FAM20C* gene in two siblings with hypophosphatemia and urinary phosphate wasting, but without signs of rickets, and demonstrated, for the first time, an association between mutations in *FAM20C* and elevated levels of intact FGF23. In retrospect, their skeletal and mineralization phenotype shares some features with Raine syndrome, previously described as a lethal condition, and recently shown to be caused by mutations in the *FAM20C* gene (238).

The *FAM20* gene family consists of three genes with sequence similarity, *FAM20A*, *FAM20B* and *FAM20C*, all encoding secreted glycoproteins. They were first identified and characterized in the search for hematopoietic growth factors (239). Later, *Dentin Matrix Protein 4 (Dmp4)*, the mouse orthologue to the human

FAM20C gene, was identified as a calcium binding protein, important for differentiation of odontoblasts in mice (240). Specifically, it was shown that increased expression of *Dmp4* resulted in increased expression of genes important for mineralization in odontoblasts, ameloblasts and osteoblasts, while reduced expression of *Dmp4* had the opposite effect.

Studies on mouse embryos have shown that *FAM20C* is expressed during osteogenesis and odontogenesis, and that mutation in *FAM20C* causes abnormal calcifications in both skeletal and non-skeletal tissues. *FAM20C* thus seem to be important for proper differentiation of cells of mineralized tissues, and to inhibit premature mineralization of tissues during development (241). This expression pattern reflects to a large extent the phenotypic features of Raine syndrome, with distorted mineralization of bone and teeth, and ectopic calcifications in the brain. It was also shown that *FAM20C* expression in the cells and extracellular matrices of bone and teeth increased after birth, then declined. Taken together, this reflects a possible role for *FAM20C* in proper differentiation of the cells and prevention of premature mineralization of these tissues during development.

In 2007 Simpson et al. identified biallelic mutations in *FAM20C* as the cause of Raine syndrome (238). This condition, first described by Raine et al. in 1989, is characterized by osteosclerosis of long bones and skull, leading to dysmorphic features, as well as intracerebral calcifications. The most severe cases are lethal within hours or days after birth, due to respiratory distress secondary to thoracic deformities.

Further studies on *FAM20C* has shown that this is a secreted protein kinase previously identified as the Golgi enriched fraction casein kinase (GEF-CK) that specifically recognizes the consensus sequence S-x-E found in many secreted proteins (242-244). Among these are the Small Integrin-Binding Ligand N-linked Glycoproteins (SIBLING) proteins. Specifically, it has been shown that *FAM20C* is able to phosphorylate the acidic serine aspartate rich MEPE-associated (ASARM)

motif of the SIBLING-proteins osteopontin (OPN), matrix extracellular phosphoglycoprotein (MEPE) and dentin matrix protein 1 (DMP1) (242, 243). The phosphorylation state of the SIBLINGs is important, as it determines the effect of the proteins in bone and dental development and mineralization. For instance phosphorylated ASARMs inhibits the differentiation of odontoblasts and osteoblasts and phosphorylated OPN has anti-mineralizing effects (245), while phosphorylated DMP1 has pro-mineralizing function (246). Non-functional FAM20C will thus have pro-mineralization effect by lack of OPN-phosphorylation, and anti-mineralization effect by lack of DMP1-phosphorylation. Functional studies have shown that survival beyond infancy is associated with mutations leading to partially functional FAM20C protein product (247), and the degree of impairment of phosphorylation correlates with the severity of the phenotype in previously reported cases of Raine syndrome (243).

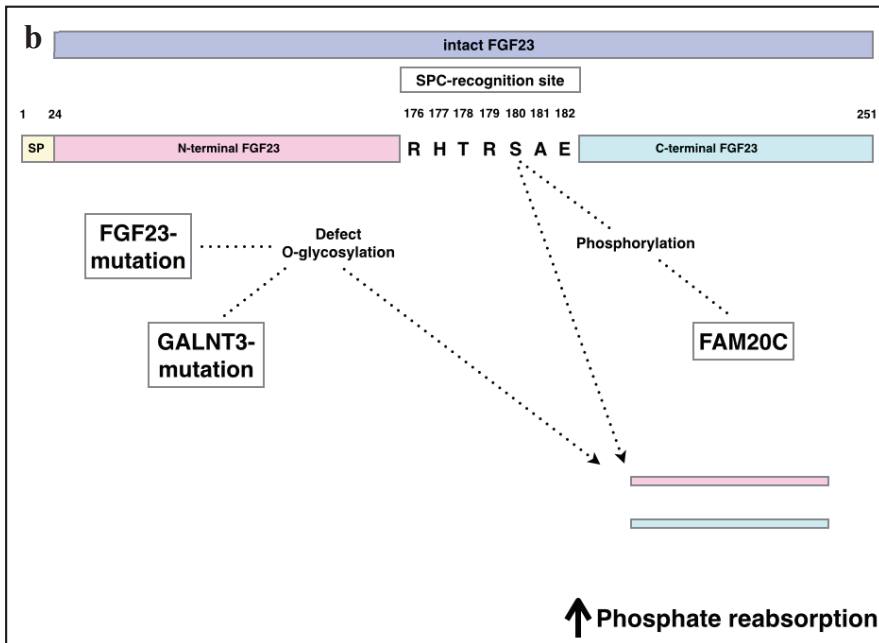
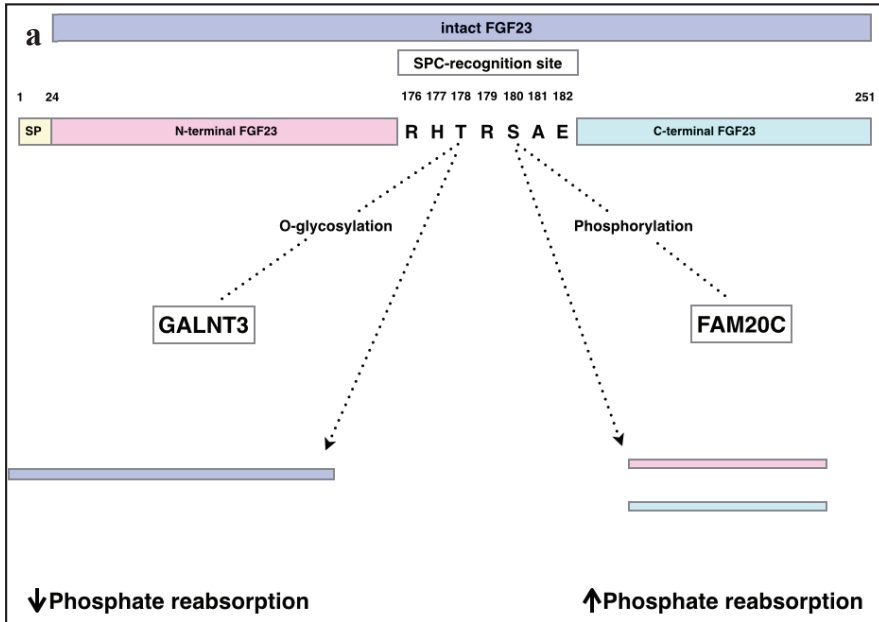
The two affected brothers in our study carried a p.T268M missense mutation in *FAM20C*, which has later been shown to give a partially functional protein product (247). The boys also carried a nonsense mutation in *FAM20C*, p.Y305X, predicted to give truncated, nonfunctional protein. The fact that the boys had one copy of the *FAM20C* gene encoding a partially functional protein, might explain their milder phenotype. The parents and half brother were all clinically and biochemically unaffected carriers, indicating that one normal copy of the gene is sufficient to retain protein function.

We were the first to show increased serum levels of intact FGF23 in patients with *FAM20C* mutation (178). The FAM20C protein is also directly involved in the regulation of FGF23, by phosphorylation of the serine in position 180 of the FGF23 protein (247). FGF23 is normally deactivated by proteolytic cleavage at the subtilisin-like proprotein convertase (SPC) site, ¹⁷⁶RHTR¹⁷⁹/S¹⁸⁰AE¹⁸²(56) (Figure 9). However, the O-glycosylation of T¹⁷⁸ within this SPC site by the GalNAcT3 enzyme stabilizes FGF23, and prevents proteolytic degradation (56). Within the SPC site, FGF23 also harbors the S-x-E-motif recognized by FAM20C. The T268M missense mutation

identified by our group has later been shown by others to lead to a partial reduction in the ability of FAM20C to phosphorylate FGF23 at S¹⁸⁰ (247). The T268M variant is located within the glycine-rich loop responsible for the binding of nucleotides, and leads to partial inhibition of O-glycosylation of FGF23 at position T¹⁷⁸ (247). The lack of phosphorylation of FGF23 by FAM20C can account for the increased serum levels of intact FGF23 found in humans (178) and mice (248) with *FAM20C* mutations.

Despite many similarities in phenotype between human and murine subjects with *FAM20C* mutations, the skeletal phenotype is not straightforward compatible in the two species. *Fam20c* KO mice show severe hypophosphatemic rickets, while generalized osteosclerosis is reported in humans with *FAM20C* mutations, including lethal variants of Raine syndrome. However, in a recent report, a 61 year old man with Raine syndrome was described to have hypophosphatemia and renal phosphate wasting associated with calcification of the posterior longitudinal ligament and increased bone mineral densities of the femoral neck, while a bone biopsy showed large areas of osteomalacia surrounding osteocytes (249). Such periosteocytic hypomineralization is typically described in bone biopsies from individuals with XLHR (250).

Taken together, FAM20C has both pro-mineralizing and anti-mineralizing properties, and in humans this is reflected in the divergent effect of *FAM20C* mutations in human teeth versus human bone. In mice however, *Fam20c* mutations seem to cause a hypomineralized phenotype in both teeth and skeleton. Although there are many details concerning the role of FAM20C in tissue mineralization yet to be clarified, our work has been important for linking the observations from in vitro- and animal studies to human disease. *FAM20C* related hereditary hypophosphatemia adds to the group of FGF23-dependent hypophosphatemic disorders.



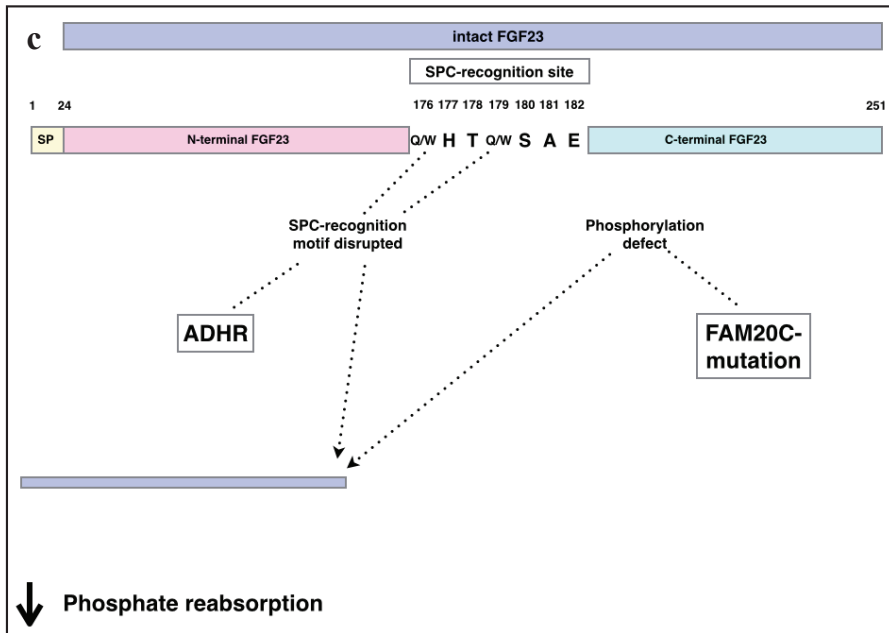


Figure 9 Glycosylation and phosphorylation of FGF23

Regulation of FGF23 break-down by the balance between O-glycosylation and phosphorylation of amino acids within the SPC-recognition site. a) In the normal state there is a balance between O-glycosylation and phosphorylation of FGF23 to ensure a proper balance between phosphate reabsorption and phosphate excretion. b) In states of defective O-glycosylation, as in *FGF23*- or *GALNT3* mutations, FGF23 is predominantly phosphorylated and prone to enzymatic degradation. This favors phosphate reabsorption. c) In cases of *FAM20C* mutation, FGF23 is predominantly O-glycosylated at the SPC site, and thus protected from enzymatic degradation. This favors phosphaturia.

5.2.3 Hereditary hyperphosphatemia illustrating the janus face of genes involved in phosphate regulation – Paper III

In paper III we describe two adult siblings with hereditary hyperphosphatemia due to a homozygous novel mutation in the *GALNT3* gene. The male had a phenotype predominated by hyperphosphatemic familial tumoral calcinosis (HFTC), while the female had a phenotype of hyperphosphatemic hyperostosis syndrome (HHS), but also evidence of calcific tumors characteristic for HFTC. Both had elevated levels of serum phosphate in combination with an increased tubular maximum reabsorption of phosphate relative to glomerular filtration rate (TmP/GFR).

Earlier HFTC and HHS were thought to be two different conditions. However the observation that both are caused by mutations in the same genes (139), that both phenotypes can occur in one pedigree and that some subjects show a mixed phenotype, has led to the current view, that these phenotypes represent different presentation of the same condition (180, 251, 252) collectively referred to as HFTC (OMIM #211900).

The prevalence of HFTC/HHS has, to the best of our knowledge, not been reported. Through our literature search, as described in paper III, we were able to identify a total of 56 genetically verified cases of HFTC/HHS by 2013. In addition to the two cases described in paper III, we were able to identify one additional case in Norway, described in an earlier case report (253). By repeated contact with medical and pediatric departments in Norwegian hospitals, we were not able to identify more than these three cases. The number of inhabitants in Norway by January 1st 2014 was 5 109 000, which gives a national prevalence of this condition of 0.06 in 100.000 inhabitants. However, as described in paper III, there are often long symptom free intervals, and symptoms may be nonspecific, especially in the HHS phenotype, there is a great possibility of under-diagnosis in this condition. In fact, the female described in paper III, who had mainly symptoms of HHS in adulthood, may not been diagnosed, had it not been for the more obvious HFTC phenotype observed in her

brother. Monogenic hyperphosphatemia is probably an underdiagnosed cause of symptomatic and non-symptomatic mineralization disorders.

The siblings we describe had quite different manifestations of the same disease. The male had his first large calcific tumor at the elbow in adolescence, and once this was removed, he was apparently symptom free until the age of 37, when he had a large calcific tumor in the gluteal region. The diagnostic work-up suggested a clinical diagnosis of HFTC, although the genetic diagnosis was not made until inclusion in our study. The female had non-specific rheumatic symptoms throughout adulthood, and was diagnosed with hyperphosphatemia after screening of the males' first-degree relatives. In retrospect, however, the medical files for the female described several attacks of diaphysitis in childhood, and also an episode of cutaneous nodules on the scalp in infancy. During adulthood she had dental and eye manifestations and calcifications of the placenta was noted in her first pregnancy. Later she had stiffness and pain in joints and muscles, and small calcific tumors in the subcutaneous tissue of hands and feet recognized on skeletal x-ray. The male also had dental manifestations and eye symptoms. Our findings support the observations made by others, that HFTC and HHS are probably to phenotypic variants for the same disease. Through our review of all 56 published cases of genetically verified HFTC and/or HHS, we showed that the combined phenotype is more common than previously recognized, adding further support to the theory that this is one disease with a spectrum of manifestations.

HFTC/HHS is caused by mutations in *FGF23* (143), *GALNT3* (138) or *KL* (254), and the common pathophysiological mechanism is a reduced level of intact FGF23 (143). The levels of c-terminal FGF23 (cFGF23) are elevated, indicating increased break down of FGF23. This is the opposite of what is found in FGF23-dependent hereditary hypophosphatemia, where break down of FGF23 is prevented. The two groups of conditions are therefore often considered mirror images of each other, and biochemically this is true. However, as demonstrated in Table 7 (Appendix), phenotypically the image becomes more confusing. An interesting observation is that

the pattern of ectopic calcifications seen in the hyperphosphatemic condition HFTC/HHS, partially resembles the patterns of calcifications seen in FGF23 dependent hypophosphatemic conditions. The hyperostosis of long bones characteristic of the HHS phenotype, is also seen in hereditary hypophosphatemia caused by mutations in *FAM20C* and *DMP1* (96, 255), as well as in XLHR (196). Furthermore, enthesopathies are quite prevalent in adults with XLHR (196, 256).

In the same way that phosphate and vitamin D supplements in HR cannot fully correct the skeletal mineralization defects, the various approaches to reduce serum phosphate seem to have variable effect in controlling ectopic calcifications in HFTC/HHS (257). In the collection of case reports, some authors report effect of phosphate lowering treatment in reducing calcific tumor size (257), but this might as well reflect the temporal fluctuations in disease course as seen in our patients before treatment and also reported by others (258). As discussed in section 3.2.2 regarding hereditary hypophosphatemia, the individual differences in phenotype between patients with the same genotype, even within the same family, probably reflects that physiological and pathological mineralization of tissues are complex processes. Hypo- and hyperphosphatemia are directly involved in pathogenesis in the two groups of diseases, but are also markers of FGF23 dysregulation and mineralization disturbance.

Targeted therapy to increase the levels of FGF23 is not currently available. Experiments in mice have shown that overexpression of α -Klotho leads to increased levels of FGF23 (259). However, the negative effects of pathological levels of FGF23 discussed earlier, suggests a narrow therapeutic range for measures to increase FGF23.

5.2.4 FGF23 dysregulation – new knowledge on pathophysiological mechanisms in mineralization

The last ten to twenty years, the identification of genes involved in monogenic phosphate balance disorders has led to new knowledge on the physiology and pathophysiology of phosphate regulation and mineralization process. The discovery of the phosphatonin FGF23 and of bone as an endocrine organ, has been important not only for understanding the monogenic phosphate balance disorders, but also disordered mineralization seen in other conditions, as chronic renal failure.

Collectively, our observations suggest that adequate treatment with phosphate and vitamin D can only partially improve growth and heal mineralization defect in XLHR. It has been speculated if FGF23 may play a role in skeletal and mineralization metabolism independent from its role as a phosphatonin (135). Pathologically elevated levels of FGF23 have been associated with left ventricular hypertrophy (171, 172), endothelial dysfunction (173), atherosclerosis (174), and increased risk of mortality in chronic kidney disease (168) and persons with coronary heart disease (176). Treatment with phosphate triggers a vicious cycle of production and release of FGF23 (260) and PTH (37), which further negative effect on skeletal metabolism. Targeted therapy to reduce the levels of FGF23 would be a more rational approach, and in fact monoclonal anti-FGF23 antibodies are currently being tested in adult patients with XLHR. So far the results on phosphate metabolism are promising, and the treatment is considered safe (136, 261). The treatment has not been tested in children, however, and its effect on rickets and longitudinal growth in humans is not known, but in mice FGF23 neutralizing antibodies has been shown to correct growth deficiency (262). At the same time it is important to be aware of diseases associated with a lack of FGF23, as exemplified by the hyperphosphatemia and ectopic calcifications seen in hyperphosphatemic familial tumoral calcinosis (HFTC). At least theoretically, a balanced reduction of FGF23 levels in hereditary hypophosphatemia will improve mineralization defects and longitudinal growth more efficiently than by correcting only hypophosphatemia itself.

An important observation in hereditary hypo- and hyperphosphatemia is that the correction of serum phosphate levels towards normal, do not necessarily correct the disordered mineralization seen in these conditions. Also, the overlap in skeletal phenotypes between hypo- and hyperphosphatemic conditions illustrates the complexity of the bone and tissue mineralizing process. For instance, *ARHR1* has previously been associated with rickets and short stature, as well as calcifications of the posterior longitudinal ligament and hyperostosis of the skull base (93). Furthermore, patients with *FAM20C* mutations, both in our cohort, and later also described by others have elevated levels of FGF23 (249), but no rickets or short stature, but rather show ectopic calcifications and hyperostosis. As discussed earlier, a normal serum phosphate level is probably not sufficient to ensure mineralization balance in the body, while the phosphorylation state of proteins can alter the balance between pro- and anti-mineralizing molecules. For instance osteopontin (OPN) is a pro-mineralizing protein in its non-phosphorylated state, while phosphorylation gives it anti-mineralizing properties (245). The same is seen in non-phosphorylated and phosphorylated ASARM peptides, which are the break down product of the SIBLING proteins (78, 79). In DMP1, the opposite is probably true, as phosphorylated DMP1 has been shown to have pro-mineralizing effects (246). As discussed in section 5.2.1, sequence variants in *FGF23* have been associated with lower levels of serum phosphate and lower renal tubular maximum reabsorption rate of phosphate to glomerular filtration rate (TmP/GFR) (206), and lower plasma intact PTH in healthy children and adults (207). Sequence variants in *FGF23* and several other genes encoding proteins involved in bone metabolism, could affect sites of phosphorylation, and change their pro- versus anti-mineralizing properties, explaining the complex pathophysiology of the inherited phosphate balance disorders.

Table 7 of the appendix gives an overview of the hereditary monogenic conditions associated with dysregulation of FGF23 and phosphate reabsorption, and abnormal mineralization.

6. Conclusions

The group of hereditary hypophosphatemias associated with rickets, and previously referred to as hypophosphatemic rickets, also includes conditions without clinical manifest skeletal disease, and we propose the term hereditary hypophosphatemia to depict this group of conditions.

To the best of our knowledge, this is the first study of a national cohort of children with hereditary hypophosphatemia. Our study shows that the prevalence of XLHR of 1 in 60.000 Norwegian children is lower than reported in earlier studies.

Despite adequate treatment, all XLHR children had evidence of rickets or skeletal axis deviation at some point during follow up, and most had height z-scores less than average. A high proportion of XLHR patients had elevated PTH before the start of treatment with phosphate and alfacalcidol. There was a high prevalence of low-grade nephrocalcinosis, but only one observation of compromised renal function, which was transient.

We have shown that patients with *FAM20C* mutations may have pathological serum levels of FGF23, and that *FAM20C* mutations are associated with autosomal recessive FGF23-dependent hereditary hypophosphatemia.

We have also found a novel mutation in *GALNT3* associated with HFTC and HHS, and brought further support to theory that these conditions are two syndromes in the spectrum of FGF23 related hereditary hyperphosphatemias.

7. Future perspectives

The discovering of bone as an endocrine organ has brought new understanding to the field of phosphate metabolism generally, and hereditary phosphate balance disorders specifically. The differentiation between FGF23 dependent and –independent hereditary hypophosphatemia will be important, as FGF23 targeted therapy is currently in the pipeline; recombinant FGF23 neutralizing antibodies have shown to be safe and have beneficial effects in adults with XLHR (136, 261). If proven safe for use in children, FGF23 targeted therapy may also have implication for other groups of patients, as exemplified by chronic renal failure, in which elevated FGF23 plays an important role in morbidity for this large group of patients. To efficiently be able to select the patients eligible for FGF23 targeted therapy there is also a need for more robust FGF23 assays.

Through exome sequencing, we were able to show that mutations in the protein kinase *FAM20C* are associated with FGF23 dependent hereditary hypophosphatemia, and our finding has given support to studies showing that *FAM20C*, through phosphorylation, is a regulator of FGF23. Through increasing efficiency and availability of genetic analysis, there may be a possibility of finding the genetic cause in most children with hereditary phosphate balance disorders. The highly complex mechanisms of phosphate homeostasis and regulation of mineralization, involve several genes and proteins that might be linked to monogenic phosphate balance disorders.

Hopefully, the discovery of novel genes and novel mechanisms will contribute to a greater understanding of the regulation of phosphate metabolism and physiological and pathological mineralization processes. This includes not only disorders of skeletal mineralization, but also pathological vascular calcification involved in cardiovascular diseases as hypertension, myocardial infarction, stroke and renal function.

Through our search for families with hereditary hypophosphatemia, we identified two siblings with HFTC/HHS, who had symptoms from childhood, but were not diagnosed until late adulthood. We suggest that this condition is underdiagnosed because of the highly variable clinical manifestation and large fluctuation of symptoms over time, with long symptom free intervals. Currently available phosphate lowering therapy is probably not sufficient to control the ectopic calcification. Targeted therapy to increase the levels of FGF23 is not currently available and would have to be balanced against the negative effects of pathologically elevated levels of FGF23. However, the long-term prognosis of HFTC/HHS with currently available treatment is not known, and thus the indication for targeted therapy is difficult to determine.

For children with hereditary hypophosphatemia, early recognition, genetic diagnosis and targeted therapy would probably give better opportunities for normal growth, and a therapeutic regimen that is more easy to comply with, and less risk of bothersome and potentially serious complications.

8. References

1. Albright FB, A.M.; Bloomberg, E. Rickets resistant to vitamin D therapy. *Am J Dis Child*. 1937;54:529-47.
2. Smerdon GT. Daniel Whistler and the English disease; a translation and biographical note. *J Hist Med Allied Sci*. 1950;5(4):397-415.
3. Oxford English Dictionary. Available from: <http://www.oed.com.pva.uib.no/view/Entry/165593?redirectedFrom=rickets-eid>.
4. Wacker M, Holick MF. Sunlight and Vitamin D: A global perspective for health. *Dermatoendocrinol*. 2013;5(1):51-108.
5. Kloster J. The distribution and frequency of rickets in one of the fishery districts of Finmark and relation of diet to the disorder. Uppsala, 1931. 82 s. p.
6. Glorieux F, Chabot G, Tau C. Familial Hypophosphatemic Rickets: Pathophysiology and Medical Management. Nestlé Nutrition Workshop Series. 1991;21:185-200.
7. Winters RW, Graham JB, Williams TF, Mc FV, Burnett CH. A genetic study of familial hypophosphatemia and vitamin D resistant rickets with a review of the literature. *Medicine (Baltimore)*. 1958;37(2):97-142.
8. Hsia DY, Kraus M, Samuels J. Genetic studies on vitamin D resistant rickets (familial hypophosphatemia). *Am J Hum Genet*. 1959;11(2 Part 1):156-65.
9. Feng JQ, Ward LM, Liu S, Lu Y, Xie Y, Yuan B, et al. Loss of DMP1 causes rickets and osteomalacia and identifies a role for osteocytes in mineral metabolism. *Nat Genet*. 2006;38(11):1310-5.
10. Lorenz-Depiereux B, Bastepe M, Benet-Pages A, Amyere M, Wagenstaller J, Muller-Barth U, et al. DMP1 mutations in autosomal recessive hypophosphatemia implicate a bone matrix protein in the regulation of phosphate homeostasis. *Nat Genet*. 2006;38(11):1248-50.
11. Eicher EM, Southard JL, Scriver CR, Glorieux FH. Hypophosphatemia: mouse model for human familial hypophosphatemic (vitamin D-resistant) rickets. *Proc Natl Acad Sci U S A*. 1976;73(12):4667-71.
12. Read AP, Thakker RV, Davies KE, Mountford RC, Brenton DP, Davies M, et al. Mapping of human X-linked hypophosphatemic rickets by multilocus linkage analysis. *Hum Genet*. 1986;73(3):267-70.
13. Bringham FRD, M.B.; Krane, S.M.; Kronenberg, H.M. Bone and Mineral Metabolism in Health and Disease. In: Kasper DL, editor. *Harrison's principles of internal medicine*. 16th ed: Mc Graw Hill; 2005. p. 2238-48.
14. Greenbaum LA. Electrolyte and Acid-Base Disorders. In: Kliegman RMea, editor. *Nelson textbook of pediatrics*. 18 ed: Saunders; 2007. p. 267-309.
15. Magagnin S, Werner A, Markovich D, Sorribas V, Stange G, Biber J, et al. Expression cloning of human and rat renal cortex Na/Pi cotransport. *Proc Natl Acad Sci U S A*. 1993;90(13):5979-83.
16. Hartmann CM, Hewson AS, Kos CH, Hilfiker H, Soumounou Y, Murer H, et al. Structure of murine and human renal type II Na⁺-phosphate cotransporter genes (Npt2 and NPT2). *Proc Natl Acad Sci U S A*. 1996;93(14):7409-14.

17. Kavanaugh MP, Miller DG, Zhang W, Law W, Kozak SL, Kabat D, et al. Cell-surface receptors for gibbon ape leukemia virus and amphotropic murine retrovirus are inducible sodium-dependent phosphate symporters. *Proc Natl Acad Sci U S A*. 1994;91(15):7071-5.
18. Virkki LV, Biber J, Murer H, Forster IC. Phosphate transporters: a tale of two solute carrier families. *Am J Physiol Renal Physiol*. 2007;293(3):F643-54.
19. Reimer RJ, Edwards RH. Organic anion transport is the primary function of the SLC17/type I phosphate transporter family. *Pflugers Arch*. 2004;447(5):629-35.
20. Madjdpour C, Bacic D, Kaissling B, Murer H, Biber J. Segment-specific expression of sodium-phosphate cotransporters NaPi-IIa and -IIc and interacting proteins in mouse renal proximal tubules. *Pflugers Arch*. 2004;448(4):402-10.
21. Tenenhouse HS. Regulation of phosphorus homeostasis by the type iia na/phosphate cotransporter. *Annu Rev Nutr*. 2005;25:197-214.
22. Segawa H, Yamanaka S, Ito M, Kuwahata M, Shono M, Yamamoto T, et al. Internalization of renal type IIc Na-Pi cotransporter in response to a high-phosphate diet. *Am J Physiol Renal Physiol*. 2005;288(3):F587-96.
23. Hilfiker H, Hattenhauer O, Traebert M, Forster I, Murer H, Biber J. Characterization of a murine type II sodium-phosphate cotransporter expressed in mammalian small intestine. *Proc Natl Acad Sci U S A*. 1998;95(24):14564-9.
24. Sabbagh Y, O'Brien SP, Song W, Boulanger JH, Stockmann A, Arbeeny C, et al. Intestinal npt2b plays a major role in phosphate absorption and homeostasis. *J Am Soc Nephrol*. 2009;20(11):2348-58.
25. Hattenhauer O, Traebert M, Murer H, Biber J. Regulation of small intestinal Na-P(i) type IIb cotransporter by dietary phosphate intake. *Am J Physiol*. 1999;277(4 Pt 1):G756-62.
26. Corut A, Senyigit A, Ugur SA, Altin S, Ozcelik U, Calisir H, et al. Mutations in SLC34A2 cause pulmonary alveolar microlithiasis and are possibly associated with testicular microlithiasis. *Am J Hum Genet*. 2006;79(4):650-6.
27. Huqun, Izumi S, Miyazawa H, Ishii K, Uchiyama B, Ishida T, et al. Mutations in the SLC34A2 gene are associated with pulmonary alveolar microlithiasis. *Am J Respir Crit Care Med*. 2007;175(3):263-8.
28. Olah Z, Lehel C, Anderson WB, Eiden MV, Wilson CA. The cellular receptor for gibbon ape leukemia virus is a novel high affinity sodium-dependent phosphate transporter. *J Biol Chem*. 1994;269(41):25426-31.
29. Yoshiko Y, Candelieri GA, Maeda N, Aubin JE. Osteoblast autonomous Pi regulation via Pit1 plays a role in bone mineralization. *Mol Cell Biol*. 2007;27(12):4465-74.
30. Villa-Bellosta R, Ravera S, Sorribas V, Stange G, Levi M, Murer H, et al. The Na⁺-Pi cotransporter PiT-2 (SLC20A2) is expressed in the apical membrane of rat renal proximal tubules and regulated by dietary Pi. *Am J Physiol Renal Physiol*. 2009;296(4):F691-9.
31. Segawa H, Onitsuka A, Furutani J, Kaneko I, Aranami F, Matsumoto N, et al. Npt2a and Npt2c in mice play distinct and synergistic roles in inorganic phosphate metabolism and skeletal development. *Am J Physiol Renal Physiol*. 2009;297(3):F671-8.

32. Imel EA, Carpenter TO. A Practical Clinical Approach to Paediatric Phosphate Disorders. *Endocr Dev.* 2015;28:134-61.
33. Nissenson RAJ, H. Parathyroid Hormone. In: Rosen CJ, editor. *Primer on the Metabolic Bone Diseases and Disorders of Mineral Metabolism*. 1. Eight ed: Wiley-Blackwell; 2013. p. 208-14.
34. de Groot T, Lee K, Langeslag M, Xi Q, Jalink K, Bindels RJ, et al. Parathyroid hormone activates TRPV5 via PKA-dependent phosphorylation. *J Am Soc Nephrol.* 2009;20(8):1693-704.
35. Bacic D, Lehir M, Biber J, Kaissling B, Murer H, Wagner CA. The renal Na⁺/phosphate cotransporter NaPi-IIa is internalized via the receptor-mediated endocytic route in response to parathyroid hormone. *Kidney Int.* 2006;69(3):495-503.
36. Segawa H, Yamanaka S, Onitsuka A, Tomoe Y, Kuwahata M, Ito M, et al. Parathyroid hormone-dependent endocytosis of renal type IIc Na-Pi cotransporter. *Am J Physiol Renal Physiol.* 2007;292(1):F395-403.
37. Reiss E, Canterbury JM, Bercovitz MA, Kaplan EL. The role of phosphate in the secretion of parathyroid hormone in man. *J Clin Invest.* 1970;49(11):2146-9.
38. Moallem E, Kilav R, Silver J, Naveh-Many T. RNA-Protein binding and post-transcriptional regulation of parathyroid hormone gene expression by calcium and phosphate. *J Biol Chem.* 1998;273(9):5253-9.
39. Silva BC, Costa AG, Cusano NE, Kousteni S, Bilezikian JP. Catabolic and anabolic actions of parathyroid hormone on the skeleton. *J Endocrinol Invest.* 2011;34(10):801-10.
40. Saito H, Maeda A, Ohtomo S, Hirata M, Kusano K, Kato S, et al. Circulating FGF-23 is regulated by 1alpha,25-dihydroxyvitamin D3 and phosphorus in vivo. *J Biol Chem.* 2005;280(4):2543-9.
41. Perwad F, Zhang MY, Tenenhouse HS, Portale AA. Fibroblast growth factor 23 impairs phosphorus and vitamin D metabolism in vivo and suppresses 25-hydroxyvitamin D-1alpha-hydroxylase expression in vitro. *Am J Physiol Renal Physiol.* 2007;293(5):F1577-83.
42. Farrow EG, Davis SI, Summers LJ, White KE. Initial FGF23-mediated signaling occurs in the distal convoluted tubule. *J Am Soc Nephrol.* 2009;20(5):955-60.
43. Andrukhova O, Smorodchenko A, Egerbacher M, Streicher C, Zeitz U, Goetz R, et al. FGF23 promotes renal calcium reabsorption through the TRPV5 channel. *EMBO J.* 2014;33(3):229-46.
44. Holick MG, M. Vitamin D: production, metabolism, mechanism of action, and clinical requirements. In: Rosen CJ, editor. *Primer on the metabolic bone diseases and disorders of mineral metabolism*. 8th ed: Wiley-Blackwell; 2013.
45. Wasserman RH, Fullmer CS. Vitamin D and intestinal calcium transport: facts, speculations and hypotheses. *J Nutr.* 1995;125(7 Suppl):1971S-9S.
46. Amling M, Priemel M, Holzmann T, Chapin K, Rueger JM, Baron R, et al. Rescue of the skeletal phenotype of vitamin D receptor-ablated mice in the setting of normal mineral ion homeostasis: formal histomorphometric and biomechanical analyses. *Endocrinology.* 1999;140(11):4982-7.
47. Itoh N, Ornitz DM. Fibroblast growth factors: from molecular evolution to roles in development, metabolism and disease. *J Biochem.* 2011;149(2):121-30.

-
48. Goldfarb M, Schoorlemmer J, Williams A, Diwakar S, Wang Q, Huang X, et al. Fibroblast growth factor homologous factors control neuronal excitability through modulation of voltage-gated sodium channels. *Neuron*. 2007;55(3):449-63.
 49. Tekin M, Hismi BO, Fitoz S, Ozdag H, Cengiz FB, Sirmaci A, et al. Homozygous mutations in fibroblast growth factor 3 are associated with a new form of syndromic deafness characterized by inner ear agenesis, microtia, and microdontia. *Am J Hum Genet*. 2007;80(2):338-44.
 50. Trarbach EB, Abreu AP, Silveira LF, Garmes HM, Baptista MT, Teles MG, et al. Nonsense mutations in FGF8 gene causing different degrees of human gonadotropin-releasing deficiency. *J Clin Endocrinol Metab*. 2010;95(7):3491-6.
 51. Riley BM, Mansilla MA, Ma J, Daack-Hirsch S, Maher BS, Raffensperger LM, et al. Impaired FGF signaling contributes to cleft lip and palate. *Proc Natl Acad Sci U S A*. 2007;104(11):4512-7.
 52. Goetz R, Beenken A, Ibrahim OA, Kalinina J, Olsen SK, Eliseenkova AV, et al. Molecular insights into the klotho-dependent, endocrine mode of action of fibroblast growth factor 19 subfamily members. *Mol Cell Biol*. 2007;27(9):3417-28.
 53. Yamashita T, Yoshioka M, Itoh N. Identification of a novel fibroblast growth factor, FGF-23, preferentially expressed in the ventrolateral thalamic nucleus of the brain. *Biochem Biophys Res Commun*. 2000;277(2):494-8.
 54. Consortium A. Autosomal dominant hypophosphataemic rickets is associated with mutations in FGF23. *Nat Genet*. 2000;26(3):345-8.
 55. Shimada T, Mizutani S, Muto T, Yoneya T, Hino R, Takeda S, et al. Cloning and characterization of FGF23 as a causative factor of tumor-induced osteomalacia. *Proc Natl Acad Sci U S A*. 2001;98(11):6500-5.
 56. White KE, Carn G, Lorenz-Depiereux B, Benet-Pages A, Strom TM, Econs MJ. Autosomal-dominant hypophosphatemic rickets (ADHR) mutations stabilize FGF-23. *Kidney Int*. 2001;60(6):2079-86.
 57. Kolek OI, Hines ER, Jones MD, LeSueur LK, Lipko MA, Kiela PR, et al. 1 α ,25-Dihydroxyvitamin D3 upregulates FGF23 gene expression in bone: the final link in a renal-gastrointestinal-skeletal axis that controls phosphate transport. *Am J Physiol Gastrointest Liver Physiol*. 2005;289(6):G1036-42.
 58. Urakawa I, Yamazaki Y, Shimada T, Iijima K, Hasegawa H, Okawa K, et al. Klotho converts canonical FGF receptor into a specific receptor for FGF23. *Nature*. 2006;444(7120):770-4.
 59. Kurosu H, Ogawa Y, Miyoshi M, Yamamoto M, Nandi A, Rosenblatt KP, et al. Regulation of fibroblast growth factor-23 signaling by klotho. *J Biol Chem*. 2006;281(10):6120-3.
 60. Gattineni J, Bates C, Twombly K, Dwarakanath V, Robinson ML, Goetz R, et al. FGF23 decreases renal NaPi-2a and NaPi-2c expression and induces hypophosphatemia in vivo predominantly via FGF receptor 1. *Am J Physiol Renal Physiol*. 2009;297(2):F282-91.
 61. Andrukhova O, Zeitz U, Goetz R, Mohammadi M, Lanske B, Erben RG. FGF23 acts directly on renal proximal tubules to induce phosphaturia through activation of the ERK1/2-SGK1 signaling pathway. *Bone*. 2012;51(3):621-8.
 62. Deliot N, Hernando N, Horst-Liu Z, Gisler SM, Capuano P, Wagner CA, et al. Parathyroid hormone treatment induces dissociation of type IIa Na⁺-P(i)

-
- cotransporter-Na⁺/H⁺ exchanger regulatory factor-1 complexes. *Am J Physiol Cell Physiol.* 2005;289(1):C159-67.
63. Shimada T, Hasegawa H, Yamazaki Y, Muto T, Hino R, Takeuchi Y, et al. FGF-23 is a potent regulator of vitamin D metabolism and phosphate homeostasis. *J Bone Miner Res.* 2004;19(3):429-35.
64. Sadler TW. *Langman's Medical Embryology.* 9th ed: Lippincott, Williams and Wilkins; 2004.
65. Burdan F, Szumilo J, Korobowicz A, Farooquee R, Patel S, Patel A, et al. Morphology and physiology of the epiphyseal growth plate. *Folia Histochem Cytobiol.* 2009;47(1):5-16.
66. Tiosano D, Hochberg Z. Hypophosphatemia: the common denominator of all rickets. *J Bone Miner Metab.* 2009;27(4):392-401.
67. Clarke B. Normal bone anatomy and physiology. *Clin J Am Soc Nephrol.* 2008;3 Suppl 3:S131-9.
68. Golub EE. Role of matrix vesicles in biomineralization. *Biochim Biophys Acta.* 2009;1790(12):1592-8.
69. Anderson HC. Electron microscopic studies of induced cartilage development and calcification. *J Cell Biol.* 1967;35(1):81-101.
70. Alford AI, Kozloff KM, Hankenson KD. Extracellular matrix networks in bone remodeling. *Int J Biochem Cell Biol.* 2015;65:20-31.
71. Davies M, Stanbury SW. THE RHEUMATIC MANIFESTATIONS OF METABOLIC BONE-DISEASE. *Clin Rheum Dis.* 1981;7(3):595-646.
72. Beck-Nielsen SS, Brock-Jacobsen B, Gram J, Brixen K, Jensen TK. Incidence and prevalence of nutritional and hereditary rickets in southern Denmark. *Eur J Endocrinol.* 2009;160(3):491-7.
73. Bruneau N, Lombardo D. Chaperone function of a Grp 94-related protein for folding and transport of the pancreatic bile salt-dependent lipase. *J Biol Chem.* 1995;270(22):13524-33.
74. Sabbagh Y, Boileau G, Campos M, Carmona AK, Tenenhouse HS. Structure and function of disease-causing missense mutations in the PHEX gene. *The Journal of clinical endocrinology and metabolism.* 2003;88(5):2213-22.
75. Jonsson KB, Zahradnik R, Larsson T, White KE, Sugimoto T, Imanishi Y, et al. Fibroblast growth factor 23 in oncogenic osteomalacia and X-linked hypophosphatemia. *N Engl J Med.* 2003;348(17):1656-63.
76. Bastepe M, Juppner H. Inherited hypophosphatemic disorders in children and the evolving mechanisms of phosphate regulation. *Rev Endocr Metab Disord.* 2008;9(2):171-80.
77. Juppner H. Novel regulators of phosphate homeostasis and bone metabolism. *Therapeutic apheresis and dialysis : official peer-reviewed journal of the International Society for Apheresis, the Japanese Society for Apheresis, the Japanese Society for Dialysis Therapy.* 2007;11 Suppl 1:S3-22.
78. Martin A, David V, Laurence JS, Schwarz PM, Lafer EM, Hedge AM, et al. Degradation of MEPE, DMP1, and release of SIBLING ASARM-peptides (minhibins): ASARM-peptide(s) are directly responsible for defective mineralization in HYP. *Endocrinology.* 2008;149(4):1757-72.

-
79. Addison WN, Nakano Y, Loisel T, Crine P, McKee MD. MEPE-ASARM peptides control extracellular matrix mineralization by binding to hydroxyapatite: an inhibition regulated by PHEX cleavage of ASARM. *J Bone Miner Res*. 2008;23(10):1638-49.
 80. Yuan B, Takaiwa M, Clemens TL, Feng JQ, Kumar R, Rowe PS, et al. Aberrant PheX function in osteoblasts and osteocytes alone underlies murine X-linked hypophosphatemia. *The Journal of clinical investigation*. 2008;118(2):722-34.
 81. Dixon PH, Christie PT, Wooding C, Trump D, Grieff M, Holm I, et al. Mutational analysis of PHEX gene in X-linked hypophosphatemia. *J Clin Endocrinol Metab*. 1998;83(10):3615-23.
 82. Ichikawa S, Traxler EA, Estwick SA, Curry LR, Johnson ML, Sorenson AH, et al. Mutational survey of the PHEX gene in patients with X-linked hypophosphatemic rickets. *Bone*. 2008;43(4):663-6.
 83. Makitie O, Doria A, Kooh SW, Cole WG, Daneman A, Sochett E. Early treatment improves growth and biochemical and radiographic outcome in X-linked hypophosphatemic rickets. *J Clin Endocrinol Metab*. 2003;88(8):3591-7.
 84. Carpenter TO. Primary Disorders of Phosphate Metabolism. In: De Groot LJ, Beck-Peccoz P, Chrousos G, Dungan K, Grossman A, Hershman JM, et al., editors. *Endotext*. South Dartmouth (MA)2000.
 85. Batra P, Tejani Z, Mars M. X-linked hypophosphatemia: dental and histologic findings. *J Can Dent Assoc*. 2006;72(1):69-72.
 86. Carpenter TO. New perspectives on the biology and treatment of X-linked hypophosphatemic rickets. *Pediatr Clin North Am*. 1997;44(2):443-66.
 87. Lewy JE, Cabana EC, Repetto HA, Canterbury JM, Reiss E. Serum parathyroid hormone in hypophosphatemic vitamin D-resistant rickets. *J Pediatr*. 1972;81(2):294-300.
 88. Rasmussen H, Pechet M, Anast C, Mazur A, Gertner J, Broadus AE. Long-term treatment of familial hypophosphatemic rickets with oral phosphate and 1 alpha-hydroxyvitamin D3. *J Pediatr*. 1981;99(1):16-25.
 89. Carpenter TO, Mitnick MA, Ellison A, Smith C, Insogna KL. Nocturnal hyperparathyroidism: a frequent feature of X-linked hypophosphatemia. *J Clin Endocrinol Metab*. 1994;78(6):1378-83.
 90. Levy-Litan V, Hershkovitz E, Avizov L, Leventhal N, Bercovich D, Chalifa-Caspi V, et al. Autosomal-recessive hypophosphatemic rickets is associated with an inactivation mutation in the ENPP1 gene. *Am J Hum Genet*. 2010;86(2):273-8.
 91. Lorenz-Depiereux B, Schnabel D, Tiosano D, Hausler G, Strom TM. Loss-of-function ENPP1 mutations cause both generalized arterial calcification of infancy and autosomal-recessive hypophosphatemic rickets. *Am J Hum Genet*. 2010;86(2):267-72.
 92. Koshida R, Yamaguchi H, Yamasaki K, Tsuchimochi W, Yonekawa T, Nakazato M. A novel nonsense mutation in the DMP1 gene in a Japanese family with autosomal recessive hypophosphatemic rickets. *J Bone Miner Metab*. 2010;28(5):585-90.
 93. Makitie O, Pereira RC, Kaitila I, Turan S, Bastepe M, Laine T, et al. Long-term clinical outcome and carrier phenotype in autosomal recessive

- hypophosphatemia caused by a novel DMP1 mutation. *J Bone Miner Res.* 2010;25(10):2165-74.
94. Turan S, Aydin C, Bereket A, Akcay T, Guran T, Yaralioglu BA, et al. Identification of a novel dentin matrix protein-1 (DMP-1) mutation and dental anomalies in a kindred with autosomal recessive hypophosphatemia. *Bone.* 2010;46(2):402-9.
95. Farrow EG, Davis SI, Ward LM, Summers LJ, Bubbear JS, Keen R, et al. Molecular analysis of DMP1 mutants causing autosomal recessive hypophosphatemic rickets. *Bone.* 2009;44(2):287-94.
96. Gannage-Yared MH, Makrythanasis P, Chouery E, Sobacchi C, Mehawej C, Santoni FA, et al. Exome sequencing reveals a mutation in DMP1 in a family with familial sclerosing bone dysplasia. *Bone.* 2014;68:142-5.
97. Beck-Nielsen SS, Brixen K, Gram J, Brusgaard K. Mutational analysis of PHEX, FGF23, DMP1, SLC34A3 and CLCN5 in patients with hypophosphatemic rickets. *J Hum Genet.* 2012;57(7):453-8.
98. Huq NL, Cross KJ, Ung M, Reynolds EC. A review of protein structure and gene organisation for proteins associated with mineralised tissue and calcium phosphate stabilisation encoded on human chromosome 4. *Arch Oral Biol.* 2005;50(7):599-609.
99. Rutsch F, Vaingankar S, Johnson K, Goldfine I, Maddux B, Schauerte P, et al. PC-1 nucleoside triphosphate pyrophosphohydrolase deficiency in idiopathic infantile arterial calcification. *Am J Pathol.* 2001;158(2):543-54.
100. Rutsch F, Ruf N, Vaingankar S, Toliat MR, Suk A, Hohne W, et al. Mutations in ENPP1 are associated with 'idiopathic' infantile arterial calcification. *Nat Genet.* 2003;34(4):379-81.
101. Rutsch F, Boyer P, Nitschke Y, Ruf N, Lorenz-Depierieux B, Wittkamp T, et al. Hypophosphatemia, hyperphosphaturia, and bisphosphonate treatment are associated with survival beyond infancy in generalized arterial calcification of infancy. *Circ Cardiovasc Genet.* 2008;1(2):133-40.
102. Hessle L, Johnson KA, Anderson HC, Narisawa S, Sali A, Goding JW, et al. Tissue-nonspecific alkaline phosphatase and plasma cell membrane glycoprotein-1 are central antagonistic regulators of bone mineralization. *Proc Natl Acad Sci U S A.* 2002;99(14):9445-9.
103. Meyer JL. Can biological calcification occur in the presence of pyrophosphate? *Arch Biochem Biophys.* 1984;231(1):1-8.
104. Johnson K, Polewski M, van Etten D, Terkeltaub R. Chondrogenesis mediated by PPi depletion promotes spontaneous aortic calcification in NPP1-/- mice. *Arterioscler Thromb Vasc Biol.* 2005;25(4):686-91.
105. Saito T, Shimizu Y, Hori M, Taguchi M, Igarashi T, Fukumoto S, et al. A patient with hypophosphatemic rickets and ossification of posterior longitudinal ligament caused by a novel homozygous mutation in ENPP1 gene. *Bone.* 2011;49(4):913-6.
106. Okawa A, Nakamura I, Goto S, Moriya H, Nakamura Y, Ikegawa S. Mutation in Npps in a mouse model of ossification of the posterior longitudinal ligament of the spine. *Nat Genet.* 1998;19(3):271-3.

-
107. Goldfine ID, Maddux BA, Youngren JF, Reaven G, Accili D, Trischitta V, et al. The role of membrane glycoprotein plasma cell antigen 1/ectonucleotide pyrophosphatase phosphodiesterase I in the pathogenesis of insulin resistance and related abnormalities. *Endocr Rev.* 2008;29(1):62-75.
 108. Econs MJ, McEnery PT. Autosomal dominant hypophosphatemic rickets/osteomalacia: clinical characterization of a novel renal phosphate-wasting disorder. *J Clin Endocrinol Metab.* 1997;82(2):674-81.
 109. Tieder M, Modai D, Samuel R, Arie R, Halabe A, Bab I, et al. Hereditary hypophosphatemic rickets with hypercalciuria. *The New England journal of medicine.* 1985;312(10):611-7.
 110. Lorenz-Depiereux B, Benet-Pages A, Eckstein G, Tenenbaum-Rakover Y, Wagenstaller J, Tiosano D, et al. Hereditary hypophosphatemic rickets with hypercalciuria is caused by mutations in the sodium-phosphate cotransporter gene SLC34A3. *Am J Hum Genet.* 2006;78(2):193-201.
 111. Bergwitz C, Roslin NM, Tieder M, Loredó-Osti JC, Bastepe M, Abu-Zahra H, et al. SLC34A3 mutations in patients with hereditary hypophosphatemic rickets with hypercalciuria predict a key role for the sodium-phosphate cotransporter NaPi-IIc in maintaining phosphate homeostasis. *Am J Hum Genet.* 2006;78(2):179-92.
 112. Tencza AL, Ichikawa S, Dang A, Kenagy D, McCarthy E, Econs MJ, et al. Hypophosphatemic rickets with hypercalciuria due to mutation in SLC34A3/type IIc sodium-phosphate cotransporter: presentation as hypercalciuria and nephrolithiasis. *J Clin Endocrinol Metab.* 2009;94(11):4433-8.
 113. Chi Y, Zhao Z, He X, Sun Y, Jiang Y, Li M, et al. A compound heterozygous mutation in SLC34A3 causes hereditary hypophosphatemic rickets with hypercalciuria in a Chinese patient. *Bone.* 2014;59:114-21.
 114. Beck L, Karaplis AC, Amizuka N, Hewson AS, Ozawa H, Tenenhouse HS. Targeted inactivation of Npt2 in mice leads to severe renal phosphate wasting, hypercalciuria, and skeletal abnormalities. *Proc Natl Acad Sci U S A.* 1998;95(9):5372-7.
 115. Amatschek S, Haller M, Oberbauer R. Renal phosphate handling in human-- what can we learn from hereditary hypophosphataemias? *Eur J Clin Invest.* 2010;40(6):552-60.
 116. Prie D, Huart V, Bakouh N, Planelles G, Dellis O, Gerard B, et al. Nephrolithiasis and osteoporosis associated with hypophosphatemia caused by mutations in the type 2a sodium-phosphate cotransporter. *N Engl J Med.* 2002;347(13):983-91.
 117. Schlingmann KP, Ruminska J, Kaufmann M, Dursun I, Patti M, Kranz B, et al. Autosomal-Recessive Mutations in SLC34A1 Encoding Sodium-Phosphate Cotransporter 2A Cause Idiopathic Infantile Hypercalcemia. *J Am Soc Nephrol.* 2015.
 118. Brownstein CA, Adler F, Nelson-Williams C, Iijima J, Li P, Imura A, et al. A translocation causing increased alpha-klotho level results in hypophosphatemic rickets and hyperparathyroidism. *Proc Natl Acad Sci U S A.* 2008;105(9):3455-60.
 119. Kurosu H, Yamamoto M, Clark JD, Pastor JV, Nandi A, Gurnani P, et al. Suppression of aging in mice by the hormone Klotho. *Science.* 2005;309(5742):1829-33.

-
120. Kuro-o M, Matsumura Y, Aizawa H, Kawaguchi H, Suga T, Utsugi T, et al. Mutation of the mouse *klotho* gene leads to a syndrome resembling ageing. *Nature*. 1997;390(6655):45-51.
 121. Matsumura Y, Aizawa H, Shiraki-Iida T, Nagai R, Kuro-o M, Nabeshima Y. Identification of the human *klotho* gene and its two transcripts encoding membrane and secreted *klotho* protein. *Biochem Biophys Res Commun*. 1998;242(3):626-30.
 122. Hu MC, Shi M, Zhang J, Pastor J, Nakatani T, Lanske B, et al. *Klotho*: a novel phosphaturic substance acting as an autocrine enzyme in the renal proximal tubule. *FASEB J*. 2010;24(9):3438-50.
 123. White KE, Cabral JM, Davis SI, Fishburn T, Evans WE, Ichikawa S, et al. Mutations that cause osteoglophonic dysplasia define novel roles for *FGFR1* in bone elongation. *Am J Hum Genet*. 2005;76(2):361-7.
 124. Farrow EG, Davis SI, Mooney SD, Beighton P, Mascarenhas L, Gutierrez YR, et al. Extended mutational analyses of *FGFR1* in osteoglophonic dysplasia. *Am J Med Genet A*. 2006;140(5):537-9.
 125. Passos-Bueno MR, Wilcox WR, Jabs EW, Sertie AL, Alonso LG, Kitoh H. Clinical spectrum of fibroblast growth factor receptor mutations. *Hum Mutat*. 1999;14(2):115-25.
 126. Gattineni J, Alphonse P, Zhang Q, Mathews N, Bates CM, Baum M. Regulation of renal phosphate transport by *FGF23* is mediated by *FGFR1* and *FGFR4*. *Am J Physiol Renal Physiol*. 2014;306(3):F351-8.
 127. Karim Z, Gerard B, Bakouh N, Alili R, Leroy C, Beck L, et al. *NHERF1* mutations and responsiveness of renal parathyroid hormone. *N Engl J Med*. 2008;359(11):1128-35.
 128. Courbebaisse M, Leroy C, Bakouh N, Salaun C, Beck L, Grandchamp B, et al. A new human *NHERF1* mutation decreases renal phosphate transporter *NPT2a* expression by a PTH-independent mechanism. *PLoS One*. 2012;7(4):e34764.
 129. Reczek D, Berryman M, Bretscher A. Identification of *EBP50*: A PDZ-containing phosphoprotein that associates with members of the ezrin-radixin-moesin family. *J Cell Biol*. 1997;139(1):169-79.
 130. Shenolikar S, Voltz JW, Minkoff CM, Wade JB, Weinman EJ. Targeted disruption of the mouse *NHERF-1* gene promotes internalization of proximal tubule sodium-phosphate cotransporter type IIa and renal phosphate wasting. *Proc Natl Acad Sci U S A*. 2002;99(17):11470-5.
 131. Glorieux FH, Scriver CR, Reade TM, Goldman H, Roseborough A. Use of phosphate and vitamin D to prevent dwarfism and rickets in X-linked hypophosphatemia. *N Engl J Med*. 1972;287(10):481-7.
 132. Goodyer PR, Kronick JB, Jequier S, Reade TM, Scriver CR. Nephrocalcinosis and its relationship to treatment of hereditary rickets. *J Pediatr*. 1987;111(5):700-4.
 133. Reusz GS, Hoyer PF, Lucas M, Krohn HP, Ehrich JH, Brodehl J. X linked hypophosphatemia: treatment, height gain, and nephrocalcinosis. *Arch Dis Child*. 1990;65(10):1125-8.
 134. Carpenter TO, Imel EA, Holm IA, Jan de Beur SM, Insogna KL. A clinician's guide to X-linked hypophosphatemia. *J Bone Miner Res*. 2011;26(7):1381-8.

-
135. Linglart A, Bioso-Duplan M, Briot K, Chaussain C, Esterle L, Guillaume-Czitrom S, et al. Therapeutic management of hypophosphatemic rickets from infancy to adulthood. *Endocr Connect.* 2014;3(1):R13-30.
 136. Imel EA, Zhang X, Ruppe MD, Weber TJ, Klausner MA, Ito T, et al. Prolonged Correction of Serum Phosphorus in Adults With X-Linked Hypophosphatemia Using Monthly Doses of KRN23. *J Clin Endocrinol Metab.* 2015;100(7):2565-73.
 137. Raeder H, Bjerknes R, Shaw N, Netelenbos C. A case of X-linked hypophosphatemic rickets (XLH): complications and the therapeutic use of cinacalcet. *Eur J Endocrinol.* 2008.
 138. Topaz O, Shurman DL, Bergman R, Indelman M, Ratajczak P, Mizrahi M, et al. Mutations in GALNT3, encoding a protein involved in O-linked glycosylation, cause familial tumoral calcinosis. *Nat Genet.* 2004;36(6):579-81.
 139. Frishberg Y, Topaz O, Bergman R, Behar D, Fisher D, Gordon D, et al. Identification of a recurrent mutation in GALNT3 demonstrates that hyperostosis-hyperphosphatemia syndrome and familial tumoral calcinosis are allelic disorders. *J Mol Med (Berl).* 2005;83(1):33-8.
 140. Yancovitch A, Hershkovitz D, Indelman M, Galloway P, Whiteford M, Sprecher E, et al. Novel mutations in GALNT3 causing hyperphosphatemic familial tumoral calcinosis. *J Bone Miner Metab.* 2011;29(5):621-5.
 141. Kato K, Jeanneau C, Tarp MA, Benet-Pages A, Lorenz-Depiereux B, Bennett EP, et al. Polypeptide GalNAc-transferase T3 and familial tumoral calcinosis. Secretion of fibroblast growth factor 23 requires O-glycosylation. *J Biol Chem.* 2006;281(27):18370-7.
 142. Larsson T, Davis SI, Garringer HJ, Mooney SD, Draman MS, Cullen MJ, et al. Fibroblast growth factor-23 mutants causing familial tumoral calcinosis are differentially processed. *Endocrinology.* 2005;146(9):3883-91.
 143. Benet-Pages A, Orlik P, Strom TM, Lorenz-Depiereux B. An FGF23 missense mutation causes familial tumoral calcinosis with hyperphosphatemia. *Hum Mol Genet.* 2005;14(3):385-90.
 144. Ichikawa S, Imel EA, Kreiter ML, Yu X, Mackenzie DS, Sorenson AH, et al. A homozygous missense mutation in human KLOTHO causes severe tumoral calcinosis. *J Clin Invest.* 2007;117(9):2684-91.
 145. Giard JM. Sur la calcification hibernale. *Comptes Rendus des Seances de la Societe de Biologie So.* 1898:3.
 146. McPhaul JJ, Jr., Engel FL. Heterotopic calcification, hyperphosphatemia and angioid streaks of the retina. *Am J Med.* 1961;31:488-92.
 147. Bruns DE, Lieb W, Conway BP, Savory J, Wills MR, Boskey AL. Band keratopathy and calcific lid lesions in tumoral calcinosis. Case reports. *Arch Ophthalmol.* 1988;106(6):725-6.
 148. Campagnoli MF, Pucci A, Garelli E, Carando A, Defilippi C, Lala R, et al. Familial tumoral calcinosis and testicular microlithiasis associated with a new mutation of GALNT3 in a white family. *J Clin Pathol.* 2006;59(4):440-2.
 149. McGuinness FE. Hyperphosphataemic tumoral calcinosis in Bedouin Arabs--clinical and radiological features. *Clin Radiol.* 1995;50(4):259-64.

-
150. Lyles KW, Burkes EJ, Ellis GJ, Lucas KJ, Dolan EA, Drezner MK. Genetic transmission of tumoral calcinosis: autosomal dominant with variable clinical expressivity. *J Clin Endocrinol Metab.* 1985;60(6):1093-6.
151. Witcher SL, Jr., Drinkard DW, Shapiro RD, Schow CE, Jr. Tumoral calcinosis with unusual dental radiographic findings. *Oral Surg Oral Med Oral Pathol.* 1989;68(1):104-7.
152. Zerwekh JE, Sanders LA, Townsend J, Pak CY. Tumoral calcinosis: evidence for concurrent defects in renal tubular phosphorus transport and in 1 alpha,25-dihydroxycholecalciferol synthesis. *Calcif Tissue Int.* 1980;32(1):1-6.
153. Prince MJ, Schaeffer PC, Goldsmith RS, Chausmer AB. Hyperphosphatemic tumoral calcinosis: association with elevation of serum 1,25-dihydroxycholecalciferol concentrations. *Ann Intern Med.* 1982;96(5):586-91.
154. Mitnick PD, Goldfarb S, Slatopolsky E, Lemann J, Jr., Gray RW, Agus ZS. Calcium and phosphate metabolism in tumoral calcinosis. *Ann Intern Med.* 1980;92(4):482-7.
155. Frishberg Y, Ito N, Rinat C, Yamazaki Y, Feinstein S, Urakawa I, et al. Hyperostosis-hyperphosphatemia syndrome: a congenital disorder of O-glycosylation associated with augmented processing of fibroblast growth factor 23. *J Bone Miner Res.* 2007;22(2):235-42.
156. Melhem RE, Najjar SS, Khachaturian AK. Cortical hyperostosis with hyperphosphatemia: a new syndrome? *J Pediatr.* 1970;77(6):986-90.
157. Carmichael KD, Bynum JA, Evans EB. Familial tumoral calcinosis: a forty-year follow-up on one family. *J Bone Joint Surg Am.* 2009;91(3):664-71.
158. Garringer HJ, Fisher C, Larsson TE, Davis SI, Koller DL, Cullen MJ, et al. The role of mutant UDP-N-acetyl-alpha-D-galactosamine-polypeptide N-acetylgalactosaminyltransferase 3 in regulating serum intact fibroblast growth factor 23 and matrix extracellular phosphoglycoprotein in heritable tumoral calcinosis. *The Journal of clinical endocrinology and metabolism.* 2006;91(10):4037-42.
159. Folpe AL, Fanburg-Smith JC, Billings SD, Bisceglia M, Bertoni F, Cho JY, et al. Most osteomalacia-associated mesenchymal tumors are a single histopathologic entity: an analysis of 32 cases and a comprehensive review of the literature. *Am J Surg Pathol.* 2004;28(1):1-30.
160. Fletcher CD. The evolving classification of soft tissue tumours - an update based on the new 2013 WHO classification. *Histopathology.* 2014;64(1):2-11.
161. Mc CR. Osteomalacia with Looser's nodes (Milkman's syndrome) due to a raised resistance to vitamin D acquired about the age of 15 years. *Q J Med.* 1947;16(1):33-46.
162. Prader A, Illig R, Uehlinger E, Stalder G. [Rickets following bone tumor]. *Helv Paediatr Acta.* 1959;14:554-65.
163. Farrow EG, White KE. Tumor-induced osteomalacia. *Expert Rev Endocrinol Metab.* 2009;4(5):435-42.
164. Ledford CK, Zelenski NA, Cardona DM, Brigman BE, Eward WC. The phosphaturic mesenchymal tumor: why is definitive diagnosis and curative surgery often delayed? *Clin Orthop Relat Res.* 2013;471(11):3618-25.
165. Shigematsu T, Kazama JJ, Yamashita T, Fukumoto S, Hosoya T, Gejyo F, et al. Possible involvement of circulating fibroblast growth factor 23 in the development

- of secondary hyperparathyroidism associated with renal insufficiency. *Am J Kidney Dis.* 2004;44(2):250-6.
166. Gutierrez O, Isakova T, Rhee E, Shah A, Holmes J, Collerone G, et al. Fibroblast growth factor-23 mitigates hyperphosphatemia but accentuates calcitriol deficiency in chronic kidney disease. *J Am Soc Nephrol.* 2005;16(7):2205-15.
167. Isakova T, Wahl P, Vargas GS, Gutierrez OM, Scialla J, Xie H, et al. Fibroblast growth factor 23 is elevated before parathyroid hormone and phosphate in chronic kidney disease. *Kidney Int.* 2011;79(12):1370-8.
168. Isakova T, Xie H, Yang W, Xie D, Anderson AH, Scialla J, et al. Fibroblast growth factor 23 and risks of mortality and end-stage renal disease in patients with chronic kidney disease. *JAMA.* 2011;305(23):2432-9.
169. Koh N, Fujimori T, Nishiguchi S, Tamori A, Shiomi S, Nakatani T, et al. Severely reduced production of klotho in human chronic renal failure kidney. *Biochem Biophys Res Commun.* 2001;280(4):1015-20.
170. Hu MC, Kuro-o M, Moe OW. Klotho and chronic kidney disease. *Contrib Nephrol.* 2013;180:47-63.
171. Gutierrez OM, Januzzi JL, Isakova T, Laliberte K, Smith K, Collerone G, et al. Fibroblast growth factor 23 and left ventricular hypertrophy in chronic kidney disease. *Circulation.* 2009;119(19):2545-52.
172. Mirza MA, Larsson A, Melhus H, Lind L, Larsson TE. Serum intact FGF23 associate with left ventricular mass, hypertrophy and geometry in an elderly population. *Atherosclerosis.* 2009;207(2):546-51.
173. Mirza MA, Larsson A, Lind L, Larsson TE. Circulating fibroblast growth factor-23 is associated with vascular dysfunction in the community. *Atherosclerosis.* 2009;205(2):385-90.
174. Mirza MA, Hansen T, Johansson L, Ahlstrom H, Larsson A, Lind L, et al. Relationship between circulating FGF23 and total body atherosclerosis in the community. *Nephrol Dial Transplant.* 2009;24(10):3125-31.
175. Mehta R, Ying GS, Houston S, Isakova T, Nessel L, Ojo A, et al. Phosphate, fibroblast growth factor 23 and retinopathy in chronic kidney disease: the Chronic Renal Insufficiency Cohort Study. *Nephrol Dial Transplant.* 2015;30(9):1534-41.
176. Parker BD, Schurgers LJ, Brandenburg VM, Christenson RH, Vermeer C, Ketteler M, et al. The associations of fibroblast growth factor 23 and uncarboxylated matrix Gla protein with mortality in coronary artery disease: the Heart and Soul Study. *Ann Intern Med.* 2010;152(10):640-8.
177. Lufkin EG, Wilson DM, Smith LH, Bill NJ, DeLuca HF, Dousa TP, et al. Phosphorus excretion in tumoral calcinosis: response to parathyroid hormone and acetazolamide. *J Clin Endocrinol Metab.* 1980;50(4):648-53.
178. Rafaelsen SH, Raeder H, Fagerheim AK, Knappskog P, Carpenter TO, Johansson S, et al. Exome sequencing reveals FAM20c mutations associated with fibroblast growth factor 23-related hypophosphatemia, dental anomalies, and ectopic calcification. *J Bone Miner Res.* 2013;28(6):1378-85.
179. Li Voon Chong SW, Ah Kion S, Cullen MJ. A report of familial hyperphosphataemia in an Irish family. *Ir J Med Sci.* 1999;168(4):262-4.
180. Joseph L, Hing SN, Presneau N, O'Donnell P, Diss T, Idowu BD, et al. Familial tumoral calcinosis and hyperostosis-hyperphosphataemia syndrome are

- different manifestations of the same disease: novel missense mutations in GALNT3. *Skeletal Radiol.* 2010;39(1):63-8.
181. Wang K, Li M, Hakonarson H. ANNOVAR: functional annotation of genetic variants from high-throughput sequencing data. *Nucleic Acids Res.* 2010;38(16):e164.
182. Statistics Norway. Available from: <http://www.ssb.no>.
183. The Biotechnology Act 2003. Act relating to the application of biotechnology in human medicine etc]. Available from: <http://lovdata.no/dokument/NL/lov/2003-12-05-100?q=bioteknologi>.
184. Graham JB, Mc FV, Winters RW. Familial hypophosphatemia with vitamin D-resistant rickets. II: three additional kindreds of the sex-linked dominant type with a genetic analysis of four such families. *Am J Hum Genet.* 1959;11:311-32.
185. Gaucher C, Walrant-Debray O, Nguyen TM, Esterle L, Garabedian M, Jehan F. PHEX analysis in 118 pedigrees reveals new genetic clues in hypophosphatemic rickets. *Hum Genet.* 2009;125(4):401-11.
186. Morey M, Castro-Feijoo L, Barreiro J, Cabanas P, Pombo M, Gil M, et al. Genetic diagnosis of X-linked dominant Hypophosphatemic Rickets in a cohort study: tubular reabsorption of phosphate and 1,25(OH)₂D serum levels are associated with PHEX mutation type. *BMC Med Genet.* 2011;12:116.
187. Abe Y, Nagasaki K, Watanabe T, Abe T, Fukami M. Association between compound heterozygous mutations of SLC34A3 and hypercalciuria. *Horm Res Paediatr.* 2014;82(1):65-71.
188. Dasgupta D, Wee MJ, Reyes M, Li Y, Simm PJ, Sharma A, et al. Mutations in SLC34A3/NPT2c are associated with kidney stones and nephrocalcinosis. *J Am Soc Nephrol.* 2014;25(10):2366-75.
189. Holm IA, Nelson AE, Robinson BG, Mason RS, Marsh DJ, Cowell CT, et al. Mutational analysis and genotype-phenotype correlation of the PHEX gene in X-linked hypophosphatemic rickets. *J Clin Endocrinol Metab.* 2001;86(8):3889-99.
190. Shields ED, Scriver CR, Reade T, Fujiwara TM, Morgan K, Ciampi A, et al. X-linked hypophosphatemia: the mutant gene is expressed in teeth as well as in kidney. *Am J Hum Genet.* 1990;46(3):434-42.
191. Chaussain-Miller C, Sinding C, Wolikow M, Lasfargues JJ, Godeau G, Garabedian M. Dental abnormalities in patients with familial hypophosphatemic vitamin D-resistant rickets: prevention by early treatment with 1-hydroxyvitamin D. *J Pediatr.* 2003;142(3):324-31.
192. Quinlan C, Guegan K, Offiah A, Neill RO, Hiorns MP, Ellard S, et al. Growth in PHEX-associated X-linked hypophosphatemic rickets: the importance of early treatment. *Pediatr Nephrol.* 2012;27(4):581-8.
193. Kaene V. Assessment of growth. In: Kliegman RMea, editor. *Nelson textbook of pediatrics*: Saunders; 2007. p. 70-4.
194. Winters RW, Mc FV, Graham JB. Genetic studies of vitamin D resistant rickets and familial hypophosphatemia. *Helv Paediatr Acta.* 1959;14:533-8.
195. Reid IR, Hardy DC, Murphy WA, Teitelbaum SL, Bergfeld MA, Whyte MP. X-linked hypophosphatemia: a clinical, biochemical, and histopathologic assessment of morbidity in adults. *Medicine (Baltimore).* 1989;68(6):336-52.

-
196. Hardy DC, Murphy WA, Siegel BA, Reid IR, Whyte MP. X-linked hypophosphatemia in adults: prevalence of skeletal radiographic and scintigraphic features. *Radiology*. 1989;171(2):403-14.
 197. Burnett CH, Dent CE, Harper C, Warland BJ. Vitamin D-Resistant Rickets. Analysis of Twenty-Four Pedigrees with Hereditary and Sporadic Cases. *Am J Med*. 1964;36:222-32.
 198. Whyte MP, Schranck FW, Armamento-Villareal R. X-linked hypophosphatemia: a search for gender, race, anticipation, or parent of origin effects on disease expression in children. *J Clin Endocrinol Metab*. 1996;81(11):4075-80.
 199. Carrillo-Lopez N, Roman-Garcia P, Rodriguez-Rebollar A, Fernandez-Martin JL, Naves-Diaz M, Cannata-Andia JB. Indirect regulation of PTH by estrogens may require FGF23. *J Am Soc Nephrol*. 2009;20(9):2009-17.
 200. Cannata-Andia JB, Carrillo-Lopez N, Naves-Diaz M. Estrogens and bone disease in chronic kidney disease: role of FGF23. *Curr Opin Nephrol Hypertens*. 2010;19(4):354-8.
 201. Faroqui S, Levi M, Soleimani M, Amlal H. Estrogen downregulates the proximal tubule type IIa sodium phosphate cotransporter causing phosphate wasting and hypophosphatemia. *Kidney Int*. 2008;73(10):1141-50.
 202. Rowe PS, Oudet CL, Francis F, Sinding C, Pannetier S, Econs MJ, et al. Distribution of mutations in the PEX gene in families with X-linked hypophosphataemic rickets (HYP). *Hum Mol Genet*. 1997;6(4):539-49.
 203. Song HR, Park JW, Cho DY, Yang JH, Yoon HR, Jung SC. PHEX gene mutations and genotype-phenotype analysis of Korean patients with hypophosphatemic rickets. *J Korean Med Sci*. 2007;22(6):981-6.
 204. Cho HY, Lee BH, Kang JH, Ha IS, Cheong HI, Choi Y. A clinical and molecular genetic study of hypophosphatemic rickets in children. *Pediatr Res*. 2005;58(2):329-33.
 205. Econs MJ, Friedman NE, Rowe PS, Speer MC, Francis F, Strom TM, et al. A PHEX gene mutation is responsible for adult-onset vitamin D-resistant hypophosphatemic osteomalacia: evidence that the disorder is not a distinct entity from X-linked hypophosphatemic rickets. *J Clin Endocrinol Metab*. 1998;83(10):3459-62.
 206. Rendina D, Esposito T, Mossetti G, De Filippo G, Gianfrancesco F, Perfetti A, et al. A functional allelic variant of the FGF23 gene is associated with renal phosphate leak in calcium nephrolithiasis. *J Clin Endocrinol Metab*. 2012;97(5):E840-4.
 207. Pekkinen M, Laine CM, Makitie R, Leinonen E, Lamberg-Allardt C, Viljakainen H, et al. FGF23 gene variation and its association with phosphate homeostasis and bone mineral density in Finnish children and adolescents. *Bone*. 2015;71:124-30.
 208. Raeder H, Shaw N, Netelenbos C, Bjerknes R. A case of X-linked hypophosphatemic rickets: complications and the therapeutic use of cinacalcet. *Eur J Endocrinol*. 2008;159 Suppl 1:S101-5.
 209. Verge CF, Lam A, Simpson JM, Cowell CT, Howard NJ, Silink M. Effects of therapy in X-linked hypophosphatemic rickets. *N Engl J Med*. 1991;325(26):1843-8.

-
210. Alon U, Donaldson DL, Hellerstein S, Warady BA, Harris DJ. Metabolic and histologic investigation of the nature of nephrocalcinosis in children with hypophosphatemic rickets and in the Hyp mouse. *J Pediatr.* 1992;120(6):899-905.
 211. Kooh SW, Binet A, Daneman A. Nephrocalcinosis in X-linked hypophosphatemic rickets: its relationship to treatment, kidney function, and growth. *Clin Invest Med.* 1994;17(2):123-30.
 212. Taylor A, Sherman NH, Norman ME. Nephrocalcinosis in X-linked hypophosphatemia: effect of treatment versus disease. *Pediatr Nephrol.* 1995;9(2):173-5.
 213. Patzer L, van't Hoff W, Shah V, Hallson P, Kasidas GP, Samuelli C, et al. Urinary supersaturation of calcium oxalate and phosphate in patients with X-linked hypophosphatemic rickets and in healthy schoolchildren. *J Pediatr.* 1999;135(5):611-7.
 214. Vogt BAA, E.D. Renal failure. In: Kliegman RMea, editor. *Nelson textbook of pediatrics*: Saunders; 2007. p. 2206-14.
 215. Lanske B, Razzaque MS. Molecular interactions of FGF23 and PTH in phosphate regulation. *Kidney Int.* 2014;86(6):1072-4.
 216. Krajisnik T, Bjorklund P, Marsell R, Ljunggren O, Akerstrom G, Jonsson KB, et al. Fibroblast growth factor-23 regulates parathyroid hormone and 1 α -hydroxylase expression in cultured bovine parathyroid cells. *J Endocrinol.* 2007;195(1):125-31.
 217. Makitie O, Kooh SW, Sochett E. Prolonged high-dose phosphate treatment: a risk factor for tertiary hyperparathyroidism in X-linked hypophosphatemic rickets. *Clin Endocrinol (Oxf).* 2003;58(2):163-8.
 218. Sun GE, Suer O, Carpenter TO, Tan CD, Li-Ng M. Heart failure in hypophosphatemic rickets: complications from high-dose phosphate therapy. *Endocr Pract.* 2013;19(1):e8-e11.
 219. Tournis S, Georgoulas T, Zafeiris C, Papalexis C, Petraki K, Lyritis GP. Tertiary hyperparathyroidism in a patient with X-linked hypophosphatemic rickets. *J Musculoskelet Neuronal Interact.* 2011;11(3):266-9.
 220. Neal MD, Deslouches B, Ogilvie J. The use of pre-operative imaging and intraoperative parathyroid hormone level to guide surgical management of tertiary hyperparathyroidism from X-linked hypophosphatemic rickets: a case report. *Cases J.* 2009;2:7572.
 221. McHenry CR, Mostafavi K, Murphy TA. Tertiary hyperparathyroidism attributable to long-term oral phosphate therapy. *Endocr Pract.* 2006;12(3):294-8.
 222. Savio RM, Gosnell JE, Posen S, Reeve TS, Delbridge LW. Parathyroidectomy for tertiary hyperparathyroidism associated with X-linked dominant hypophosphatemic rickets. *Arch Surg.* 2004;139(2):218-22.
 223. Alon US, Monzavi R, Lilien M, Rasoulpour M, Geffner ME, Yadin O. Hypertension in hypophosphatemic rickets--role of secondary hyperparathyroidism. *Pediatr Nephrol.* 2003;18(2):155-8.
 224. Wu CJ, Song YM, Sheu WH. Tertiary hyperparathyroidism in X-linked hypophosphatemic rickets. *Intern Med.* 2000;39(6):468-71.

-
225. Moreno Molina JA, Lopez Sigüero JP, Bueno Fernandez A, Martínez-Aedo Ollero MJ, Martínez Valverde A. [Tertiary hyperparathyroidism during the treatment of familial hypophosphatemic rickets]. *An Esp Pediatr.* 1996;45(2):193-5.
226. Knudtson J, Halse J, Monn E, Nesland A, Nordal KP, Paus P, et al. Autonomous hyperparathyroidism in X-linked hypophosphataemia. *Clin Endocrinol (Oxf).* 1995;42(2):199-203.
227. Alon US, Levy-Olomucki R, Moore WV, Stubbs J, Liu S, Quarles LD. Calcimimetics as an adjuvant treatment for familial hypophosphatemic rickets. *Clin J Am Soc Nephrol.* 2008;3(3):658-64.
228. Grove-Laugesen D, Rejnmark L. Three-year successful cinacalcet treatment of secondary hyperparathyroidism in a patient with x-linked dominant hypophosphatemic rickets: a case report. *Case Rep Endocrinol.* 2014;2014:479641.
229. Yavropoulou MP, Kotsa K, Gotzamani Psarrakou A, Papazisi A, Tranga T, Ventis S, et al. Cinacalcet in hyperparathyroidism secondary to X-linked hypophosphatemic rickets: case report and brief literature review. *Hormones (Athens).* 2010;9(3):274-8.
230. US Food and Drug Administration. Sensipar (cinacalcet hydrochloride): Drug Safety Communication. FDA suspends pediatric clinical trials after report of death.: US Food and Drug Administration; 2013. Available from: <http://www.fda.gov/Drugs/DrugSafety/ucm340551.htm>.
231. Carpenter TO, Olear EA, Zhang JH, Ellis BK, Simpson CA, Cheng D, et al. Effect of paricalcitol on circulating parathyroid hormone in X-linked hypophosphatemia: a randomized, double-blind, placebo-controlled study. *J Clin Endocrinol Metab.* 2014;99(9):3103-11.
232. Zivicnjak M, Schnabel D, Staude H, Even G, Marx M, Beetz R, et al. Three-year growth hormone treatment in short children with X-linked hypophosphatemic rickets: effects on linear growth and body disproportion. *J Clin Endocrinol Metab.* 2011;96(12):E2097-105.
233. Haffner D, Wuhl E, Blum WF, Schaefer F, Mehls O. Disproportionate growth following long-term growth hormone treatment in short children with X-linked hypophosphataemia. *Eur J Pediatr.* 1995;154(8):610-3.
234. Saggese G, Baroncelli GI, Bertelloni S, Perri G. Long-term growth hormone treatment in children with renal hypophosphatemic rickets: effects on growth, mineral metabolism, and bone density. *J Pediatr.* 1995;127(3):395-402.
235. Baroncelli GI, Bertelloni S, Ceccarelli C, Saggese G. Effect of growth hormone treatment on final height, phosphate metabolism, and bone mineral density in children with X-linked hypophosphatemic rickets. *J Pediatr.* 2001;138(2):236-43.
236. Haffner D, Nissel R, Wuhl E, Mehls O. Effects of growth hormone treatment on body proportions and final height among small children with X-linked hypophosphatemic rickets. *Pediatrics.* 2004;113(6):e593-6.
237. Reusz GS, Miltenyi G, Stubnya G, Szabo A, Horvath C, Byrd DJ, et al. X-linked hypophosphatemia: effects of treatment with recombinant human growth hormone. *Pediatr Nephrol.* 1997;11(5):573-7.
238. Simpson MA, Hsu R, Keir LS, Hao J, Sivapalan G, Ernst LM, et al. Mutations in FAM20C are associated with lethal osteosclerotic bone dysplasia (Raine

- syndrome), highlighting a crucial molecule in bone development. *Am J Hum Genet.* 2007;81(5):906-12.
239. Nalbant D, Youn H, Nalbant SI, Sharma S, Cobos E, Beale EG, et al. FAM20: an evolutionarily conserved family of secreted proteins expressed in hematopoietic cells. *BMC Genomics.* 2005;6:11.
240. Hao J, Narayanan K, Muni T, Ramachandran A, George A. Dentin matrix protein 4, a novel secretory calcium-binding protein that modulates odontoblast differentiation. *J Biol Chem.* 2007;282(21):15357-65.
241. Wang X, Hao J, Xie Y, Sun Y, Hernandez B, Yamoah AK, et al. Expression of FAM20C in the osteogenesis and odontogenesis of mouse. *J Histochem Cytochem.* 2010;58(11):957-67.
242. Tagliabracci VS, Engel JL, Wen J, Wiley SE, Worby CA, Kinch LN, et al. Secreted kinase phosphorylates extracellular proteins that regulate biomineralization. *Science.* 2012;336(6085):1150-3.
243. Ishikawa HO, Xu A, Ogura E, Manning G, Irvine KD. The Raine syndrome protein FAM20C is a Golgi kinase that phosphorylates bio-mineralization proteins. *PLoS One.* 2012;7(8):e42988.
244. Lolli G, Cozza G, Mazzorana M, Tibaldi E, Cesaro L, Donella-Deana A, et al. Inhibition of protein kinase CK2 by flavonoids and tyrphostins. A structural insight. *Biochemistry.* 2012;51(31):6097-107.
245. Addison WN, Masica DL, Gray JJ, McKee MD. Phosphorylation-dependent inhibition of mineralization by osteopontin ASARM peptides is regulated by PHEX cleavage. *J Bone Miner Res.* 2010;25(4):695-705.
246. Deshpande AS, Fang PA, Zhang X, Jayaraman T, Sfeir C, Beniash E. Primary structure and phosphorylation of dentin matrix protein 1 (DMP1) and dentin phosphophoryn (DPP) uniquely determine their role in biomineralization. *Biomacromolecules.* 2011;12(8):2933-45.
247. Tagliabracci VS, Engel JL, Wiley SE, Xiao J, Gonzalez DJ, Nidumanda Appaiah H, et al. Dynamic regulation of FGF23 by Fam20C phosphorylation, GalNAc-T3 glycosylation, and furin proteolysis. *Proc Natl Acad Sci U S A.* 2014;111(15):5520-5.
248. Wang X, Wang S, Li C, Gao T, Liu Y, Rangiani A, et al. Inactivation of a novel FGF23 regulator, FAM20C, leads to hypophosphatemic rickets in mice. *PLoS Genet.* 2012;8(5):e1002708.
249. Takeyari S, Yamamoto T, Kinoshita Y, Fukumoto S, Glorieux FH, Michigami T, et al. Hypophosphatemic osteomalacia and bone sclerosis caused by a novel homozygous mutation of the FAM20C gene in an elderly man with a mild variant of Raine syndrome. *Bone.* 2014;67:56-62.
250. Marie PJ, Glorieux FH. Relation between hypomineralized periosteocytic lesions and bone mineralization in vitamin D-resistant rickets. *Calcif Tissue Int.* 1983;35(4-5):443-8.
251. Dumitrescu CE, Kelly MH, Khosravi A, Hart TC, Brahim J, White KE, et al. A case of familial tumoral calcinosis/hyperostosis-hyperphosphatemia syndrome due to a compound heterozygous mutation in GALNT3 demonstrating new phenotypic features. *Osteoporos Int.* 2009;20(7):1273-8.

-
252. Ichikawa S, Baujat G, Seyahi A, Garoufali AG, Imel EA, Padgett LR, et al. Clinical variability of familial tumoral calcinosis caused by novel GALNT3 mutations. *Am J Med Genet A*. 2010;152A(4):896-903.
253. Specktor P, Cooper JG, Indelman M, Sprecher E. Hyperphosphatemic familial tumoral calcinosis caused by a mutation in GALNT3 in a European kindred. *J Hum Genet*. 2006;51(5):487-90.
254. Ichikawa S, Imel EA, Kreiter ML, Yu X, Mackenzie DS, Sorenson AH, et al. A homozygous missense mutation in human KLOTHO causes severe tumoral calcinosis. *J Musculoskelet Neuronal Interact*. 2007;7(4):318-9.
255. Chouery E, Pangrazio A, Frattini A, Villa A, Van Wesenbeeck L, Piters E, et al. A new familial sclerosing bone dysplasia. *J Bone Miner Res*. 2010;25(3):676-80.
256. Steinbach HL, Kolb FO, Crane JT. Unusual roentgen manifestations of osteomalacia. *Am J Roentgenol Radium Ther Nucl Med*. 1959;82:875-86.
257. Folsom LJ, Imel EA. Hyperphosphatemic familial tumoral calcinosis: genetic models of deficient FGF23 action. *Curr Osteoporos Rep*. 2015;13(2):78-87.
258. Carmichael KD, Bynum JA, Evans EB. Familial tumoral calcinosis: a forty-year follow-up on one family. *J Bone Joint Surg Am*. 2009;91(3):664-71.
259. Smith RC, O'Bryan LM, Farrow EG, Summers LJ, Clinkenbeard EL, Roberts JL, et al. Circulating alphaKlotho influences phosphate handling by controlling FGF23 production. *J Clin Invest*. 2012;122(12):4710-5.
260. Imel EA, DiMeglio LA, Hui SL, Carpenter TO, Econs MJ. Treatment of X-linked hypophosphatemia with calcitriol and phosphate increases circulating fibroblast growth factor 23 concentrations. *J Clin Endocrinol Metab*. 2010;95(4):1846-50.
261. Carpenter TO, Imel EA, Ruppe MD, Weber TJ, Klausner MA, Wooddell MM, et al. Randomized trial of the anti-FGF23 antibody KRN23 in X-linked hypophosphatemia. *J Clin Invest*. 2014;124(4):1587-97.
262. Aono Y, Yamazaki Y, Yasutake J, Kawata T, Hasegawa H, Urakawa I, et al. Therapeutic effects of anti-FGF23 antibodies in hypophosphatemic rickets/osteomalacia. *J Bone Miner Res*. 2009;24(11):1879-88.

9. Appendix

Table 4 Age- and sex-dependent reference intervals.

Analyte	Age	Female	Male	Unit
S-P	At birth	0.9 – 2.2		mmol/L
	0 – 12 months	1.4 – 2.3		
	1 – 17 years	1.2 – 1.8		
	18 – 49 years	0.85 – 1.5	0.75 – 1.65	
	> 50 years	0.85 – 1.5	0.75 – 1.35	
S-ALP	0-14 days	90 – 273		U/L
	15 days < 1 year	134 – 518		
	1-5 years	156 – 369		
	5-6	149 – 363	127 – 370	
	7-8	157 – 365	149 – 345	
	9-10	166 – 423	159 – 365	
	11-13	119 – 402	150 – 492	
	14-16	49 – 291	100 – 402	
	17-19	39 – 106	55 – 242	
	Adult	35 – 105		
S-PTH	2 – 4 years	0.4 - 3.4		pmol/L
	4 – 8 years	0.1 – 2.7		
	8 – 12 years	0.2 – 3.4		
	12 – 16 years	0.1 – 3.9		
	Adult	1.3 – 6.9		

Table 5 Phenotype-, treatment- and complication characteristics of XLHR patients¹

	Time of diagnosis							Treatment details					Last registered consultation						
	Family number	Sex	Age	Height z-score	Skeletal involvement	S-phosphate mmol/L	S-ALP U/L	S-iPTH pmol/L	Tmp/GFR mmol/L	Age at start of treatment	Elemental phosphorus start dose (mg/kg/d)	Elemental phosphorus mean dose (mg/kg/d)	Alfacalcidol start dose (ng/kg/d)	Alfacalcidol mean dose (ng/kg/d)	Age	Height z-score	Dental involvement	Hyperparathyroidism	Nephrocalcinosis
3	F	6y4m	-1.98	+	0.74	362	5.3	0.64	6y8m	15.8	28.3	15.4	25.9	7y2m	-2.4	+	+/+	-	+
3	F	2y0m	-1.39	+	0.86	375	7.4	0.71	NA	0	0	0	0	2y0m	-1.39	+	+/+	-	+
5	F	0y2m	-0.07	-	1.16	791	NA	NA	0y3m	103.3	60.6	16.7	44.2	16y3m	-1.39	-	+/+	+	-
5	F	0y1m	-0.92	-	1.53	1099	NA	NA	0y2m	31.6	56.9	25.3	48.2	13y9m	-0.5	-	+/+	+	-
5	F	0y3m	-0.74	-	1.2	796	NA	NA	0y11m	40.8	62.4	32.6	39.1	7y5m	-1	-	+/+	+	+
6	M	0y8m	0.51	-	0.8	687	NA	0.83	0y10m	10.8	64	16.3	48	6y11m	-2.59	+	+/+	-	+
6	F	4y5m	0.52	+	0.76	533	7.3	0.77	4y5m	10	60	40	30	12y1m	-0.53	+	+/+	+	+
6	F	2y3m	-0.1	+	0.9	583	14	NA	2y7m	29.1	28.6	17.4	17.2	3y2m	-0.07	-	+/+	-	-
7	F	2y1m	-2.54	+	0.7	411	7.9	NA	2y1m	21.7	66.6	17	23.9	11y4m	-1.26	+	+/+	-	-
8	F	0y11m	-2.75	+	0.63	339	5.7	NA	0y11m	10	29.9	13.3	24.6	1y4m	-2.34	-	+/+	-	-
8	M	0y11m	-1.68	+	0.72	598	14.6	0.73	1y0m	38.4	60.8	23.3	49.4	11y4m	-2.22	-	+/+	+	+
9	M	0y6m	-2.97	+	0.8	349	8.2	NA	0y6m	15.1	31.7	14.7	53.8	14y11m	-0.97	+	+/+	+	+OT
10	F	2y6m	NA	NA	0.77	NA	NA	NA	NA	NA	NA	NA	NA	17y4m	NA	+	NA	NA	NA
11	M	3y1m	-3.27	+	0.9	351	7.1	0.9	3y7m	53.4	39	28.8	36.6	16y1m	-2	+	+/+	-	-
12	F	0y5m	0.58	-	1.43	731	9.5	1.17	0y7m	23.8	11.1	14.3	37.9	10y9m	-1.48	-	+/+	-	-
12	F	0y4m	-0.87	-	1.14	628	5.6	0.92	0y5m	19	13.4	17.1	33.7	5y9m	-1.78	-	+/+	+	+
15	F	0y8m	-1.96	+	0.77	440	5.3	NA	1y2m	27	34.6	29.1	31.5	8y5m	-2.29	-	+/+	+	+
17	F	0y5m	0.99	-	1.36	782	NA	NA	0y5m	69.3	74.1	29.9	17.2	18y0m	0.79	-	NA/T	+	-
24	F	6y6m	-6.51	+	0.9	1460	9.1	NA	6y7m	26	NA	27	NA	7y4m	-6.31	+	+/+	-	+
24	M	15y6m	-5.11	+	0.92	734	6.4	NA	15y7m	66	NA	20	NA	16y4m	-5.1	+	+/+	-	+OT
27	F	3y4m	0.34	+	0.8	366	3.1	0.76	3y4m	15	30	18	18	3y7m	0.34	-	+/+	-	+

¹Abbreviations: F = female; M = male; NA = not available. For skeletal involvement, dental involvement, nephrocalcinosis and persistent bowing: "-" = "no" and "+/" = "yes". OT = osteotomy. For hyperparathyroidism: "-/+" = "no before start of treatment/yes during treatment"; "+/+/" = "yes before start of treatment/yes during treatment". T = tertiary hyperparathyroidism.

Table 6 Phenotype-, treatment- and complication characteristics of non-XLHR patients with hereditary hypophosphatemia¹

Gene	Time of diagnosis							Treatment details					Last registered consultation							
	Family number	Sex	Age	Height z-score	Skeletal involvement	S-phosphate mmol/L	S-ALP U/L	S-iPTH pmol/L	Tmp/GFR mmol/L	Age at start of treatment	Elemental phosphorus start dose (mg/kg/d)	Elemental phosphorus mean dose (mg/kg/d)	Alfacalcidol start dose (ng/kg/d)	Alfacalcidol mean dose (ng/kg/d)	Age	Height z-score	Dental involvement	Hyperparathyroidism	Nephrocalcinosis	Persistent bowing
<i>FAM20C</i>	1	M	3 y 8 m	-0.8	-	1.02	216	2.5	NA	3 y 8 m	NA	NA	NA	NA	16 y 3 m	-1.38	+	+/-	-	-
	1	M	5 y 11 m	0.64	-	1.26	379	NA	NA	5 y 11 m	NA	NA	NA	NA	18 y 0 m	0.56	+	+/-	-	-
<i>SLC34A3</i>	28	M	12 y 0 m	0.17	-	1.17	243	0.3	1.42	NO					12 y 0 m	0.17	-	-	+	-
Unknown	2	M	3 y 4 m	-3.05	+	0.65	915	8.6	0.45	3 y 4 m	10.6	51.6	24.2	38	17 y 11 m	-2.43	+	+/+	-	+
	13	F	1 y 10 m	NA	+	0.8	504	NA	NA	1 y 10 m	NA	43.1	NA	61.2	18 y 0 m	-1.55	+	NA/T	+	+
	14	F	5 y 10 m	0.46	+	0.54	489	2.3	NA	5 y 11 m	NA	NA	NA	NA	17 y 8 m	0.04	-	+/-	-	NA
	16	M	2 y 0 m	-1.89	+	1.14	466	13.6	NA	5 y 10 m	20	11.8	20	17.6	16 y 4 m	-3.79	-	+/+	-	+/OT

¹Abbreviations: F = female; M = male; NA = not available. For skeletal involvement, dental involvement, nephrocalcinosis and persistent bowing: "-" = "no" and "+/+" = "yes". OT = osteotomy. For hyperparathyroidism: "-/+/" = "no before start of treatment/yes during treatment"; "+/+/" = "yes before start of treatment/yes during treatment". T = tertiary hyperparathyroidism.

Table 7 Hereditary monogenic conditions involving dysregulation of FGF23 and phosphate reabsorption, and abnormal tissue mineralization.

Gene	Protein	Human disease	OMIM#	S-P	TmP/GFR	fFGF23	cFGF23	Abnormal mineralization
<i>FGF23</i>	Fibroblast growth factor 23	ADHR	193100	↓	↓	↔	↔	Rickets, osteomalacia, enthesopathies
		HFTC/HHS	211900	↔	↔	↓	↔	Ectopic calcification, focal hyperostosis
<i>PHEX</i>	Phosphate-regulating endopeptidase homolog, X-linked	XLHR	307800	↓	↓	↔	↔	Rickets, osteomalacia, enthesopathies
		ARHR1	241520	↓	↓	↔	↔	Rickets, osteomalacia, osteosclerosis of skull
<i>ENPP1</i>	Ectonucleotide pyrophosphatase phosphodiesterase 1	ARHR2	613312	↓	↓	↔	↔	Rickets, osteomalacia, ectopic calcifications
<i>FAM20C</i>	Family with sequence similarity 20, member c	ARHR3		↓	↓	↔	↔	Generalized osteosclerosis; Animal model: rickets
		Raine syndrome	259775					
<i>KL</i>	α-klotho	Klotho-HR		↓	↓	↔	↔	Rickets, osteomalacia
		HFTC/HHS	211900	↔	↔	↓	↔	Ectopic calcification, focal hyperostosis
<i>FGFR1</i>	Fibroblast growth factor receptor 1	OGD	166250	↓	↓			Achondroplasia-like; fibrous dysplasia
<i>GALNT3</i>	GalNAc transferase 3	HFTC/HHS	211900	↔	↔	↓	↔	Ectopic calcification, focal hyperostosis

10. Papers I – III

Paper I

I

Hereditary hypophosphatemia in Norway: a retrospective population-based study of genotypes, phenotypes, and treatment complications

Silje Rafaelsen¹, Stefan Johansson^{1,2}, Helge Ræder^{1,3} and Robert Bjerknes^{1,3}

¹Section for Pediatrics, Department of Clinical Science, Haukeland University Hospital, University of Bergen, N-5021 Bergen, Norway, ²Center for Medical Genetics and Molecular Medicine and ³Department of Pediatrics, Haukeland University Hospital, Bergen, Norway

Correspondence
should be addressed
to S Rafaelsen
Email
Silje.Rafaelsen@uib.no

Abstract

Objective: Hereditary hypophosphatemias (HH) are rare monogenic conditions characterized by decreased renal tubular phosphate reabsorption. The aim of this study was to explore the prevalence, genotypes, phenotypic spectrum, treatment response, and complications of treatment in the Norwegian population of children with HH.

Design: Retrospective national cohort study.

Methods: Sanger sequencing and multiplex ligand-dependent probe amplification analysis of *PHEX* and Sanger sequencing of *FGF23*, *DMP1*, *ENPP1KL*, and *FAM20C* were performed to assess genotype in patients with HH with or without rickets in all pediatric hospital departments across Norway. Patients with hypercalcuria were screened for *SLC34A3* mutations. In one family, exome sequencing was performed. Information from the patients' medical records was collected for the evaluation of phenotype.

Results: Twenty-eight patients with HH (18 females and ten males) from 19 different families were identified. X-linked dominant hypophosphatemic rickets (XLHR) was confirmed in 21 children from 13 families. The total number of inhabitants in Norway aged 18 or below by 1st January 2010 was 1 109 156, giving an XLHR prevalence of ~1 in 60 000 Norwegian children. *FAM20C* mutations were found in two brothers and *SLC34A3* mutations in one patient. In XLHR, growth was compromised in spite of treatment with oral phosphate and active vitamin D compounds, with males tending to be more affected than females. Nephrocalcinosis tended to be slightly more common in patients starting treatment before 1 year of age, and was associated with higher average treatment doses of phosphate. However, none of these differences reached statistical significance.

Conclusions: We present the first national cohort of HH in children. The prevalence of XLHR seems to be lower in Norwegian children than reported earlier.

European Journal of
Endocrinology
(2016) 174, 125–136

Introduction

Hereditary hypophosphatemia (HH) is a group of rare diseases with disordered phosphate metabolism and decreased renal tubular phosphate reabsorption (1). In hypophosphatemic rickets (HR), the hypophosphatemia is associated with rickets and osteomalacia, whereas syndromes with hypophosphatemia combined with

osteosclerosis and ectopic calcifications, and not rickets or osteomalacia, are also recognized (1).

HR can be classified as either dependent or independent of the bone derived fibroblast growth factor 23 (FGF23) (1). FGF23 is a phosphate-regulating hormone (2), acting on kidney tubuli cells to decrease expression of

sodium-phosphate co-transporter types IIa and IIc (NaPi-IIa and NaPi-IIc) encoded by *SLC34A1* and *SLC34A3* respectively. Elevated levels of serum phosphate increase the expression of FGF23 thereby decreasing the reabsorption of phosphate in the renal proximal tubule, while hypophosphatemia normally down regulates the expression of FGF23. FGF23 also down regulates the 1- α -hydroxylase (encoded by *CYP27b1*), thus inhibiting the activation of 25OH vitamin D (25OHD) to 1,25(OH)₂ vitamin D (1,25(OH)₂D), and up regulates 24-hydroxylase (encoded by *CYP24a1*), which inactivates 1,25(OH)₂D by conversion to 24,25(OH)₂ vitamin D (3). In FGF23-dependent HR, the physiological increase in serum 1,25(OH)₂D in response to hypophosphatemia is blunted, and the result is a serum level of 1,25(OH)₂D that is low, or inappropriately normal for the degree of hypophosphatemia (4).

FGF23 dependent HR is caused by mutations in genes involved in the FGF23 bone–kidney-axis, with levels of intact FGF23 (iFGF23) being elevated or inappropriately normal in the setting of hypophosphatemia when suppressed FGF23 is to be expected (1). FGF23 dependent HR includes X-linked dominant HR (XLHR) caused by loss-of-function mutations in the phosphate regulating endopeptidase homolog, X-linked (*PHEX*) gene (5), autosomal dominant HR caused by gain of function mutations in the *FGF23* gene (6), and three types of autosomal recessive HR. ARHR1 is caused by mutations in the *DMPI* gene, encoding the dentin matrix protein 1 (7, 8), ARHR2 is caused by mutations in the *ENPP1* gene encoding the ectonucleotide pyrophosphatase/phosphodiesterase 1 (9, 10), whereas we have recently shown an association between biallelic mutations in *FAM20C* and FGF23-dependent ARHR3 in a Norwegian family (11). *FAM20C* encodes a protein kinase, important in many phosphorylation processes. Phosphorylation of FGF23 by *FAM20C* makes FGF23 less stable by inhibiting O-glycosylation by GalNacT3 (12), and inactivating mutations in *FAM20C* thus leads to increased levels of iFGF23 (11, 13). There is also one report of FGF23 dependent HR caused by an activating translocation leading to up-regulation of the expression of the *KL* gene, encoding the anti-aging protein α -klotho (14). In FGF23-independent HR, as seen in hereditary HR with hypercalcuria (HHRH) caused by mutations in the *SLC34A3* gene (15, 16), the level of iFGF23 is appropriately down-regulated (16).

Treatment of HR includes oral phosphate replacement several times daily, combined with calcitriol to counteract the secondary hyperparathyroidism (HPT) elicited by the serum phosphate peak (17) and transient decrease

in serum ionized calcium upon phosphate dosing. Treatment is balanced to improve linear growth and reduce skeletal deformities while simultaneously minimizing the risk of complications to treatment such as secondary and tertiary HPT, nephrocalcinosis, hypertension, and renal failure (18).

We have conducted the first complete national study of HH in children, to explore the prevalence, genotypes, phenotypic spectrum, and response to and complications of treatment.

Subjects and methods

Patient population

During 2009 all pediatric hospital departments in Norway were contacted to identify children with HH. The number of patients identified was compared to the number of patients younger than 18 years registered in the Norwegian Patient Registry (NPR) with the diagnosis code 'E83.3 Disorders of phosphorus metabolism and phosphatases' in the World Health Organization's International Classification of Diseases version 10 (WHO ICD-10). Patients were continuously recruited through the years 2009–2014.

The inclusion criteria for HH were serum phosphate below the age dependent reference range in repeated samples combined with tubular maximum reabsorption rate of phosphate per glomerular filtration rate (TmP/GFR) not due to primary HPT, HPT secondary to renal failure or malabsorption, Fanconi syndrome or other tubulopathy, vitamin D dependent rickets, vitamin D deficiency or hypophosphatemia secondary to acute metabolic derangements. A family history or genetic diagnosis was supportive, but not required for inclusion.

Genetic analysis

Genomic DNA was purified from blood using the QiaSymphony System (Qiagen). If the mutation status was not already known, all exons and intron–exon boundaries of *PHEX* were sequenced in the index case of each family. If a disease causing mutation was not found, and the inheritance pattern suggested a sporadic case or X-linked dominant disease, multiplex ligand-dependent probe amplification (MLPA) analysis of *PHEX* were performed at the Molecular Genetics Laboratory, Royal Devon and Exeter Foundation NHS Trust, Exeter, Devon, UK. The *PHEX* MLPA analysis can identify mid-size deletions and insertions not detected by regular Sanger sequencing or chromosomal analysis.

All exons and intron–exon boundaries of *FGF23*, *DMP1*, *ENPP1*, *KL*, and *FAM20C* were sequenced, in successive order, in subjects without pathogenic *PHEX* mutations.

In short, DNA targets were first amplified by PCR (list of primers available upon request) using the AmpliTaq Gold DNA Polymerase System (Applied Biosystems). PCR amplicons were purified with 2 μ l of ExoSapIT. Using the Big Dye Terminator chemistry sequencing was performed on the 3730 DNA analyzer (Applied Biosystems) and analyzed using the SeqScape Software (Applied Biosystems).

All mutations detected were compared to variants previously reported in the SNP database (<http://www.ncbi.nlm.nih.gov/projects/SNP/index.html>) and in the PHEX database (http://www.pahdb.mcgill.ca/cgi-bin/phexdb/phexdb_mutQ1.cgi?field=ID_mut&value=).

Review of medical history

Information on age at diagnosis, clinical and biochemical findings at diagnosis, treatment, and complications was collected by review of the medical records of included patients. Height was converted to z-scores according to Norwegian growth charts (19). Delta z-score was calculated as the difference between z-score at last registered consultation and z-score at diagnosis. Laboratory data from each visit from the time of diagnosis to the time of inclusion in the study, including serum levels of calcium, phosphate, alkaline phosphatase, creatinine, parathyroid hormone (PTH), 25OHD, and 1,25(OH)₂D were also recorded, as well as results from kidney ultrasound and skeletal X-ray examinations. Tmp/GFR was calculated according to the formula provided by Barth *et al.* (20). Blood tests were analyzed according to each hospital laboratory's current standard methods.

Genotype–phenotype associations in XLHR patients

The *PHEX* mutations were classified as either deleterious or plausible according to earlier studies (21). Deleterious mutations comprise those leading to a premature stop codon, including nonsense mutations, splice-site mutations, and insertions and deletions affecting reading frame. Mutations classified as plausible were missense mutations and deletions that did not affect reading frame. The phenotypic features compared were age at diagnosis and at the last registered consultation, height z-score at diagnosis and at the last registered consultation, serum levels of phosphate, ALP and PTH at diagnosis, skeletal manifestations (clinical or radiological signs of rickets or

bowing) at diagnosis, and information on dental involvement, nephrocalcinosis, and persistent bowing at the last registered consultation.

Statistical analysis

The prevalences of HH and XLHR was calculated based on the number of patients aged 0–18 years registered with these diagnosis in 2009 and the total number of people in Norway aged 0–18 years by 1st January 2010, obtained from the official Statistics Norway database (22).

The data were analyzed with SPSS version 22. Between-group comparisons were performed using non-parametric tests; medians were compared using the Mann–Whitney *U* test, and frequencies were compared with the Fisher's exact test.

Ethics and approvals

Written informed consent was obtained from all study participants. The study was approved by the Regional Committee for Medical and Health Research Ethics, Region West, Norway (REK number 2009/1140).

Clinical Trial Registration (ClinicalTrials.gov) number: NCT01057186.

Results

HH patient cohort

By 31st December 2009 we had identified a total of 23 children aged 0–18 years with HH in Norway, and all except one were included in this study. Two additional patients with HH, one with confirmed XLHR, were born before 2009, but diagnosed after 2010. By the end of 2009 the National Patient Registry reported 32 children with the ICD-10 diagnosis 'E83.3 Disorders of phosphate metabolism and phosphatases', but four of these patients had hypophosphatasia, and five had transient hypophosphatemia in the course of malignancy, premature birth, or other underlying condition. On 1st January 2010, the number of inhabitants aged below 18 years was 1 109 156, and this gives a prevalence of HH of ~ 1 in 45 000 children. XLHR was confirmed in 18 children, giving a prevalence of ~ 1 in 60 000. During the period from 1st January 2010 to 31st December 2014, we included another four patients, two of which immigrated to Norway in 2014 and two patients born to XLHR mothers after 2010.

The total of 28 patients included comprised 18 females and ten males from 19 different families

(Supplementary Figure 1, see section on supplementary data given at the end of this article). XLHR was confirmed in 21 children. Twenty-two patients had a family history of HR, while six were sporadic cases.

Genotypes in HH

We identified the likely pathogenic mutation in 15 of the 19 HH pedigrees (79%). *PHEX* mutations were found in 21 subjects from 13 different pedigrees (Supplementary Table 1, see section on supplementary data given at the end of this article), and three of the XLHR probands were sporadic. Of the 13 different *PHEX* mutations detected, nine had not been previously reported in the SNP or *PHEX* databases (see section 'Materials and methods'). The nine novel mutations comprised one large duplication, two single nucleotide deletions leading to frameshift and premature stop codons, two triplet deletions leading to loss of one or more codons, two missense mutations, one nonsense mutation, and one splice site mutation. One male patient with HHRH was found to be compound heterozygous for a splicing mutation, c.757-1G>A, and an intronic deletion mutation, c.925+20_926-48del, in the *SLC34A3* gene. The c.757-1G>A affects the conserved splice donor site of intron 7, and is predicted to cause aberrant splicing. The c.925+20_926-48del mutation has been reported previously (15). Two patients with combined heterozygous mutations in *FAM20C* are described elsewhere (11). In four patients, two sporadic cases in

females and two males with affected mothers, we were not able to identify a pathogenic mutation by standard Sanger sequencing of *PHEX*, *FGF23*, *DMP1*, *ENPP1* or *KL*, or by *PHEX* MLPA.

Phenotypes in HH

The median age at diagnosis was 2.1 years (range 0.1–15.5 years), and 26 of the 28 subjects were diagnosed before the age of 7 years (Table 1 and detailed information for each subject is given in Supplementary Table 2, see section on supplementary data given at the end of this article). Median age at the last registered consultation was 12.1 years (range 1.3–18.3).

Phenotype in XLHR ▶ The 21 XLHR children comprised 16 females and five males. Their median age was 0.9 years (range 0.1–15.5) at diagnosis, and 10.8 years (range 1.3–18.0) at the last registered consultation. Growth was compromised, and Fig. 1 illustrates the height z-scores for 19 of the 21 XLHR patients related to age at diagnosis and at the last registered consultation. Males tended to have a lower height z-score than females (Table 2), both at diagnosis and at the last registered consultation, whereas delta z-score did not differ between the sexes. In accordance with an earlier study (23), we analyzed the XLHR patients' data depending on initiation of treatment before or after 1 year of age. There was no significant improvement in height z-score in either treatment group.

Table 1 Characteristics of the cohort of patients with hereditary hypophosphatemia^a.

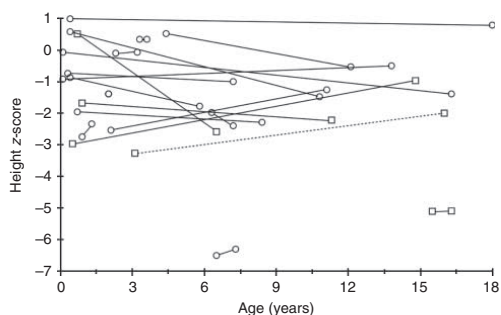
	All patients (n=28)	XLHR (n=21)
Time of diagnosis		
Sex (male/female) (n/n)	10/18	5/16
Family history of HH (n/N)	22/28	18/21
Age at diagnosis (years)	2.1 (0.1 to 15.5)	0.9 (0.1 to 15.5)
Height (z-score)	-0.9 (-6.5 to 1.0)	-1.2 (-6.5 to 1.0)
Skeletal disease ^b (n/N)	17/28	13/21
Treatment		
Age at treatment start (years)	2.1 (0.2 to 15.6)	1 (0.2 to 6.7)
Elemental phosphorus (mg/kg per day)	39 (28 to 61)	39 (0 to 74)
Alfacalcidol (ng/kg per day)	33 (21 to 42)	34 (0 to 54)
Last registered consultation		
Age (years)	12.1 (1.3 to 18.3)	10.8 (1.3 to 18.0)
Height (z-score)	-1.4 (-6.31 to 0.8)	-1.4 (-6.3 to 0.8)
Delta z-score height (z-score)	-0.1 (-3.1 to 2.0)	-0.1 (-3.1 to 2.0)
Dental involvement (n/N)	13/28	9/21
Nephrocalcinosis (n/N)	11/28	9/20 ^c
Persistent bowing (n/N)	16/28	13/21

n/N, number of patients with this characteristic/total number of patients.

^aContinual variables are given as median (range).

^bSkeletal disease: clinical or radiological signs of rickets, or skeletal axis deviation.

^cInformation missing for one patient.

**Figure 1**

Growth in X-linked hypophosphatemic rickets. Ages at diagnosis and last registered consultation, and the corresponding height z-scores for 19 of the 21 XLHR patients. The two outliers represent two immigrant siblings who had not received any medical care and did not start treatment until age 6 and 15 years respectively. The broken line represents the male treated with growth hormone. Circles represent females and squares represent males.

One patient was treated with growth hormone (GH) from the age of 11 years 10 months. His height z-score improved from -2.9 at the last consultation before initiation of GH to a final height of -1.9 s.d. at age 17 years (data not shown).

Clinical or radiological evidence of skeletal involvement was found in 13 of 20 children (four out of five males

and nine out of 15 females) at diagnosis. The seven patients without skeletal manifestations at diagnosis were all familial cases, diagnosed before the age of 8 months (median 4 months), and comprised six females and one male. During the years after diagnosis, all of these had episodes of rickets identified on clinical or radiological examination, and a male and two of the females had persisting skeletal axis deviations at the last registered consultation. Overall, nine females and four males had persisting axis deviation at the last registered consultation, and correcting osteotomy had been performed in one female and two males. The prevalence of dental involvement was higher in male than female XLHR patients, and in children who started treatment after the age of 1 year (Table 2).

Genotype–phenotype associations in XLHR ▶ There were no differences between the mutation status groups in growth, dental involvement, persistent bowing, or development of nephrocalcinosis (results not shown).

Treatment and complications in HH

The median age at the start of treatment was 2.1 years. Twenty-six of the 28 patients were treated with oral phosphate and vitamin D (alfacalcidol) supplements (Table 1). Two patients were diagnosed at the time of inclusion, and had not started any treatment at that point.

Treatment and complications in XLHR ▶ Details of medical treatment were available for 19 of the 21 XLHR

Table 2 Effect of gender and early start of treatment in X-linked hypophosphatemic rickets^a.

	Stratified by gender		Age at treatment start	
	Male (n=5)	Female (n=16)	<1 year (n=10)	>1 year (n=9)
Time of diagnosis				
Age (years)	0.9 (0.5 to 15.5)	1.5 (0.1 to 6.5)	0.4 (0.1 to 0.9)	3.3 (0.7 to 15.5)
Height (z-score)	-3 (-5.1 to 0.5)	-0.9 (-6.5 to 1.0)	-0.8 (-3.0 to 1.0)	-2 (-6.5 to 0.5)
Skeletal disease ^b (n/N)	4/5	9/15	3/10	9/9
Treatment data				
Age at treatment start (years)	1 (0.5 to 3.6)	1.1 (0.2 to 6.7)	0.6 (0.2 to 1.0)	3.6 (1.2 to 15.6)
Elemental phosphorus (mg/kg per day)	50 (32 to 64)	32 (0 to 74)	59 (11 to 74)	35 (28 to 67)
Alfacalcidol (ng/kg per day)	49 (37 to 54)	28 (0 to 48)	42 (17 to 54)	26 (17 to 37)
Last registered consultation				
Age (years)	14.8 (6.5 to 16.3)	7.9 (1.3 to 18.0)	11.1 (1.3 to 18.0)	8.4 (3.2 to 16.3)
Height (z-score)	-2.2 (-5.1 to -1.0)	-1.4 (-6.3 to 0.8)	-1.4 (-2.6 to 0.8)	-2 (-6.3 to 0.3)
Delta z-score (z-score)	0 (-2.1 to 1.3)	-0.2 (-3.1 to 2.0)	-0.4 (-3.1 to 2.0)	0 (-1.1 to 1.3)
Dental involvement (n/N)	4/5	5/15	2/10	7/9
Nephrocalcinosis (n/N)	2/5	7/15	7/10	2/9
Persistent bowing (n/N)	4/5	9/15	5/10	7/9

n/N, number of patients with this symptom/total number of patients.

^aContinual variables are given as median (range).

^bSkeletal disease: clinical or radiological signs of rickets, or skeletal axis deviation.

patients. In this group, the median age at the start of treatment with oral phosphate and alfacalcidol was 1.0 year (range 0.2–15.6), and ten of 19 children started treatment before the age of 1 year.

Information concerning development of nephrocalcinosis was available for 20 of 21 XLHR patients, and nephrocalcinosis was diagnosed in nine of 20 (45%), at a median age 4 years 6 months (range 1 year–5 years 5 months), after a median time in treatment of 1 year 5 months (range 8 months–4 years 5 months). The median time in treatment for patients without registered nephrocalcinosis was 7 years 2 months (range 0–14 years 7 months).

All nine XLHR patients who developed nephrocalcinosis did so within 5 years of treatment. Of the 11 patients without nephrocalcinosis, only four had been treated for 5 years or more, and were included in further comparisons. The prevalence of nephrocalcinosis in this subgroup was nine of 13 (69%). There was a trend toward a higher average daily dose of phosphate (given as mg/kg per day elemental phosphorus) during the years before the diagnosis of nephrocalcinosis as compared to the daily phosphate dose during the first 5 treatment years in patients without nephrocalcinosis (Fig. 2A) (median 61.0 mg/kg per day (range 12.1–79.0) and median 44.8 mg/kg per day (range 13.8–64.7) respectively). Moreover, there was a tendency for earlier start of treatment in children who developed nephrocalcinosis compared with children that did not (median 0.5 year vs 1 year; range 0.2–4.4 vs 0.6–3.6), and seven of nine children with nephrocalcinosis and two of four children without

nephrocalcinosis had started treatment before 1 year of age. There were no differences in the starting doses of phosphate and alfacalcidol, average daily dose of alfacalcidol, serum level of PTH level at diagnosis, maximum registered serum PTH, or maximum registered urine-calcium/creatinine ratio (U-Ca/creatinine; results not shown). Furthermore, the groups did not differ with respect to the occurrence of skeletal symptoms at diagnosis, dental involvement at diagnosis, persistent bowing at the last registered consultation, or delta height z-score (not shown).

Information concerning parathyroid state was available in 18 patients, of whom 16 had elevated levels of total intact PTH at the time of diagnosis (Table 1 and Supplementary Table 2a). All patients developed transient HPT during treatment in the face of normocalcemia. As seen in Fig. 2B, there was a positive association between the maximum measured serum PTH and the daily dose of phosphate (given as mg/kg per day of elemental phosphorus). Tertiary HPT was diagnosed in one female XLHR patient at 13 years of age. She had been treated with phosphate and alfacalcidol from the age of 5 months, and during the 12.5 years of treatment, the average phosphate dose was 83.0 mg/kg per day (range 47.0–127.0 mg/kg per day) and alfacalcidol dose 18.5 ng/kg per day (range 11.4–44.0 ng/kg per day). Treatment with calcimimetics was started, and she has avoided the need of parathyroidectomy (24).

Treatment and complications in non-X-linked HH ► Nephrocalcinosis was diagnosed in one female patient with no detected mutation in any of the known genes at age 8 years 2 months after 6 years 4 months of treatment with phosphate and alfacalcidol. Nephrocalcinosis was also demonstrated in the male patient with HHRH, before start of treatment. Tertiary HPT was found in one female patient with no established mutations in any of the known genes. She had been treated for 14 years, with an average dose of elemental phosphorus of 45.9 mg/kg per day (range 38–80 mg/kg per day) and alfacalcidol 34.2 ng/kg per day (range 22–49.6 ng/kg per day) the last 7 years before the development of permanently elevated PTH combined with hypercalcemia. The patient has responded well to treatment with a calcimimetic, and has so far not needed parathyroidectomy.

Discussion

We have presented the first national cohort of HH and XLHR in children, describing the prevalence, genotypes,

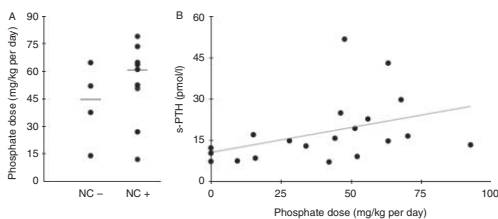


Figure 2

Complications in X-linked hypophosphatemic rickets.

(A) Nephrocalcinosis: the average daily phosphate (given as mg/kg per day elemental phosphorus) dose in patients who developed nephrocalcinosis (NC+) and patients who did not (NC-). The horizontal lines represent the median in each group. (B) Hyperparathyroidism: the relationship between the maximum registered value of serum PTH and phosphate dose (given as mg/kg per day elemental phosphorus) at the same time point.

phenotypic spectrum, and response to and complications of treatment in the Norwegian pediatric population. The prevalence of XLHR in Norwegian children was one in 60 000. Earlier reports from regional cohorts, with a risk of selection bias, have found the prevalence of XLHR to be ~1 in 20 000 (25, 26). Studies of large pedigrees of XLHR patients have reported a low penetrance of skeletal manifestations in hypophosphatemic female family members, whereas all hypophosphatemic males had skeletal manifestations of disease (27). Hence, there is a possibility of undiagnosed XLHR in Norwegian females from pedigrees without affected males. However, the ratio of female to male patients in our cohort was 16:5, as compared to the expected ratio of 2:1 for X-linked dominant disorders; a large proportion of undiagnosed females thus seems unlikely. Since our study included only children already in contact with health care and asymptomatic members of the pedigrees were not tested for hypophosphatemia, we cannot rule out hypophosphatemic second-degree relatives (28). It is therefore possible that the prevalence of HH and XLHR in the Norwegian pediatric population may be higher than one in 45 000 and one in 60 000 respectively.

We identified the genotype responsible for HH in 79% of pedigrees in this population-based cohort, and *PHEX* mutations comprised 87% of the verified mutations. This supports what has been found by others (29), and confirms that XLHR is the most common variant of HR. Of 13 *PHEX* mutations, nine (69%) had not been reported earlier (ExAC Browser accessed 21.05.15, <http://exac.broadinstitute.org/gene/ENSG00000102174>), demonstrating that most mutations are private in this gene (28). We have previously reported two male siblings with the first identified association between compound heterozygous mutations in *FAM20C* and *FGF23* dependent hypophosphatemia in humans (11). None of the patients had mutations in *FGF23*, *DMP1*, *ENPP1*, or *KL*, confirming that mutations in these genes rarely seem to be the cause of HH. In four patients we did not find the likely disease causing mutation. However, as illustrated by our finding of *FAM20C* mutations (11), there are possibilities of mutations in other genes associated with pathways involving *FGF23*, phosphate reabsorption, and tissue mineralization.

One adolescent male was compound heterozygous for mutations in the *SLC34A3* gene. He had no manifestations of rickets, normal growth and bone mineral density, and came to medical attention because of recurrent kidney stones, accompanied by hypercalcuria, hypophosphatemia, suppressed PTH, and high 1,25(OH)₂D. He had a

novel splicing mutation c.757-1G>A affecting the conserved splice donor site of intron 7, predicted to cause aberrant splicing, and a previously reported intronic deletion mutation, c.925+20_926-48del (15). Earlier studies have shown that about 10% of homozygous and 16% of compound heterozygous carriers of mutations in *SLC34A3* presented with renal calcifications, without evidence of skeletal involvement (30, 31). Thus, our case is consistent with a phenotypic and genotypic heterogeneity in *SLC34A3* related conditions, including HHRH.

When comparing non-sense *PHEX* mutations with missense *PHEX* mutations likely to reduce protein function, we did not find differences in growth, severity of skeletal or dental disease, or in the prevalence of treatment complications based on the type of mutation. Our findings confirm the results of another recent study (21), whereas other studies have suggested an association between truncating mutations and a more severe skeletal phenotype (32, 33, 34). However, even in subjects with the same genotype, the skeletal phenotype seems to be very variable and individual (35, 36). This might reflect influence from other genetic variants in mineralization and phosphate metabolism. Interestingly, it was recently reported that patients homozygous or heterozygous for the *FGF23* sequence variant c.C716T (p.T239M, rs7955866) had significantly lower levels of serum phosphate and lower renal Tmp/GFR than patients homozygous for the WT allele (37). Another research group have reported a weak, but significant association between the c.C716T variant of *FGF23* and lower Tmp/GFR and lower plasma intact PTH in healthy children and adults (38). In none of the studies, it was possible to show significantly higher levels of serum iFGF23 in subjects carrying the c.C716T variant.

Evaluation of phenotype in XLHR showed that growth was compromised, and there was a tendency for lower height z-scores in males than females. Also, we found a trend for males having a higher proportion of skeletal and dental manifestations than females. As discussed above, some studies points to a milder phenotype in females, with slight hypophosphatemia and mild or no overt skeletal disease (39, 40). There are also reports of slightly lower serum levels of phosphate (40, 41) and more severe skeletal disease in male than female XLHR patients (42). Other studies have reported no gender differences in skeletal phenotype (35, 43), but more severe dental phenotype in post pubertal males than females (35, 44). Thus, our findings support the notion of a more severe mineralization defect in males than females.

Dental involvement seemed to be less common in the patients who started treatment before 1 year of age, suggesting the importance of proper mineralization of dentin prior to the eruption of teeth (45). On the other hand, starting treatment before age 1 year did not lead to an improved height z-score at the last registered consultation. Some earlier studies have concluded that early start of treatment had a positive effect on linear growth (23, 46). In one study however, the height z-score was generally higher in those who started treatment before the age of 1 year compared with those who started later, but declined over time for those who started treatment early and improved in those who started treatment later (46). We found that treatment with phosphate and vitamin D improved mineral homeostasis and rickets, but did not fully correct skeletal axis deviation and to a lesser extent correct the growth deficiency in HR. This adds support to the theory that FGF23 may play a role in the normal physiology of mineralized tissues independently phosphate regulation (18). Treatment with phosphate will lead to transient increases in serum phosphate, which trigger production and release of FGF23 (47) and PTH (48), further aggravating the skeletal phenotype. Novel therapy with FGF23 neutralizing antibodies has shown that inhibition of excess FGF23 activity correct growth deficiency in mice (49), and anti-FGF23 antibodies are currently being tested in human XLHR (50, 51). It is possible that longitudinal growth in HH patients reflects the individual severity of and response to a disturbed FGF23 homeostasis, rather than the severity of hypophosphatemia itself.

The patients who developed nephrocalcinosis had started treatment earlier and had received higher daily doses of phosphate, but did not have better growth outcomes, than patients without nephrocalcinosis. Renal function remained normal in all patients, except for transient low-grade renal failure seen in the XLHR patient with tertiary HPT. Our results strengthen the association between higher phosphate doses and development of nephrocalcinosis found in earlier studies (52, 53, 54, 55). Early start of treatment as a risk factor for nephrocalcinosis has been found by some (52), but not by others (23, 46, 56). The prevalence of nephrocalcinosis in patients receiving combination therapy with phosphate and calcitriol is reported to be from 33 to 80% (median 59%) (23, 46, 52, 53, 54, 55, 56, 57, 58), but long term follow-up of mild nephrocalcinosis in XLHR does not seem to affect renal function (56). As discussed above, treatment with phosphate and calcitriol has a certain positive effect on growth, but only phosphate-treated patients develop nephrocalcinosis (54, 55, 56). This again probably

reflects that current treatment options are suboptimal, both when considering skeletal outcome and the rate of complications.

Elevated serum levels of PTH were found in ten of 15 XLHR patients before the start of treatment all patients developed HPT during the course of treatment. Our findings add to other reports of high normal or slightly elevated levels of PTH in hypophosphatemic untreated XLHR patients (59, 60, 61). In normal subjects, hypophosphatemia will, through an increase in $1,25(\text{OH})_2\text{D}$, reduce PTH levels (62). Evidence also suggests an inhibitory effect of FGF23 on PTH production (63). The explanation for the inappropriate PTH response in untreated HR, and the details of the interactions between phosphate, FGF23, and PTH, still need further clarification.

Secondary HPT caused by oral phosphate supplements can be counteracted by increasing the doses of calcitriol, with the risk of developing hypercalcuria and nephrocalcinosis, or by reducing the phosphate dose, with the risk of worsening rickets (64). However difficult, successful management of HPT in XLHR is important, as HPT has been associated with development of hypertension and renal failure (24, 65), cardiac failure (66), and also brown tumor in the mandible (67).

Two patients, one with XLHR, developed tertiary HPT after long-term use of phosphate supplements. The XLHR patient had received relatively high doses of phosphate and relatively low doses of alfacalcidol for more than 10 years. Tertiary HPT has been reported in 36 cases of HR (24, 65, 66, 68, 69, 70, 71, 72, 73, 74, 75), and prolonged treatment with high doses of phosphate supplements seems to be a risk factor (68, 71). There are reports of successful treatment of tertiary HPT with cinacalcet in children (24, 76) and adults (77, 78), but safety concerns have stopped further clinical trials investigating the effects of cinacalcet in children (79). A recent report suggests the vitamin D analog paricalcitol to suppress elevated PTH secondary to treatment in XLHR (80). However, careful monitoring of treatment, to ensure lowest efficient phosphate dose is very important to heal rickets and at the same time reduce the risk of tertiary HPT.

The observations from this study support recently published guidelines on treatment and monitoring of HR in children (64, 81). We recommend that combined treatment with oral phosphate and activated vitamin D (calcitriol or alfacalcidol) is started once the diagnosis has been made. Most children respond well to a calcitriol dose of 20–30 ng/kg per day (divided in two doses) or alfacalcidol 30–50 ng/kg per day (single dose) and an elemental phosphorous dose of 20–40 mg/kg per day

(divided in four doses) with reduced signs of rickets and skeletal deformities. The starting doses of phosphate should be kept low to reduce gastrointestinal side effects, and to avoid complications clinical and biochemical controls should be performed at least every 3 months, and supplemented with skeletal X-rays every 2 years and renal ultrasonography every 2–5 years. To avoid HPT, the aim should not be normalization of serum phosphate, but the lowest efficient dose that promote growth and heal rickets. To minimize the risk of nephrocalcinosis, hypercalcuria, defined as U-Ca/creatinine ratio >0.87 mmol/mmol should be avoided.

One strength of our study is related to the fact that combined data from the NPR and all pediatric centers in Norway allowed us to collect a complete national material of childhood HH. This allowed for the estimation of a national prevalence, and adds information to the literature on the epidemiology of hereditary HR. Moreover, we have identified new mutations in known and novel genes, expanding the genetic diversity of HH with and without rickets. On the other hand, the study is limited by the size of the cohort and the retrospective design, implying we could not ensure uniform collection of information from the clinical, biochemical, and radiological examinations. Furthermore, we did not do genetic testing on normophosphatemic, asymptomatic siblings, as predictive genetic testing on children is not allowed in Norway according to the Biotechnology Act. This means there is a possibility for undiagnosed subclinical cases.

In conclusion, we have presented the first complete national cohort of HH in children. The prevalence of XLHR seems to be lower in Norwegian children than reported earlier.

Supplementary data

This is linked to the online version of the paper at <http://dx.doi.org/10.1530/EJE-15-0515>.

Declaration of interest

The authors declare that there is no conflict of interest that could be perceived as prejudicing the impartiality of the research reported.

Funding

This research was supported by a PhD grant from the University of Bergen.

Author contribution statement

S Rafaelsen, H Ræder, S Johansson, and R Bjerknes designed the study; S Rafaelsen collected the data; whereas S Rafaelsen, H Ræder, S Johansson,

and R Bjerknes contributed to data analysis and interpretation. S Rafaelsen and R Bjerknes drafted the manuscript, whereas all authors contributed to the revision and approved the final version of the manuscript.

Acknowledgements

All patients and their families are thanked for making this study possible. We also thank the collaborating physicians Jon Bland at Stavanger University Hospital; Leif Brunvand, Anne Grethe Myhre, Kathrine Alsaker Heier, and Martin Heier at Oslo University Hospital; Torstein B Rø and Gunnhild Møllerløkken at St Olavs Hospital; Ketil Mevold, Dag Veimo, and Anne Kristine Fagerheim at Nordland County Hospital, Bodø; for recruiting patients. We thank the staff at the Laboratory of Centre of Medical Genetics and Molecular Medicine, Haukeland University Hospital, for expert technical support.

References

- Carpenter TO. The expanding family of hypophosphatemic syndromes. *Journal of Bone and Mineral Metabolism* 2012 **30** 1–9. (doi:10.1007/s00774-011-0340-2)
- Shimada T, Hasegawa H, Yamazaki Y, Muto T, Hino R, Takeuchi Y, Fujita T, Nakahara K, Fukumoto S & Yamashita T. FGF-23 is a potent regulator of vitamin D metabolism and phosphate homeostasis. *Journal of Bone and Mineral Research* 2004 **19** 429–435. (doi:10.1359/JBMR.0301264)
- Shimada T, Mizutani S, Muto T, Yoneya T, Hino R, Takeda S, Takeuchi Y, Fujita T, Fukumoto S & Yamashita T. Cloning and characterization of FGF23 as a causative factor of tumor-induced osteomalacia. *PNAS* 2001 **98** 6500–6505. (doi:10.1073/pnas.101545198)
- Drezner MK, Lyles KW, Haussler MR & Harrelson JM. Evaluation of a role for 1,25-dihydroxyvitamin D3 in the pathogenesis and treatment of X-linked hypophosphatemic rickets and osteomalacia. *Journal of Clinical Investigation* 1980 **66** 1020–1032. (doi:10.1172/JCI109930)
- Francis F, Hennign S, Korn B, Reinhardt R, de Jong P, Poustka A, Lehrach H, Rowe PSN, Goulding JN, Summerfield T *et al.* A gene (*PEX*) with homologies to endopeptidases is mutated in patients with X-linked hypophosphatemic rickets. The HYP Consortium. *Nature Genetics* 1995 **11** 130–136. (doi:10.1038/ng1095-130)
- White KE, Evans WE, O’Riordan JH, Speer MC, Econs MJ, Lorenz-Depiereux B, Grabowski M, Meitinger T & Strom TM. Autosomal dominant hypophosphatemic rickets is associated with mutations in FGF23. *Nature Genetics* 2000 **26** 345–348. (doi:10.1038/81664)
- Lorenz-Depiereux B, Bastepe M, Benet-Pages A, Amyere M, Wagenstaller J, Muller-Barth U, Badenhop K, Kaiser SM, Rittmaster RS, Shlossberg AH *et al.* DMP1 mutations in autosomal recessive hypophosphatemia implicate a bone matrix protein in the regulation of phosphate homeostasis. *Nature Genetics* 2006 **38** 1248–1250. (doi:10.1038/ng1868)
- Feng JQ, Ward LM, Liu S, Lu Y, Xie Y, Yuan B, Yu X, Rauch F, Davis SI, Zhang S *et al.* Loss of DMP1 causes rickets and osteomalacia and identifies a role for osteocytes in mineral metabolism. *Nature Genetics* 2006 **38** 1310–1315. (doi:10.1038/ng1905)
- Levy-Litan V, Hershkovitz E, Avizov L, Leventhal N, Bercovich D, Chalifa-Caspi V, Manor E, Buriakovsky S, Hadad Y, Goding J *et al.* Autosomal-recessive hypophosphatemic rickets is associated with an inactivation mutation in the ENPP1 gene. *American Journal of Human Genetics* 2010 **86** 273–278. (doi:10.1016/j.ajhg.2010.01.010)
- Lorenz-Depiereux B, Schnabel D, Tiosano D, Hausler G & Strom TM. Loss-of-function ENPP1 mutations cause both generalized arterial calcification of infancy and autosomal-recessive hypophosphatemic

- rickets. *American Journal of Human Genetics* 2010 **86** 267–272. (doi:10.1016/j.ajhg.2010.01.006)
- 11 Rafaelsen SH, Raeder H, Fagerheim AK, Knappskog P, Carpenter TO, Johansson S & Bjerknes R. Exome sequencing reveals FAM20c mutations associated with fibroblast growth factor 23-related hypophosphatemia, dental anomalies, and ectopic calcification. *Journal of Bone and Mineral Research* 2013 **28** 1378–1385. (doi:10.1002/jbmr.1850)
 - 12 Tagliabracci VS, Engel JL, Wiley SE, Xiao J, Gonzalez DJ, Nidumanda Appaiah H, Koller A, Nizet V, White KE & Dixon JE. Dynamic regulation of FGF23 by Fam20C phosphorylation, GalNAc-T3 glycosylation, and furin proteolysis. *PNAS* 2014 **111** 5520–5525. (doi:10.1073/pnas.1402218111)
 - 13 Wang X, Wang S, Li C, Gao T, Liu Y, Rangiani A, Sun Y, Hao J, George A, Lu Y *et al.* Inactivation of a novel FGF23 regulator, FAM20C, leads to hypophosphatemic rickets in mice. *PLoS Genetics* 2012 **8** e1002708. (doi:10.1371/journal.pgen.1002708)
 - 14 Brownstein CA, Adler F, Nelson-Williams C, Iijima J, Li P, Imura A, Nabeshima Y, Reyes-Mugica M, Carpenter TO & Lifton RP. A translocation causing increased α -klotho level results in hypophosphatemic rickets and hyperparathyroidism. *PNAS* 2008 **105** 3455–3460. (doi:10.1073/pnas.0712361105)
 - 15 Bergwitz C, Roslin NM, Tieder M, Loredio-Osti JC, Bastepe M, Abu-Zahra H, Frappier D, Burkett K, Carpenter TO, Anderson D *et al.* SLC34A3 mutations in patients with hereditary hypophosphatemic rickets with hypercalciuria predict a key role for the sodium-phosphate cotransporter NaPi-IIc in maintaining phosphate homeostasis. *American Journal of Human Genetics* 2006 **78** 179–192. (doi:10.1086/499409)
 - 16 Lorenz-Depiereux B, Benet-Pages A, Eckstein G, Tenenbaum-Rakover Y, Wagenstaller J, Tiosano D, Gershoni-Baruch R, Albers N, Lichtner P, Schnabel D *et al.* Hereditary hypophosphatemic rickets with hypercalciuria is caused by mutations in the sodium-phosphate cotransporter gene SLC34A3. *American Journal of Human Genetics* 2006 **78** 193–201. (doi:10.1086/499410)
 - 17 Glorieux FH, Scriver CR, Reade TM, Goldman H & Roseborough A. Use of phosphate and vitamin D to prevent dwarfism and rickets in X-linked hypophosphatemia. *New England Journal of Medicine* 1972 **287** 481–487. (doi:10.1056/NEJM19720927871003)
 - 18 Linglart A, Bissos-Duplan M, Briot K, Chaussain C, Esterle L, Guillaume-Czitrom S, Kamenicky P, Nevoux J, Prie D, Rothenbuhler A *et al.* Therapeutic management of hypophosphatemic rickets from infancy to adulthood. *Endocrine Connections* 2014 **3** R13–R30. (doi:10.1530/EC-13-0103)
 - 19 Juliusson PB, Roelants M, Nordal E, Furevik L, Eide GE, Moster D, Hauspie R & Bjerknes R. Growth references for 0–19 year-old Norwegian children for length/height, weight, body mass index and head circumference. *Annals of Human Biology* 2013 **40** 220–227. (doi:10.3109/03014460.2012.759276)
 - 20 Barth JH, Jones RG & Payne RB. Calculation of renal tubular reabsorption of phosphate: the algorithm performs better than the nomogram. *Annals of Clinical Biochemistry* 2000 **37** 79–81. (doi:10.1258/0004563001901371)
 - 21 Morey M, Castro-Feijoo L, Barreiro J, Cabanas P, Pombo M, Gil M, Bernabeu I, Diaz-Grande JM, Rey-Cordo L, Ariceta G *et al.* Genetic diagnosis of X-linked dominant hypophosphatemic rickets in a cohort study: tubular reabsorption of phosphate and 1,25(OH)₂D serum levels are associated with PHEX mutation type. *BMC Medical Genetics* 2011 **12** 116. (doi:10.1186/1471-2350-12-116)
 - 22 Statistics Norway. (<https://www.ssb.no/statistikkbanken/selectout/ShowTable.asp?Fileformat=2&Queryfile=20151120125141735872111NY3026&PLanguage=0&MainTable=NY3026&spotsize=36> Accession date Nov.4th 2015)
 - 23 Makitie O, Doria A, Kooh SW, Cole WG, Daneman A & Sochett E. Early treatment improves growth and biochemical and radiographic outcome in X-linked hypophosphatemic rickets. *Journal of Clinical Endocrinology and Metabolism* 2003 **88** 3591–3597. (doi:10.1210/jc.2003-030036)
 - 24 Raeder H, Shaw N, Netelenbos C & Bjerknes R. A case of X-linked hypophosphatemic rickets: complications and the therapeutic use of cinacalcet. *European Journal of Endocrinology* 2008 **159** (Suppl 1) S101–S105. (doi:10.1530/EJE-08-0383)
 - 25 Davies M & Stanbury SW. The rheumatic manifestations of metabolic bone-disease. *Clinics in Rheumatic Diseases* 1981 **7** 595–646.
 - 26 Beck-Nielsen SS, Brock-Jacobsen B, Gram J, Brixen K & Jensen TK. Incidence and prevalence of nutritional and hereditary rickets in southern Denmark. *European Journal of Endocrinology* 2009 **160** 491–497. (doi:10.1530/EJE-08-0818)
 - 27 Graham JB, Mc FV & Winters RW. Familial hypophosphatemia with vitamin D-resistant rickets. II: three additional kindreds of the sex-linked dominant type with a genetic analysis of four such families. *American Journal of Human Genetics* 1959 **11** 311–332.
 - 28 Gaucher C, Walrant-Debray O, Nguyen TM, Esterle L, Garabedian M & Jehan F. PHEX analysis in 118 pedigrees reveals new genetic clues in hypophosphatemic rickets. *Human Genetics* 2009 **125** 401–411. (doi:10.1007/s00439-009-0631-z)
 - 29 Beck-Nielsen SS, Brixen K, Gram J & Brusgaard K. Mutational analysis of PHEX, FGF23, DMP1, SLC34A3 and CLCN5 in patients with hypophosphatemic rickets. *Journal of Human Genetics* 2012 **57** 453–458. (doi:10.1038/jhg.2012.56)
 - 30 Abe Y, Nagasaki K, Watanabe T, Abe T & Fukami M. Association between compound heterozygous mutations of SLC34A3 and hypercalciuria. *Hormone Research in Paediatrics* 2014 **82** 65–71. (doi:10.1159/000360291)
 - 31 Dasgupta D, Wee MJ, Reyes M, Li Y, Simm PJ, Sharma A, Schlingmann KP, Janner M, Biggin A, Lazier J *et al.* Mutations in SLC34A3/NPT2c are associated with kidney stones and nephrocalcinosis. *Journal of the American Society of Nephrology* 2014 **25** 2366–2375. (doi:10.1681/ASN.2013101085)
 - 32 Rowe PS, Oudet CL, Francis F, Sinding C, Pannetier S, Econs MJ, Strom TM, Meitinger T, Garabedian M, David A *et al.* Distribution of mutations in the PEX gene in families with X-linked hypophosphatemic rickets (HYP). *Human Molecular Genetics* 1997 **6** 539–549. (doi:10.1093/hmg/6.4.539)
 - 33 Song HR, Park JW, Cho DY, Yang JH, Yoon HR & Jung SC. PHEX gene mutations and genotype–phenotype analysis of Korean patients with hypophosphatemic rickets. *Journal of Korean Medical Science* 2007 **22** 981–986. (doi:10.3346/jkms.2007.22.6.981)
 - 34 Cho HY, Lee BH, Kang JH, Ha IS, Cheong HI & Choi Y. A clinical and molecular genetic study of hypophosphatemic rickets in children. *Pediatric Research* 2005 **58** 329–333. (doi:10.1203/01.PDR.0000169983.40758.7B)
 - 35 Holm IA, Nelson AE, Robinson BG, Mason RS, Marsh DJ, Cowell CT & Carpenter TO. Mutational analysis and genotype–phenotype correlation of the PHEX gene in X-linked hypophosphatemic rickets. *Journal of Clinical Endocrinology and Metabolism* 2001 **86** 3889–3899. (doi:10.1210/jcem.86.8.7761)
 - 36 Econs MJ, Friedman NE, Rowe PS, Speer MC, Francis F, Strom TM, Oudet C, Smith JA, Ninomiya JT, Lee BE *et al.* A PHEX gene mutation is responsible for adult-onset vitamin D-resistant hypophosphatemic osteomalacia: evidence that the disorder is not a distinct entity from X-linked hypophosphatemic rickets. *Journal of Clinical Endocrinology and Metabolism* 1998 **83** 3459–3462. (doi:10.1210/jcem.83.10.5167)
 - 37 Rendina D, Esposito T, Morosetti G, De Filippo G, Gianfrancesco F, Perfetti A, Magliocca S, Formisano P, Prie D & Strazzullo P. A functional allelic variant of the FGF23 gene is associated with renal phosphate leak in calcium nephrolithiasis. *Journal of Clinical Endocrinology and Metabolism* 2012 **97** E840–E844. (doi:10.1210/jc.2011-1528)
 - 38 Pekkinen M, Laine CM, Makitie R, Leinonen E, Lamberg-Allardt C, Viljakainen H & Makitie O. FGF23 gene variation and its association with phosphate homeostasis and bone mineral density in Finnish

- children and adolescents. *Bone* 2015 **71** 124–130. (doi:10.1016/j.bone.2014.10.013)
- 39 Burnett CH, Dent CE, Harper C & Warland BJ. Vitamin D-resistant rickets. Analysis of twenty-four pedigrees with hereditary and sporadic cases. *American Journal of Medicine* 1964 **36** 222–232. (doi:10.1016/0002-9343(64)90085-3)
- 40 Reid IR, Hardy DC, Murphy WA, Teitelbaum SL, Bergfeld MA & Whyte MP. X-linked hypophosphatemia: a clinical, biochemical, and histopathologic assessment of morbidity in adults. *Medicine* 1989 **68** 336–352. (doi:10.1097/00005792-198911000-00002)
- 41 Winters RW, Mc FV & Graham JB. Genetic studies of vitamin D resistant rickets and familial hypophosphatemia. *Helvetica Paediatrica Acta* 1959 **14** 533–538.
- 42 Hardy DC, Murphy WA, Siegel BA, Reid IR & Whyte MP. X-linked hypophosphatemia in adults: prevalence of skeletal radiographic and scintigraphic features. *Radiology* 1989 **171** 403–414. (doi:10.1148/radiology.171.2.2539609)
- 43 Whyte MP, Schranck FW & Armamento-Villareal R. X-linked hypophosphatemia: a search for gender, race, anticipation, or parent of origin effects on disease expression in children. *Journal of Clinical Endocrinology and Metabolism* 1996 **81** 4075–4080. (doi:10.1210/jcem.81.11.8923863)
- 44 Shields ED, Scriver CR, Reade T, Fujiwara TM, Morgan K, Ciampi A & Schwartz S. X-linked hypophosphatemia: the mutant gene is expressed in teeth as well as in kidney. *American Journal of Human Genetics* 1990 **46** 434–442.
- 45 Chaussain-Miller C, Sinding C, Wolikow M, Lasfargues JJ, Godeau G & Garabedian M. Dental abnormalities in patients with familial hypophosphatemic vitamin D-resistant rickets: prevention by early treatment with 1-hydroxyvitamin D. *Journal of Pediatrics* 2003 **142** 324–331. (doi:10.1067/mpd.2003.119)
- 46 Quinlan C, Guegan K, Offiah A, Neill RO, Hiorns MP, Ellard S, Bockenbauer D, Hoff WV & Waters AM. Growth in PHEX-associated X-linked hypophosphatemic rickets: the importance of early treatment. *Pediatric Nephrology* 2012 **27** 581–588. (doi:10.1007/s00467-011-2046-z)
- 47 Imel EA, DiMeglio LA, Hui SL, Carpenter TO & Econs MJ. Treatment of X-linked hypophosphatemia with calcitriol and phosphate increases circulating fibroblast growth factor 23 concentrations. *Journal of Clinical Endocrinology and Metabolism* 2010 **95** 1846–1850. (doi:10.1210/jc.2009-1671)
- 48 Reiss E, Canterbury JM, Bercovitz MA & Kaplan EL. The role of phosphate in the secretion of parathyroid hormone in man. *Journal of Clinical Investigation* 1970 **49** 2146–2149. (doi:10.1172/JCI106432)
- 49 Aono Y, Yamazaki Y, Yasutake J, Kawata T, Hasegawa H, Urakawa I, Fujita T, Wada M, Yamashita T, Fukumoto S *et al*. Therapeutic effects of anti-FGF23 antibodies in hypophosphatemic rickets/osteomalacia. *Journal of Bone and Mineral Research* 2009 **24** 1879–1888. (doi:10.1359/jbmr.090509)
- 50 Carpenter TO, Imel EA, Ruppe MD, Weber TJ, Klausner MA, Wooddell MM, Kawakami T, Ito T, Zhang X, Humphrey J *et al*. Randomized trial of the anti-FGF23 antibody KRN23 in X-linked hypophosphatemia. *Journal of Clinical Investigation* 2014 **124** 1587–1597. (doi:10.1172/JCI12829)
- 51 Imel EA, Zhang X, Ruppe MD, Weber TJ, Klausner MA, Ito T, Vergeire M, Humphrey JS, Glorieux FH, Portale AA *et al*. Prolonged correction of serum phosphorus in adults with X-linked hypophosphatemia using monthly doses of KRN23. *Journal of Clinical Endocrinology and Metabolism* 2015 **100** 2565–2573. (doi:10.1210/jc.2015-1551)
- 52 Goodyer PR, Kronick JB, Jequier S, Reade TM & Scriver CR. Nephrocalcinosis and its relationship to treatment of hereditary rickets. *Journal of Pediatrics* 1987 **111** 700–704. (doi:10.1016/S0022-3476(87)80245-7)
- 53 Reusz GS, Hoyer PF, Lucas M, Krohn HP, Ehrlich JH & Brodehl J. X-linked hypophosphatemia: treatment, height gain, and nephrocalcinosis. *Archives of Disease in Childhood* 1990 **65** 1125–1128. (doi:10.1136/adc.65.10.1125)
- 54 Taylor A, Sherman NH & Norman ME. Nephrocalcinosis in X-linked hypophosphatemia: effect of treatment versus disease. *Pediatric Nephrology* 1995 **9** 173–175. (doi:10.1007/BF00860736)
- 55 Verge CF, Lam A, Simpson JM, Cowell CT, Howard NJ & Silink M. Effects of therapy in X-linked hypophosphatemic rickets. *New England Journal of Medicine* 1991 **325** 1843–1848. (doi:10.1056/NEJM199112263252604)
- 56 Kooh SW, Binet A & Daneman A. Nephrocalcinosis in X-linked hypophosphatemic rickets: its relationship to treatment, kidney function, and growth. *Clinical and Investigative Medicine. Médecine Clinique et Experimentale* 1994 **17** 123–130.
- 57 Alon U, Donaldson DL, Hellerstein S, Warady BA & Harris DJ. Metabolic and histologic investigation of the nature of nephrocalcinosis in children with hypophosphatemic rickets and in the Hyp mouse. *Journal of Pediatrics* 1992 **120** 899–905. (doi:10.1016/S0022-3476(05)81957-2)
- 58 Patzer L, van't Hoff W, Shah V, Hallson P, Kasidas GP, Samuël C, de Bruyn R, Barratt TM & Dillon MJ. Urinary supersaturation of calcium oxalate and phosphate in patients with X-linked hypophosphatemic rickets and in healthy schoolchildren. *Journal of Pediatrics* 1999 **135** 611–617. (doi:10.1016/S0022-3476(99)70060-0)
- 59 Carpenter TO, Mitnick MA, Ellison A, Smith C & Insogna KL. Nocturnal hyperparathyroidism: a frequent feature of X-linked hypophosphatemia. *Journal of Clinical Endocrinology and Metabolism* 1994 **78** 1378–1383. (doi:10.1210/jcem.78.6.8200940)
- 60 Rasmussen H, Pechet M, Anast C, Mazur A, Gertner J & Broadus AE. Long-term treatment of familial hypophosphatemic rickets with oral phosphate and 1 α -hydroxyvitamin D₃. *Journal of Pediatrics* 1981 **99** 16–25. (doi:10.1016/S0022-3476(81)80951-1)
- 61 Lewy JE, Cabana EC, Repetto HA, Canterbury JM & Reiss E. Serum parathyroid hormone in hypophosphatemic vitamin D-resistant rickets. *Journal of Pediatrics* 1972 **81** 294–300. (doi:10.1016/S0022-3476(72)80298-1)
- 62 Lanske B & Razaque MS. Molecular interactions of FGF23 and PTH in phosphate regulation. *Kidney International* 2014 **86** 1072–1074. (doi:10.1038/ki.2014.316)
- 63 Krajsnik T, Bjorklund P, Marsell R, Ljunggren O, Akerstrom G, Jonsson KB, Westin G & Larsson TE. Fibroblast growth factor-23 regulates parathyroid hormone and 1 α -hydroxylase expression in cultured bovine parathyroid cells. *Journal of Endocrinology* 2007 **195** 125–131. (doi:10.1677/JOE-07-0267)
- 64 Carpenter TO, Imel EA, Holm IA, Jan de Beur SM & Insogna KL. A clinician's guide to X-linked hypophosphatemia. *Journal of Bone and Mineral Research* 2011 **26** 1381–1388. (doi:10.1002/jbmr.340)
- 65 Alon US, Monzavi R, Lilien M, Rasoulpour M, Geffner ME & Yadin O. Hypertension in hypophosphatemic rickets – role of secondary hyperparathyroidism. *Pediatric Nephrology* 2003 **18** 155–158. (doi:10.1007/s00467-002-1044-6)
- 66 Sun GE, Suer O, Carpenter TO, Tan CD & Li-Ng M. Heart failure in hypophosphatemic rickets: complications from high-dose phosphate therapy. *Endocrine Practice* 2013 **19** e8–e11. (doi:10.4158/EP12184.CR)
- 67 Andrews RG, Baumhardt H, Martin B, Belachew D & Reyes-Mugica M. Oral manifestations of hyperparathyroidism secondary to familial hypophosphatemic rickets. *Pediatric Dentistry* 2014 **36** 422–424.
- 68 Makitie O, Kooh SW & Sochett E. Prolonged high-dose phosphate treatment: a risk factor for tertiary hyperparathyroidism in X-linked hypophosphatemic rickets. *Clinical Endocrinology* 2003 **58** 163–168. (doi:10.1046/j.1365-2265.2003.01685.x)
- 69 Tournis S, Georgoulas T, Zafeiris C, Papalexis C, Petraki K & Lyrakis GP. Tertiary hyperparathyroidism in a patient with X-linked hypophosphatemic rickets. *Journal of Musculoskeletal & Neuronal Interactions* 2011 **11** 266–269.
- 70 Neal MD, Deslouches B & Ogilvie J. The use of pre-operative imaging and intraoperative parathyroid hormone level to guide surgical

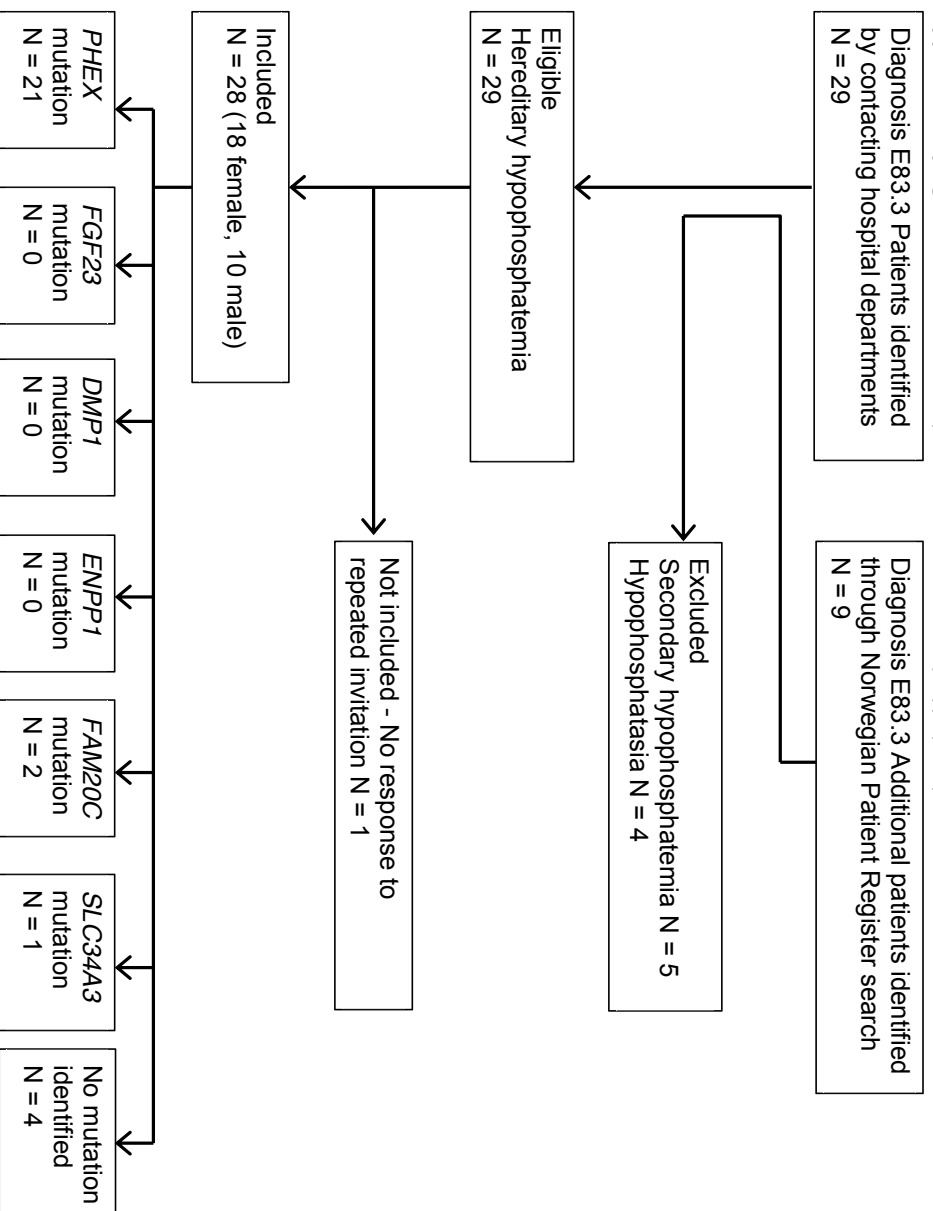
- management of tertiary hyperparathyroidism from X-linked hypophosphatemic rickets: a case report. *Cases Journal* 2009 **2** 7572. (doi:10.4076/1757-1626-2-7572)
- 71 McHenry CR, Mostafavi K & Murphy TA. Tertiary hyperparathyroidism attributable to long-term oral phosphate therapy. *Endocrine Practice* 2006 **12** 294–298. (doi:10.4158/EP.12.3.294)
- 72 Savio RM, Gosnell JE, Posen S, Reeve TS & Delbridge LW. Parathyroidectomy for tertiary hyperparathyroidism associated with X-linked dominant hypophosphatemic rickets. *Archives of Surgery* 2004 **139** 218–222. (doi:10.1001/archsurg.139.2.218)
- 73 Wu CJ, Song YM & Sheu WH. Tertiary hyperparathyroidism in X-linked hypophosphatemic rickets. *Internal Medicine* 2000 **39** 468–471. (doi:10.2169/internalmedicine.39.468)
- 74 Moreno Molina JA, Lopez Siguero JP, Bueno Fernandez A, Martinez-Aedo Ollero MJ & Martinez Valverde A. Tertiary hyperparathyroidism during the treatment of familial hypophosphatemic rickets. *Anales Españoles de Pediatría* 1996 **45** 193–195.
- 75 Knudtzon J, Halse J, Monn E, Nesland A, Nordal KP, Paus P, Seip M, Sund S & Sodal G. Autonomous hyperparathyroidism in X-linked hypophosphatemia. *Clinical Endocrinology* 1995 **42** 199–203. (doi:10.1111/j.1365-2265.1995.tb01863.x)
- 76 Alon US, Levy-Olomucki R, Moore WV, Stubbs J, Liu S & Quarles LD. Calcimimetics as an adjuvant treatment for familial hypophosphatemic rickets. *Clinical Journal of the American Society of Nephrology* 2008 **3** 658–664. (doi:10.2215/CJN.04981107)
- 77 Grove-Laugesen D & Rejnmark L. Three-year successful cinacalcet treatment of secondary hyperparathyroidism in a patient with X-linked dominant hypophosphatemic rickets: a case report. *Case Reports in Endocrinology* 2014 **2014** 479641. (doi:10.1155/2014/479641)
- 78 Yavropoulou MP, Kotsa K, Gotzamani Psarrakou A, Papazisi A, Tranga T, Ventis S & Yovos JG. Cinacalcet in hyperparathyroidism secondary to X-linked hypophosphatemic rickets: case report and brief literature review. *Hormones* 2010 **9** 274–278. (doi:10.14310/horm.2002.1277)
- 79 US Food and Drug Administration. Sensipar (cinacalcet hydrochloride): drug safety communication. FDA suspends pediatric clinical trials after report of death: US Food and Drug Administration, 2013. (<http://www.fda.gov/Safety/MedWatch/SafetyInformation/SafetyAlertsforHumanMedicalProducts/ucm341255.htm> Accession date Nov.4th 2015)
- 80 Carpenter TO, Olear EA, Zhang JH, Ellis BK, Simpson CA, Cheng D, Gundberg CM & Insogna KL. Effect of paricalcitol on circulating parathyroid hormone in X-linked hypophosphatemia: a randomized, double-blind, placebo-controlled study. *Journal of Clinical Endocrinology and Metabolism* 2014 **99** 3103–3111. (doi:10.1210/jc.2014-2017)
- 81 Imel EA & Carpenter TO. A practical clinical approach to paediatric phosphate disorders. *Endocrine Development* 2015 **28** 134–161. (doi:10.1159/000381036)

Received 24 May 2015

Revised version received 2 October 2015

Accepted 4 November 2015

Supplementary figure 1 Recruitment of patients with hereditary hypophosphatemia¹



¹Exclusion criteria:

- Primary hyperparathyroidism is characterized by elevated or high normal levels of serum intact parathyroid hormone combined with serum calcium above upper normal reference range.
- Secondary hyperparathyroidism in renal failure or malabsorption
- Tertiary hyperparathyroidism is diagnosed in patients with secondary hyperparathyroidism, when elevated levels of serum intact PTH and serum calcium persist upon withdrawal of the stimulus for secondary hyperparathyroidism.
- Vitamin D dependent rickets types I and II are characterized by hypocalcemia combined with low 1,25 (OH)₂ vitamin D; hypocalcemia is not a feature of hypophosphatemic rickets.
- Fanconi syndrome or other tubulopathy,
- Vitamin D deficiency

Hypophosphatemia secondary to acute metabolic derangements.

Supplementary table 1 PHEX mutations in the Norwegian cohort of childhood hereditary hypophosphatemia

Family	N=	Region	Nucleotide change	Amino acid change	Effect	SIFT	Polyphen	Previously reported
3	2	E 6-9	c.664-?_1079+?dup	p.222-360dup	Duplication			No
5	3	E 17	c.1735G>A	p.G579R	P.d.	0	1.0	Yes(1)
6	3	E 7	c.793delT	p.S265PfsX6	Truncation			No
7	1	E 18	c.1878T>G	p.Y626X	Truncation			No
8	2	I 15	c.1646-2a>g		Splice site affected			P.d.
9	1	E 15	c.1645delC	p.R549DfsXX20	Truncation			No
10	1	E 17	c.1745T>C	p.F582S	P.d.	0	0.986	No
11	1	I 10	c.1174-1g>a		Splice site affected			P.d.
12	2	E 1	c.58G>T	p.R20X	Truncation			Yes(1)
15	1	E 21	c.2137_2139del	p.P713del	Deletion			No
17	1	E 8	c.914T>C	p.L305P	P.d.	0	0.999	Yes (3)
24	2	E 9	c.975_1001del	p.R325_1333del	P.d.			No
27	1	E 11	c.1255G>A	p.G419R	P.d.	0.35	1.0	No

- Rowe PS, Oudet CL, Francis F, Sinding C, Pannetier S, Econs MJ, Strom TM, Meitinger T, Garabedian M, David A, Macher MA, Questiaux E, Popowska E, Pronicka E, Read AP, Mokrzycki A, Glorieux FH, Drezner MK, Hanauer A, Lehrach H, Goulding JN & O'Riordan JL. Distribution of mutations in the PEX gene in families with X-linked hypophosphataemic rickets (HYP). *Human Molecular Genetics* 1997 **6** 539-549.
- Song HR, Park JW, Cho DY, Yang JH, Yoon HR & Jung SC. PHEX gene mutations and genotype-phenotype analysis of Korean patients with hypophosphatemic rickets. *Journal of Korean Medical Science* 2007 **22** 981-986.
- Raeder H, Shaw N, Netelenbos C & Bjerknes R. A case of X-linked hypophosphatemic rickets: complications and the therapeutic use of cinacalcet. *European Journal of Endocrinology of the European Federation of Endocrine Societies* 2008 **159** Suppl 1 S101-105.

Supplementary table 2a Phenotype-, treatment- and complication characteristics of XLHR patients¹

Time of diagnosis										Treatment details					Last registered consultation				
Family number	Sex	Age	Height z-score	Skeletal involvement	S-phosphate mmol/L	S-ALP U/L	S-iPTH pmol/L	TmP/GFR mmol/L	Age at start of treatment	Elemental phosphorus start dose (mg/kg/d)	Elemental phosphorus mean dose (mg/kg/d)	Alfacalcidol start dose (ng/kg/d)	Alfacalcidol mean dose (ng/kg/d)	Age	Height z-score	Dental involvement	Hyperparathyroidism	Nephrocalcinosis	Persistent bowing
3	F	6y4m	-1.98	+	0.74	362	5.3	0.64	6y8m	15.8	28.3	15.4	25.9	7y2m	-2.4	-	+/+	-	+
3	F	2y0m	-1.39	+	0.86	375	7.4	0.71	NA	0	0	0	0	2y0m	-1.39	-	+/+	-	+
5	F	0y2m	-0.07	-	1.16	791	NA	NA	0y3m	103.3	60.6	16.7	44.2	16y3m	-1.39	-	+/+	+	-
5	F	0y1m	-0.92	-	1.53	1099	NA	NA	0y2m	31.6	56.9	25.3	48.2	13y9m	-0.5	-	+/+	+	-
5	F	0y3m	-0.74	-	1.2	796	NA	NA	0y11m	40.8	62.4	32.6	39.1	7y5m	-1	-	+/+	+	-
6	M	0y8m	0.51	-	0.8	687	NA	0.83	0y10m	10.8	64	16.3	48	6y11m	-2.59	+	+/+	-	+
6	F	4y5m	0.52	+	0.76	533	7.3	0.77	4y5m	10	60	40	30	12y1m	-0.53	+	+/+	+	+
6	F	2y3m	-0.1	+	0.9	583	14	NA	2y7m	29.1	28.6	17.4	17.2	3y2m	-0.07	-	+/+	-	-
7	F	2y1m	-2.54	+	0.7	411	7.9	NA	2y1m	21.7	66.6	17	23.9	11y4m	-1.26	+	+/+	-	-
8	F	0y11m	-2.75	+	0.63	339	5.7	NA	0y11m	10	29.9	13.3	24.6	1y4m	-2.34	-	+/+	-	-
8	M	0y11m	-1.88	+	0.72	598	14.6	0.73	1y0m	38.4	60.8	23.3	49.4	11y4m	-2.22	-	+/+	+	+
9	M	0y6m	-2.97	+	0.8	349	8.2	NA	0y6m	15.1	31.7	14.7	53.8	14y11m	-0.97	+	+/+	+	+/OT
10	F	2y6m	NA	NA	0.77	NA	NA	NA	NA	NA	NA	NA	NA	17y4m	NA	+	NA	NA	NA
11	M	3y1m	-3.27	+	0.9	351	7.1	0.9	3y7m	53.4	39	28.8	36.6	16y1m	-2	+	+/+	-	-
12	F	0y5m	0.58	-	1.43	731	9.5	1.17	0y7m	23.8	11.1	14.3	37.9	10y9m	-1.48	-	+/+	-	-
12	F	0y4m	-0.87	-	1.14	628	5.6	0.92	0y5m	19	13.4	17.1	33.7	5y9m	-1.78	-	+/+	+	+
15	F	0y8m	-1.96	+	0.77	440	5.3	NA	1y2m	27	34.6	29.1	31.5	8y5m	-2.29	-	NA/T	+	-
17	F	0y5m	0.99	-	1.36	782	NA	NA	0y5m	69.3	74.1	29.9	17.2	18y0m	0.79	+	+/+	+	-
24	F	6y6m	-6.51	+	0.9	1460	9.1	NA	6y7m	26	NA	27	NA	7y4m	-6.31	+	+/+	-	+
24	M	15y6m	-5.11	+	0.92	734	6.4	NA	15y7m	66	NA	20	NA	16y4m	-5.1	+	+/+	-	+/OT
27	F	3y4m	0.34	+	0.8	366	3.1	0.76	3y4m	15	30	18	18	3y7m	0.34	-	+/+	-	+

¹ Abbreviations: F = female; M = male; NA = not available. For skeletal involvement, dental involvement, nephrocalcinosis and persistent bowing: "-" = "no" and "+" = "yes". OT = osteotomy. For hyperparathyroidism: "-/+/" = "no before start of treatment/yes during treatment"; "+/+/" = "yes before start of treatment/yes during treatment". T = tertiary hyperparathyroidism.

Supplementary table 2b Phenotype-, treatment- and complication characteristics of non-XLHR patients with hereditary hypophosphatemia²

Gene	Family number	Sex	Age	Time of diagnosis							Treatment details					Last registered consultation					
				Height z-score	Skeletal involvement	S-phosphate mmol/L	S-ALP U/L	S-iPTH pmol/L	TmP/GFR mmol/L	Age at start of treatment	Elemental phosphorus start dose (mg/kg/d)	Elemental phosphorus mean dose (mg/kg/d)	Alfacalcidol start dose (ng/kg/d)	Alfacalcidol mean dose (ng/kg/d)	Age	Height z-score	Dental involvement	Hyperparathyroidism	Nephrocalcinosis	Persistent bowing	
FAM20C	1	M	3 y 8 m	-0.8	-	1.02	216	2.5	NA	NA	3 y 8 m	NA	NA	NA	NA	16 y 3 m	-1.38	+	+/+	-	-
	1	M	5 y 11 m	0.64	-	1.26	379	NA	NA	NA	5 y 11 m	NA	NA	NA	NA	18 y 0 m	0.56	+	+/+	-	-
SLC34A3	28	M	12 y 0 m	0.17	-	1.17	243	0.3	1.42	NO	NO	10.6	51.6	24.2	38	12 y 0 m	0.17	-	-	+	-
	2	M	3 y 4 m	-3.05	+	0.65	915	8.6	0.45	3 y 4 m	10.6	51.6	24.2	38	17 y 11 m	-2.43	+	+/+	-	+	
Unknown	13	F	1 y 10 m	NA	+	0.8	504	NA	NA	1 y 10 m	NA	43.1	NA	61.2	18 y 0 m	-1.55	+	NA/T	+	+	
	14	F	5 y 10 m	0.46	+	0.54	489	2.3	NA	5 y 11 m	NA	NA	NA	NA	17 y 8 m	0.04	-	+/+	-	NA	
	16	M	2 y 0 m	-1.89	+	1.14	466	13.6	NA	5 y 10 m	20	11.8	20	17.6	16 y 4 m	-3.79	-	+/+	-	+/OT	

² Abbreviations: F = female; M = male; NA = not available. For skeletal involvement, dental involvement, nephrocalcinosis and persistent bowing: "-/-" = "no" and "+/" = "yes". OT = osteotomy. For hyperparathyroidism: "-/-/+" = "no before start of treatment/yes during treatment"; "+/+/" = "yes before start of treatment/yes during treatment". T = tertiary hyperparathyroidism.

Paper II



Paper III

RESEARCH ARTICLE

Open Access

Long-term clinical outcome and phenotypic variability in hyperphosphatemic familial tumoral calcinosis and hyperphosphatemic hyperostosis syndrome caused by a novel *GALNT3* mutation; case report and review of the literature

Silje Rafaelsen^{1*}, Stefan Johansson^{1,2}, Helge Ræder^{1,3} and Robert Bjerknes¹

Abstract

Background: Hyperphosphatemic Familial Tumoral Calcinosis (HFTC) and Hyperphosphatemic Hyperostosis Syndrome (HHS) are associated with autosomal recessive mutations in three different genes, *FGF23*, *GALNT3* and *KL*, leading to reduced levels of fibroblast growth factor 23 (FGF23) and subsequent clinical effects.

Results: We describe a consanguineous family with two affected siblings with HFTC and HHS caused by a novel homozygous G-to T substitution in exon 3 of *GALNT3* (c.767 G > T; p.Gly256Val), demonstrating great phenotypic variation and long asymptomatic intervals. Calcific tumors appeared at 14 years of age in the male, and the female displayed episodic diaphysitis from age 9 years. Symptoms of eye involvement were present in both from childhood, and progressed into band keratopathy in the female. Abnormal dental roots and tooth loss, as well as myalgia were present in both from their mid-twenties, while the female also had calcifications in the placenta, the iliac vessels and thyroid cartilage. New calcific tumors appeared more than 20 years after the initial episodes, delaying diagnosis and treatment until the ages of 37 and 50 years, respectively. Both siblings had elevated serum phosphate levels, inappropriately elevated tubular maximum phosphate reabsorption per unit glomerular filtration rate (TmP/GFR), reduced levels of intact FGF23 and increased levels of c-terminal FGF23. Review of all 54 previously published cases of *GALNT3*, *FGF23*, and *KL* associated HFTC and HHS demonstrated that more subjects than previously recognized have a combined phenotype.

Conclusion: We have described HFTC and HHS in a consanguineous Caucasian family with a novel *GALNT3* mutation, demonstrating new phenotypic features and significant variability in the natural course of the disease. A review of the literature, show that more subjects than previously recognized have a combined phenotype of HFTC and HHS. HHS and HFTC are two distinct phenotypes in a spectrum of *GALNT3* mutation related calcification disorders, where the additional factors determining the phenotypic expression, are yet to be clarified.

Keywords: Familial hyperphosphatemia, Hyperphosphatemic familial tumoral calcinosis, Hyperphosphatemia hyperostosis syndrome, *GALNT3*, *FGF23*

* Correspondence: Silje.Rafaelsen@k2.uib.no

¹Department of Clinical Science, University of Bergen, Bergen, Norway

Full list of author information is available at the end of the article

Background

The last decade has brought new insight into the molecular and pathophysiological aspects of phosphate metabolism. Previously, the regulation of serum and body phosphate was thought to be merely a consequence of the regulation of calcium levels by parathyroid hormone (PTH) and vitamin D. It is now accepted that the regulation of phosphate is specific, and involves phosphatonins, in particular fibroblast growth factor 23 (FGF23) [1].

Hyperphosphatemic familial tumoral calcinosis (HFTC) is a rare monogenic disorder with disturbances in the hormonal regulation of phosphate levels by FGF23, leading to soft tissue calcifications [2]. Hyperphosphatemic hyperostosis syndrome (HHS) is characterized by hyperphosphatemia and episodes of diaphysitis and cortical hyperostosis visualized on x-rays. This was thought to be a separate entity, rarely occurring together with HFTC, but it has later been shown that the same genes and same mutations are involved in both HHS and HFTC. This has led to the current opinion, that HHS and HFTC are different manifestations of the same genetic defect, and that in some families the same mutation can lead to either phenotype [3-5]. Both conditions are caused by inactivating mutations in either the *FGF23* gene encoding the phosphaturic hormone FGF23 [6,7], or the *GALNT3* gene encoding the UDP-N-acetyl-alpha-D-galactosamine:polypeptide N-acetylgalactosaminyltransferase 3 (GalNAc-T3) enzyme [8]. This enzyme is necessary to glycosylate FGF23, thereby preventing the break down and inactivation of the functional full-length version of the protein [9]. There is also one report of HFTC caused by an inactivating mutation in the *KL* gene, encoding α -Klotho, which is an essential co-receptor for the FGF23 receptor function in phosphate regulation [10].

GALNT3-associated HHS and HFTC are rarely found in Caucasians [11]. In this report we describe a consanguineous family of Norwegian origin, with a novel homozygous mutation in exon 3 of *GALNT3*, where diagnosis and treatment were delayed until late adulthood. In addition to new phenotypic features, the cases demonstrate the significant variability in the natural course of the disease, and how features of HFTC and HHS can be substantially overlapping with time, even in the same patient.

Methods

Patients

The family was recruited from a national population-based cohort of familial hyperphosphatemia in Norway. Written informed consent was obtained from all study participants. The study was approved by the Regional Committee for Medical and Health Research Ethics, Region West, Norway (REK number 2009/1140).

Biochemical parameters

Blood samples were collected after an overnight fast. Circulating levels of calcium, albumin, phosphate and alkaline phosphatase (ALP) activity in serum were analyzed using the Modular P-system from Roche Diagnostics (Basel, Switzerland). PTH was measured with a two-site chemiluminescent enzyme-labeled immunometric assay for intact PTH (Immulate 2000, Siemens Healthcare Diagnostics, Deerfield, IL, USA). Measurement of 25(OH)D levels was performed using an in-house developed liquid chromatography double mass spectrometry (LC-MS/MS) method [12]. A spot sample of urine collected at the time of blood sampling was analyzed for calcium, phosphorus and creatinine. The maximal tubular reabsorption of phosphate per glomerular filtration rate (TmP/GFR) was calculated according to the algorithm based on the nomogram of Walton and Bijvoet [13,14]. Plasma intact FGF23 (iFGF23) was measured with the FGF23-ELISA kit (Kainos Laboratories, Japan), with a lower detection limit of 3 pg/ml and a coefficient of variation (CV) of 4%. Plasma C-terminal FGF23 (cFGF23) was measured using the FGF23 second generation C-terminal ELISA kit (Immutopics, San Clemente, CA, USA), with a lower detection limit of 1.5 RU/ml and a CV of 4.7%.

Bone mineral density

The bone mineral density (BMD) of the right hip and lumbar spine was measured with dual X-ray absorptiometry (DXA) using Hologic Delphi W (Hologic inc., Bedford, Massachusetts, USA).

Genetic analysis

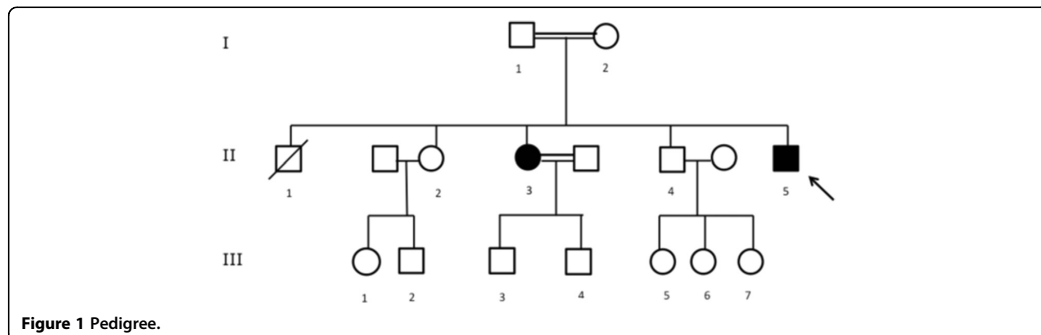
Genomic DNA was purified from blood using the QiaSymphony system (Qiagen, Hilden, Germany).

All exons and intron-exon boundaries, of *GALNT3*, *KL* and *FGF23* were sequenced in subject 1 (the index case). Only exon 3 of *GALNT3* was sequenced in subject 2 as well as in the 7 asymptomatic family members (Subjects I-2, II-2, II-4, III-1, III-3, IV-1, IV-2 in Figure 1) and 192 healthy blood donors.

DNA targets were first amplified by polymerase chain reaction (PCR) (list of primers available upon request) using the AmpliTaq Gold[®] DNA polymerase system (Applied biosystems, Life biosystems, Carlsbad, California, USA. PCR amplicons were purified with 2 μ l of ExoSapIT[®]. Using the Big Dye Terminator[®] chemistry sequencing was performed on the 3730 DNA analyzer, (Applied biosystems) and analyzed using the SeqScape[®] software (Applied biosystems).

Strategy of the literature review

We searched PubMed and EmBase for case reports on HFTC and HHS caused by mutations in *GALNT3*, *FGF23* and *KL* using the search terms "hyperphosphatemic tumoral calcinosis", "hyperphosphatemia hyperostosis syndrome",



"*GALNT3* mutation" and "*FGF23* mutation" and "*KL* mutation". Some cases and pedigrees were described in several papers, including earlier papers on the clinical presentation and later papers describing disease progression and genetic diagnose. In these cases we included all papers. We did not include case reports describing pedigrees or cases where a genetic diagnosis was not made.

Results

Case reports

Subject 1 is a Caucasian male, the youngest of five siblings of a consanguineous marriage (Table 1); the parents have a common ancestor eight generations back. He presented with a calcified mass on his right elbow at age 14. This mass was removed, the histological diagnosis was tumoral calcinosis, but no treatment or follow up was initiated. Prior to this episode he had chronic conjunctival irritation and abnormal dental roots shown on x-ray. Dental abscesses and spontaneous tooth loss started at 25 years of age. There were no new calcific tumors until the age of 35, when he developed a tender mass in his left gluteal area. He was eventually diagnosed with HFTC at age 37, when he presented with a 6 × 8 cm calcification over his left ischial tuberosity (Figure 2a), hyperphosphatemia, an inappropriately high TmP/GFR of 1.46 and TRP 84%. His renal function and serum calcium were normal. Serum 1,25 dihydroxyvitamin D3 was inappropriately normal in the setting of hyperphosphatemia and serum intact PTH was low (Table 2). Therapy with the phosphate binder Sevelamer 1600 mg three times daily was started, but the patient discontinued medication after one year due to non-

medical circumstances. At age 41 his left gluteal mass had increased further, to the degree that it restricted his daily activity. Spontaneous rupture of the overlying skin resulted in discharge of a white matter and transient pain relief, but there was rapid relapse. Sevelamer 4.8-6.4 g per day was tried once again, but had no effect on tumor size or serum phosphate levels.

At 42 years old his left gluteal mass had not decreased despite treatment for one year. He had general myalgia, with pain and stiffness in calves and forearms after slight activity. Clinical examination revealed a large, tender mass in the left gluteal area, displacing the natal cleft to the right, and the calves felt hard on palpation. Eye examination revealed salt-like conjunctival deposits. All his permanent teeth had been substituted by implants, but dental health was otherwise good. His height was 172.2 cm, head circumference was 59 cm and blood pressure was 110/80 mmHg. Computerized tomography of the kidneys and abdomen was normal. Bone mineral density (BMD) of the femoral neck and total hip was relatively high (T-scores 1.3 and 1.9; Z-scores 1.9 and 2.2, respectively), while lumbar spine BMD was normal (T-score 0.4; Z-score 0.5). In conclusion, he has had manifestations of classic HFTC from childhood. The long interval between development of calcific tumors has delayed diagnosis and treatment.

Subject 2 is the older sister of subject 1. She was diagnosed with HFTC at the age of 50 upon serum phosphate screening of the first-degree relatives of subject 1. A review of her past medical record revealed an episode of several cutaneous tumors on her scalp at three weeks of age. At age six years she had a large tumor in the gluteal

Table 1 FGF23 levels

Individual ¹	Ref. range	Unit	I-2	II-2	II-3	II-4	II-5	III-1	III-3
Genotype ²			M/m	M/m	m/m	M/M	m/m	M/M	M/m
i-FGF23	21.6-70.2 ³	pg/ml	66.3	51	26.8	33.0	12	47.2	53
c-FGF23	10-80 ²	RU/ml	32.2	25.2	120	34.8	210	17.2	20.2

¹Individuals, as presented in Figure 1.

²M = wild-type allele; m = mutant allele.

³Reference range valid for the laboratory used for this study.

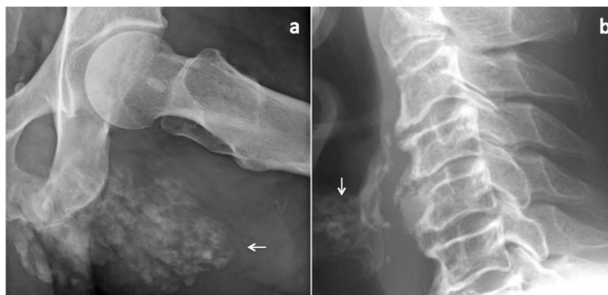

Figure 2 Radiographic findings. The pictures show **a)** the left gluteal calcification in subject 1, and **b)** age-inappropriate thyroid cartilage calcifications in subject 2.

area, and at age seven years a large tumor on her right thigh; both tumors were incised, but no diagnose is noted in her medical records. Between the ages of nine and 12 years, she had three episodes of unilateral leg pain lasting for several weeks and treated with antibiotics for suspected osteomyelitis; blood cultures were sterile and x-rays showed sclerosis of the tibia and periosteal thickening with onionskin configuration. At age 25 she had a new episode of leg pain, but this time the radiological examinations were negative, and she received no treatment. From her twenties, she has had conjunctival irritation and dental problems similar to her brother. At age 22 she gave birth to a healthy boy one week before term date after an uneventful pregnancy; the placenta was highly calcified, but the baby had no signs of intrauterine growth restriction (birth weight 3400 g, length 51 cm, head circumference 36 cm). Her second pregnancy was uncomplicated, but birth records are not available. She has had no stillbirths or spontaneous abortions.

In adulthood her chief complaint has been myalgia, stiffness of knees, hips and shoulders, and pain and deformities of her fingers and feet. The clinical findings resembled osteoarthritis, but the rheumatologic diagnostic work up was inconclusive. X-rays showed pronounced calcifications and degenerative changes in and around the phalanges of her hands and feet, calcifications of soft tissues in the foot, large bilateral calcaneal enthesopathies and age-inappropriate calcification of the thyroid cartilage (Figure 2b). Blood tests at age 50 (Table 2) revealed hyperphosphatemia, normal kidney function and inappropriately elevated renal tubular reabsorption of phosphate. The serum level of calcium was slightly elevated, but the serum levels of PTH and 1.25 (OH)₂ vitamin D₃ were not available.

At 55 years of age she had been treated with Sevelamer 800 mg per day for the previous three years, and both her symptoms and serum phosphate level had remained stable. Clinical examination revealed a height of 163.3 cm, head circumference was 56 cm and blood pressure was 120/70 mmHg. She had salt-like deposits on her bulbar conjunctiva, and the ophthalmology report confirmed band keratopathy but normal vision. She had some dental implants but good dental health. Findings in her hands, knees and hips were as previously noted. In addition her calves felt stiff on palpation. Computerized urography showed normal kidneys, but calcifications in the iliac vessels. BMDs of the femoral neck, total hip and lumbar spine were all normal (T-scores 1.5, 0.5 and 0.4; Z-scores 2.6, 1.2 and 1.5, respectively). We conclude in retrospect that she first manifested symptoms HHS in childhood, and that the absence of calcific tumors has led to delayed diagnosis.

Biochemical profile at the time of diagnosis and inclusion is given in Table 2.

FGF23

The plasma intact and c-terminal FGF23 were measured at enrolment. The level of intact FGF23 was decreased and c-terminal FGF23 was elevated in the two affected

Table 2 Biochemical profiles at diagnosis (T1) and inclusion (T2)

Parameter	Normal range	Unit	Subject 1		Subject 2	
			T1	T2	T1	T2
s-Phosphate	M: 0.85-1.65	mmol/L	1.81	2.21	1.6 - 1.84	1.36
	F: 0.85-1.50					
s-Calcium	2.15-2.51	mmol/L	2.37	2.36	2.5	2.64
s-iPTH	1.6-6.9	pmol/L	0.8	1.4	NA	5.2
s-Creatinine	M: 60-105	μmol/L	72	78	73	61
	F: 45-90					
i-FGF23	26.1-70.2 ¹	pg/ml	NA	12	NA	26.8
c-FGF23	10-80 ¹	RU/ml	NA	210	NA	120
1,25(OH) ₂ vit D	50-150	nmol/L	85	87	NA	54
TmP/GFR	> 0.85	mmol/L	1.46	2.07	1.41	1.12
TRP	> 80	%	84	94	88	82.5

¹Reference range valid for the laboratory used for this study.

subjects (Table 1); the deviation from normal was more pronounced in the male than in the female. The unaffected healthy family members had normal levels of iFGF23 and cFGF23 (Table 1).

Genetic analysis

Subject 1 was screened for mutations in all exons of *FGF23*, *GALNT3* and *KL*. No mutations were found in *FGF23* or *KL*, but a novel homozygous G-to T substitution in exon 3 of *GALNT3* (c.767 G > T) was identified, resulting in an amino acid change in position 256 (p.Gly256Val) (Figure 3). Subject 2 was also homozygous for this mutation, while her son and mother were heterozygous carriers. Subjects II-2, II-4, III-1, IV-1 and IV-2 did not carry the mutation. This substitution was not found in 192 healthy blood donors.

The detected mutation is not described in available databases and both the nucleotide and amino acid positions are highly conserved (phyloP: 5.86 and conserved up to *C. elegans*), and the variant is predicted as pathogenic by several prediction programs such as Polyphen2 [15], Align GVGD, MutationTaster and SIFT.

Review of the literature

A summary of all articles describing HFTC and HHS in subjects with *GALNT3*, *FGF23* and *KL* mutation is given in Additional file 1: Table S1.

In addition to the two subjects in this report, our search of the literature identified a total of 40 articles describing 54 affected subjects. This gives a total of 56 subjects (30 male; 26 female) from 35 different pedigrees. In 12 of the previously described cases of HFTC and one of the cases of HHS, we found that the cases had actually a combined phenotype of HFTC + HHS ("Phenotype revised" in Additional file 1: Table S1).

Genotype and phenotype

GALNT3 mutations were identified in 42 cases (22 men, 20 female; 75%) (Figure 3), *FGF23* mutations in 13 cases (8 male, 5 female; 23%), and a *KL* mutation was found in one female subject (2%). HFTC was the dominating phenotype in subjects with *GALNT3* mutations, whereas in subjects with *FGF23* mutation, HFTC and the combined HFTC + HHS phenotype were equally represented (Table 3). Interestingly, the isolated HHS phenotype was not found in subjects with *FGF23* mutation. Dental involvement was reported more often in subjects *GALNT3* than *FGF23* mutation (43% and 23%, respectively), whereas vascular calcification seemed more common with *FGF23* mutation than with *GALNT3* mutation (23% and 14%, respectively). Eye involvement was reported equally with both genotypes.

Sex and phenotype

Overall, males tend to have the phenotype of classic HFTC (60% of men), while females more often have manifestations of hyperostosis (HHS alone or HFTC + HHS; 56% of women) (Table 3). Vascular calcification was assessed in 18 cases, and was reported to occur more often in females than in males, whereas dental and eye involvement were reported more often in males (43% and 20% of the males and 32% and 12% of the females, respectively).

Discussion

We describe a consanguineous Caucasian family with two affected siblings carrying a novel homozygous missense mutation in exon 3 of the *GALNT3* gene. The male has classic HFTC and the female had one episode of cutaneous nodules on her scalp in infancy and episodes of HHS in childhood.

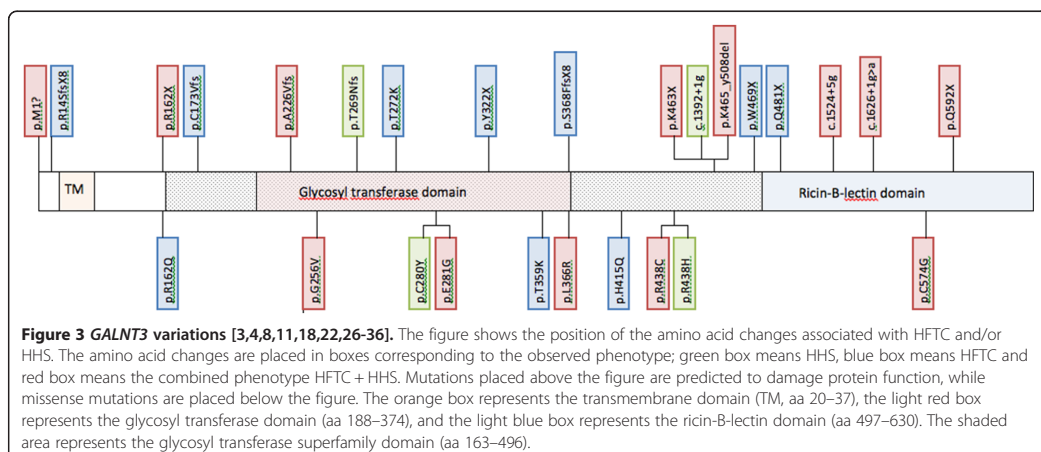


Figure 3 *GALNT3* variations [3,4,8,11,18,22,26-36]. The figure shows the position of the amino acid changes associated with HFTC and/or HHS. The amino acid changes are placed in boxes corresponding to the observed phenotype; green box means HHS, blue box means HFTC and red box means the combined phenotype HFTC + HHS. Mutations placed above the figure are predicted to damage protein function, while missense mutations are placed below the figure. The orange box represents the transmembrane domain (TM, aa 20–37), the light red box represents the glycosyl transferase domain (aa 188–374), and the light blue box represents the ricin-B-lectin domain (aa 497–630). The shaded area represents the glycosyl transferase superfamily domain (aa 163–496).

Table 3 Review of the literature [3,4,7,8,11,16-49]

Phenotype	Total N (%)	Genotype			Sex ¹	
		<i>GALNT3</i> N (%)	<i>FGF23</i> N (%)	<i>KL</i> N (%)	Male N (%)	Female N (%)
Total	56 (100)	42 (75)	13 (23)	1 (2)	30 (54)	25 (46)
Male	29 (54)	22 (52)	8 (64)	0 (0)		
Female	25 (46)	20 (48)	5 (36)	1 (100)		
HFTC	30 (54)	22 (52)	8 (62)	0	18 (60)	12 (48)
HHS	6 (11)	6 (14)	0	0	3 (10)	3 (12)
HFTC + HHS	20 (36)	14 (33)	5 (39)	1	9 (30)	10 (40)
Dental involvement	22 (39)	18 (43)	3 (23)	1	13 (43)	8 (32)
Vascular calcification	10 (18)	6 (14)	3 (23)	1	3 (10)	6 (24)
Eye involvement	9 (16)	7 (17)	2 (15)	0	6 (20)	3 (12)

¹Between-sex comparison for *GALNT3* and *FGF23* mutation only.

Tumoral calcinosis is extremely rare in infancy; only 21 cases have been described in the literature [16,50-54], and of these only three previous cases have been associated with elevated serum phosphate levels [16,55,56]. The genetic mutations of previously described cases are unknown. Subject 2 had subcutaneous tumors on her scalp at the age of three weeks, which may have been the first manifestations of HFTC in this patient, with new tumors developing on her gluteal area at six years and thigh at seven years. There are examples of asymptomatic hyperphosphatemic children, who developed HFTC some years after hyperphosphatemia was first identified [57], and in one family, a small child, with homozygous mutation in *FGF23*, was hyperphosphatemic but asymptomatic, in contrast to her older sister with HFTC [17]. Our review of the literature shows that HFTC and HHS rarely manifested before the age of two years, with 78% of cases presenting between two and 13 years of age. The symptoms displayed in subject 2 in infancy may reflect *GALNT3* associated HFTC. This condition may be under-diagnosed in small children.

In our family, the clinical picture was complex and varied significantly with age. Band keratopathy, not previously reported in *GALNT3* associated HFTC or HHS, was found in the female at age 52. Eye involvement, with irritated, itchy eyes, has been present in both siblings since early childhood, but visual acuity has not been affected. There is only one previous report of band keratopathy associated with HFTC, but in that case the mutation was not known [58]. Reported eye manifestations in HFTC and HHS also includes calcifications on the eyelids, conjunctiva and the peripheral cornea [11,18-20] as well as angioid streaks of the retina [19,21,22]. Angioid streaks represent linear breaks in areas of calcification of the Bruch's membrane separating the retina from the choroid, and may be complicated by retinal detachment are typically found in pseudoxanthoma elasticum, a disorder of ectopic calcification.

Conjunctival and corneal calcification (CCC) is a well-known manifestation of metastatic calcification in end stage renal disease (ESRD) [59]. CCC occurs when the level of calcium and phosphate in tears approach their solubility product. As tears evaporate, and the fluid is concentrated, the result is deposition of calcium-phosphate salts on the corneal surface in the exposed interpalpebral region. It is most often located in the perilimbal region, and does not affect visual acuity. However, the most severe form, band keratopathy, can lead to visual impairment. In ESRD, the severity of CCC is positively correlated to the serum level of phosphate and the serum calcium × phosphate product, but not serum calcium levels [60,61]. CCC is also positively correlated to the occurrence of vascular calcification in ESRD [61]. The mechanisms of conjunctival and corneal calcifications are probably the same in HFTC and HHS, with a high calcium × phosphate product in serum and also other body fluids, such as tears. Our female subject is the first reported case of band keratopathy in *GALNT3* associated HFTC and HHS, and this outcome is probably the result of 50 years of untreated hyperphosphatemia.

Both our subjects have had severe dental involvement. From childhood their dental roots have been reported as abnormally short and bulbous, and from about 25 years age, their teeth started falling out despite good oral hygiene and regular dental care. Typical dental findings in HFTC and HHS are short, abnormal roots and obliteration of the root canals and pulp chambers. The lesions only partly resemble dentin dysplasia type I and II [23,24], and the specific dental lesion has been suggested as a phenotypic marker of HFTC [62].

The female had pain and stiffness in her hands and feet going on for several years, along with other diffuse symptoms, suggesting a rheumatologic disease. Thorough work-up failed to find an explanation, however, and the diagnosis of HFTC/HHS was not suspected until a calcified tumor

arose in the male. This points to some important features of this disease: firstly, it is very rare, and even more so in Caucasians, and many clinicians will not be familiar with the symptoms and signs of the disease. This can lead to delayed diagnosis, as well as lack of recognition of complications of the disease. Second, in HFTC, there are often long symptom free intervals. This is most likely not associated with phosphate lowering treatment, but a feature of the disease [25].

In the first of her two pregnancies, the medical record describes pronounced placental calcifications. Placenta calcifications have not previously been reported in *GALNT3* associated HHS/HFTC. However, placental calcifications was also reported in a Caucasian female with HFTC [19] in whom genetic analysis later revealed mutation in *FGF23* [63]. Immunohistochemistry has shown a strong level of antibody staining for GalNac-T3 in the Golgi apparatus and nuclei of normal human trophoblastic cells [64], and recent reports show evidence for the expression of the FGF receptor and its cofactor α -klotho in murine placenta [65]. These observations may support the hypothesis that HFTC/HHS may be associated with placenta calcifications. However, further studies are needed to examine the prevalence of placenta calcifications and possible placenta failure in human *GALNT3* and *FGF23* associated HFTC/HHS.

The female had age-inappropriate thyroid calcifications, but no clinical or biochemical symptoms or signs of thyroid dysfunction. This same feature has been described in one previous case of HFTC due to *GALNT3* mutation [26].

Both subjects had low levels of plasma intact FGF23 and elevated levels of c-terminal FGF23. This is in concordance with previous findings in HFTC and HHS, although in our cases the results deviated less from normal than in previously reported cases (Additional file 1: Table S1). *GALNT3* encodes the enzyme GalNacT3 responsible for O-linked glycosylation FGF23, thereby preventing the break down and inactivation of the functional full-length version of the protein [9]. Defective O-glycosylation of FGF23 due to *GALNT3* mutation, as well as mutation in the *FGF23* gene itself, will destabilize the FGF23 protein and lead to increased levels of FGF23 break down products. The level of c-terminal FGF23 will be increased, whereas the level of intact FGF23 will be low or inappropriately normal given the level of hyperphosphatemia. The explanation of the relatively less abnormal results for our two subjects is not clear, but could be due to sampling procedure, sample handling and transportation, or the different kits used for the analyses, as well as large inter-individual differences in FGF23 levels [66].

HFTC and HHS, previously described as separate entities, are now recognized as different manifestations of the same rare disease [4] of increased phosphate reabsorption from the kidney proximal tubuli. Some subjects display features

of both phenotypes, whereas most have HFTC or HHS [27]. Some authors suggest a correlation between the type of mutation in the *GALNT3* gene and the phenotype [28]; most cases of homozygous missense mutations tend to have a HHS phenotype, while cases of homozygous nonsense mutations have a phenotype of HFTC. In our cases, however, the homozygous missense mutation has resulted in a HFTC phenotype in the male, and a combined HHS/HFTC phenotype in the female. Our review of all cases of HFTC and/or HHS caused by mutations in *GALNT3* showed that more cases than previously recognized had symptoms of HHS in addition to HFTC, and that HFTC seems to be the dominating phenotype in males, while more females than males have manifestations of both HFTC and HHS. Our cases confirms the notion that there may be an underestimate of the prevalence of subjects with both phenotypes, as subject 2 in our material had symptoms of HFTC in infancy, and episodes of HHS in childhood, which remained unrecognized until the present study was conducted. The explanation for the great variation in phenotype, also within the same family, is not clear, and influence from different factors regulating calcification needs further clarification.

Conclusion

We have described HFTC and HHS in a consanguineous Caucasian family with a novel *GALNT3* mutation, demonstrating new phenotypic features and significant variability in the natural course of the disease. A review of the literature shows that more subjects than previously recognized have a combined phenotype of HFTC and HHS. HHS and HFTC are two characteristic phenotypes in a spectrum of *GALNT3* mutation related calcification disorders, where the additional factors determining the phenotypic expression, are yet to be clarified.

Additional file

Additional file 1: Table S1. Review of the literature.

Abbreviations

iFGF23: Intact fibroblast growth factor 23; cFGF23: c-terminal fibroblast growth factor 23; TmP/GFR: Tubular maximum reabsorption of phosphate related to glomerular filtration rate; TRP: Tubular reabsorption of phosphate.

Competing interests

The authors declare that they have no competing interests.

Authors' contributions

SR, HR, SJ and RB designed the study; SR collected the data; whereas SR, HR, SJ and RB contributed to data analysis and interpretation. SR and RB drafted the manuscript, whereas all authors contributed to the revision and approved the final version of the manuscript.

Acknowledgements

The family members are thanked for making this study possible, by being available for clinical examination and blood tests, as well as giving access to medical information. We also thank MD Eli Brevig at Kongsvinger Hospital,

Innlandet Hospital Trust, for the initial referral of the family, and the laboratory staff at Kongsvinger Hospital, Innlandet Hospital Trust for sample handling. The staff at the Laboratory of Centre of Medical Genetics and Molecular Medicine, Haukeland University Hospital, Bergen Norway gave technical support. We thank Diane Margareth Snowden for assistance in the copy-editing process.

Author details

¹Department of Clinical Science, University of Bergen, Bergen, Norway.
²Center of Medical Genetics and Molecular Medicine, Haukeland University Hospital, Bergen, Norway. ³Department of Pediatrics, Haukeland University Hospital, Bergen, Norway.

Received: 19 February 2014 Accepted: 4 September 2014

Published online: 24 September 2014

References

- White KE, Larsson TE, Econs MJ: The roles of specific genes implicated as circulating factors involved in normal and disordered phosphate homeostasis: frizzled related protein-4, matrix extracellular phosphoglycoprotein, and fibroblast growth factor 23. *Endocr Rev* 2006, **27**:221–241.
- Chefetz I, Sprecher E: Familial tumoral calcinosis and the role of O-glycosylation in the maintenance of phosphate homeostasis. *Biochim Biophys Acta* 2009, **1792**:847–852.
- Joseph L, Hing SN, Presneau N, O'Donnell P, Diss T, Idowu BD, Joseph S, Flanagan AM, Delaney D: Familial tumoral calcinosis and hyperostosis-hyperphosphataemia syndrome are different manifestations of the same disease: novel missense mutations in GALNT3. *Skeletal Radiol* 2010, **39**:63–68.
- Frishberg Y, Topaz O, Bergman R, Behar D, Fisher D, Gordon D, Richard G, Sprecher E: Identification of a recurrent mutation in GALNT3 demonstrates that hyperostosis-hyperphosphataemia syndrome and familial tumoral calcinosis are allelic disorders. *J Mol Med (Berl)* 2005, **83**:33–38.
- Farrow EG, Imel EA, White KE: Miscellaneous non-inflammatory musculoskeletal conditions. Hyperphosphatemic familial tumoral calcinosis (FGF23, GALNT3 and alphaKlotho). *Best Pract Res Clin Rheumatol* 2011, **25**:735–747.
- Benet-Pages A, Orlik P, Strom TM, Lorenz-Depiereux B: An FGF23 missense mutation causes familial tumoral calcinosis with hyperphosphatemia. *Hum Mol Genet* 2005, **14**:385–390.
- Larsson T, Yu X, Davis SI, Draman MS, Mooney SD, Cullen MJ, White KE: A novel recessive mutation in fibroblast growth factor-23 causes familial tumoral calcinosis. *J Clin Endocrinol Metab* 2005, **90**:2424–2427.
- Topaz O, Shurman DL, Bergman R, Indelman M, Ratajczak P, Mizrahi M, Khamaysi Z, Behar D, Petronius D, Friedman V, Zelkovic I, Raimer S, Metzker A, Richard G, Sprecher E: Mutations in GALNT3, encoding a protein involved in O-linked glycosylation, cause familial tumoral calcinosis. *Nat Genet* 2004, **36**:579–581.
- Kato K, Jeanneau C, Tarp MA, Benet-Pages A, Lorenz-Depiereux B, Bennett EP, Mandel U, Strom TM, Clausen H: Polypeptide GalNAc-transferase T3 and familial tumoral calcinosis. Secretion of fibroblast growth factor 23 requires O-glycosylation. *J Biol Chem* 2006, **281**:18370–18377.
- Ichikawa S, Imel EA, Kreiter ML, Yu X, Mackenzie DS, Sorenson AH, Goetz R, Mohammadi M, White KE, Econs MJ: A homozygous missense mutation in human KLOTHO causes severe tumoral calcinosis. *J Musculoskelet Neuronal Interact* 2007, **7**:318–319.
- Spekter P, Cooper JG, Indelman M, Sprecher E: Hyperphosphatemic familial tumoral calcinosis caused by a mutation in GALNT3 in a European kindred. *J Hum Genet* 2006, **51**:487–490.
- Geeraets WJ, Guerry D 3rd: Angioid streaks and sicklecell disease. *Am J Ophthalmol* 1960, **49**:450–470.
- Walton RJ, Bijvoet OL: Nomogram for derivation of renal threshold phosphate concentration. *Lancet* 1975, **2**:309–310.
- Barth JH, Jones RG, Payne RB: Calculation of renal tubular reabsorption of phosphate: the algorithm performs better than the nomogram. *Ann Clin Biochem* 2000, **37**(Pt 1):79–81.
- Polyphen2. <http://genetics.bwh.harvard.edu/pph2>.
- Bergwitz C, Banerjee S, Abu-Zahra H, Kaji H, Miyauchi A, Sugimoto T, Juppner H: Defective O-glycosylation due to a novel homozygous S129P mutation is associated with lack of fibroblast growth factor 23 secretion and tumoral calcinosis. *J Clin Endocrinol Metab* 2009, **94**:4267–4274.
- Lammoglia JJ, Mericq V: Familial tumoral calcinosis caused by a novel FGF23 mutation: response to induction of tubular renal acidosis with acetazolamide and the non-calcium phosphate binder sevelamer. *Horm Res* 2009, **71**:178–184.
- Ichikawa S, Imel EA, Sorenson AH, Severe R, Knudson P, Harris GJ, Shaker JL, Econs MJ: Tumoral calcinosis presenting with eyelid calcifications due to novel missense mutations in the glycosyl transferase domain of the GALNT3 gene. *J Clin Endocrinol Metab* 2006, **91**:4472–4475.
- Li Voon Chong SW, Ah Kion S, Cullen MJ: A report of familial hyperphosphataemia in an Irish family. *Ir J Med Sci* 1999, **168**:262–264.
- Chefetz I, Heller R, Galli-Tsinopoulou A, Richard G, Wollnik B, Indelman M, Koerber F, Topaz O, Bergman R, Sprecher E, Schoenau E: A novel homozygous missense mutation in FGF23 causes Familial Tumoral Calcinosis associated with disseminated visceral calcification. *Hum Genet* 2005, **118**:261–266.
- McPhaul JJ Jr, Engel FL: Heterotopic calcification, hyperphosphatemia and angioid streaks of the retina. *Am J Med* 1961, **31**:488–492.
- Yancovitch A, Hershkovitz D, Indelman M, Galloway P, Whiteford M, Sprecher E, Kilic E: Novel mutations in GALNT3 causing hyperphosphatemic familial tumoral calcinosis. *J Bone Miner Metab* 2011, **29**:621–625.
- Witcher SL Jr, Drinkard DW, Shapiro RD, Schow CE Jr: Tumoral calcinosis with unusual dental radiographic findings. *Oral Surg Oral Med Oral Pathol* 1989, **68**:104–107.
- Lyles KW, Burkes EJ, Ellis GJ, Lucas KJ, Dolan EA, Drezner MK: Genetic transmission of tumoral calcinosis: autosomal dominant with variable clinical expressivity. *J Clin Endocrinol Metab* 1985, **60**:1093–1096.
- Carmichael KD, Bynum JA, Evans EB: Familial tumoral calcinosis: a forty-year follow-up on one family. *J Bone Joint Surg Am* 2009, **91**:664–671.
- Dumitrescu CE, Kelly MH, Khosravi A, Hart TC, Brahim J, White KE, Farrow EG, Nathan MH, Murphey MD, Collins MT: A case of familial tumoral calcinosis/hyperostosis-hyperphosphatemia syndrome due to a compound heterozygous mutation in GALNT3 demonstrating new phenotypic features. *Osteoporos Int* 2009, **20**:1273–1278.
- Ichikawa S, Baujat G, Seyahi A, Garoufali AG, Imel EA, Padgett LR, Austin AM, Sorenson AH, Pejiv Z, Topouchian V, Quartier P, Cormier-Daire V, Dechaux M, Malandrinou F, Singhellakis PN, Le Merrer M, Econs MJ: Clinical variability of familial tumoral calcinosis caused by novel GALNT3 mutations. *Am J Med Genet A* 2010, **152A**:896–903.
- Garringer HJ, Mortazavi SM, Esteghamat F, Malekpour M, Boztepe H, Tanakol R, Davis SI, White KE: Two novel GALNT3 mutations in familial tumoral calcinosis. *Am J Med Genet A* 2007, **143A**:2390–2396.
- Ichikawa S, Lyles KW, Econs MJ: A novel GALNT3 mutation in a pseudoautosomal dominant form of tumoral calcinosis: evidence that the disorder is autosomal recessive. *J Clin Endocrinol Metab* 2005, **90**:2420–2423.
- Campagnoli MF, Pucci A, Garelli E, Carando A, Defilippi C, Lala R, Ingresso G, Dianzani I, Forri M, Ramenghi U: Familial tumoral calcinosis and testicular microlithiasis associated with a new mutation of GALNT3 in a white family. *J Clin Pathol* 2006, **59**:440–442.
- Garringer HJ, Fisher C, Larsson TE, Davis SI, Koller DL, Cullen MJ, Draman MS, Conlon N, Jain A, Fedarko NS, Dasgupta B, White KE: The role of mutant UDP-N-acetyl-alpha-D-galactosamine-polypeptide N-acetyl-galactosaminyltransferase 3 in regulating serum intact fibroblast growth factor 23 and matrix extracellular phosphoglycoprotein in heritable tumoral calcinosis. *J Clin Endocrinol Metab* 2006, **91**:4037–4042.
- Barbieri AM, Filopanti M, Bua G, Beck-Peccoz P: Two novel nonsense mutations in GALNT3 gene are responsible for familial tumoral calcinosis. *J Hum Genet* 2007, **52**:464–468.
- Ichikawa S, Guignon V, Imel EA, Courouble M, Heissat S, Henley JD, Sorenson AH, Petit B, Lienhardt A, Econs MJ: Novel GALNT3 mutations causing hyperostosis-hyperphosphatemia syndrome result in low intact fibroblast growth factor 23 concentrations. *J Clin Endocrinol Metab* 2007, **92**:1943–1947.
- Lalaye A, Alao MJ, Gbessi G, Adjagba M, Marche M, Coupry I, Redonnet-Vernhet I, Lepreux S, Ayivi B, Darboux RB, Lacombe D, Arveiler B: Tumoral calcinosis due to GALNT3 C.516-2A > T mutation in a black African family. *Genet Couns* 2008, **19**:183–192.
- Olauson H, Krajsnik T, Larsson C, Lindberg B, Larsson TE: A novel missense mutation in GALNT3 causing hyperostosis-hyperphosphataemia syndrome. *Eur J Endocrinol* 2008, **158**:929–934.

36. Gok F, Chefetz I, Indelman M, Kocaoglu M, Sprecher E: **Newly discovered mutations in the GALNT3 gene causing autosomal recessive hyperostosis-hyperphosphatemia syndrome.** *Acta Orthop* 2009, **80**:131–134.
37. Araya K, Fukumoto S, Backenroth R, Takeuchi Y, Nakayama K, Ito N, Yoshii N, Yamazaki Y, Yamashita T, Silver J, Igarashi T, Fujita T: **A novel mutation in fibroblast growth factor 23 gene as a cause of tumoral calcinosis.** *J Clin Endocrinol Metab* 2005, **90**:5523–5527.
38. Garringer HJ, Malekpour M, Esteghamat F, Mortazavi SM, Davis SI, Farrow EG, Yu X, Arking DE, Dietz HC, White KE: **Molecular genetic and biochemical analyses of FGF23 mutations in familial tumoral calcinosis.** *Am J Physiol Endocrinol Metab* 2008, **295**:E929–937.
39. Masi L, Gozzini A, Franchi A, Campanacci D, Amedei A, Falchetti A, Franceschelli F, Marcucci G, Tanini A, Capanna R, Brandi ML: **A novel recessive mutation of fibroblast growth factor-23 in tumoral calcinosis.** *J Bone Joint Surg Am* 2009, **91**:1190–1198.
40. Steinherz R, Chesney RW, Eisenstein B, Metzker A, DeLuca HF, Phelps M: **Elevated serum calcitriol concentrations do not fall in response to hyperphosphatemia in familial tumoral calcinosis.** *Am J Dis Child* 1985, **139**:816–819.
41. Metzker A, Eisenstein B, Oren J, Samuel R: **Tumoral calcinosis revisited—common and uncommon features. Report of ten cases and review.** *Eur J Pediatr* 1988, **147**:128–132.
42. Baldursson H, Evans EB, Dodge WF, Jackson WT: **Tumoral calcinosis with hyperphosphatemia. A report of a family with incidence in four siblings.** *J Bone Joint Surg Am* 1969, **51**:913–925.
43. Frisberg Y, Ito N, Rinat C, Yamazaki Y, Feinstein S, Urakawa I, Navon-Elkan P, Becker-Cohen R, Yamashita T, Araya K, Igarashi T, Fujita T, Fukumoto S: **Hyperostosis-hyperphosphatemia syndrome: a congenital disorder of O-glycosylation associated with augmented processing of fibroblast growth factor 23.** *J Bone Miner Res* 2007, **22**:235–242.
44. Yamaguchi T, Sugimoto T, Imai Y, Fukase M, Fujita T, Chihara K: **Successful treatment of hyperphosphatemic tumoral calcinosis with long-term acetazolamide.** *Bone* 1995, **16**:2475–2505.
45. Clarke E, Swischuk LE, Hayden CK Jr: **Tumoral calcinosis, diaphysitis, and hyperphosphatemia.** *Radiology* 1984, **151**:643–646.
46. Slavin RE, Wen J, Kumar D, Evans EB: **Familial tumoral calcinosis. A clinical, histopathologic, and ultrastructural study with an analysis of its calcifying process and pathogenesis.** *Am J Surg Pathol* 1993, **17**:788–802.
47. Ichikawa S, Imel EA, Kreiter ML, Yu X, Mackenzie DS, Sorenson AH, Goetz R, Mohammadi M, White KE, Econs MJ: **A homozygous missense mutation in human KLOTHO causes severe tumoral calcinosis.** *J Clin Invest* 2007, **117**:2684–2691.
48. Martinez S, Vogler JB 3rd, Harrelson JM, Lyles KW: **Imaging of tumoral calcinosis: new observations.** *Radiology* 1990, **174**:215–222.
49. Viegas SF, Evans EB, Calhoun J, Goodwiller SE: **Tumoral calcinosis: a case report and review of the literature.** *J Hand Surg Am* 1985, **10**:744–748.
50. Hammoud S, McCarthy EF, Weber K: **Tumoral calcinosis in infants: a report of three cases and review of the literature.** *Clin Orthop Relat Res* 2005, **436**:261–264.
51. Polykandriotis EP, Beutel FK, Horch RE, Grunert J: **A case of familial tumoral calcinosis in a neonate and review of the literature.** *Arch Orthop Trauma Surg* 2004, **124**:563–567.
52. Slavin RE, Wen J, Barmada A: **Tumoral calcinosis—a pathogenetic overview: a histological and ultrastructural study with a report of two new cases, one in infancy.** *Int J Surg Pathol* 2012, **20**:462–473.
53. Kadlec J, Hucin B, Tlaskal T, Westaby S: **Aggressive tumoral calcinosis in an infant thoracotomy scar.** *Interact Cardiovasc Thorac Surg* 2010, **11**:864–865.
54. Okada T, Hara H, Shimojima H, Suzuki H: **Spontaneous regression of multiple tumoral calcinosis in a child.** *Eur J Dermatol* 2004, **14**:424–425.
55. Niall DM, Fogarty EE, Dowling FE, Moore DP: **Spontaneous regression of tumoral calcinosis in an infant: a case report.** *J Pediatr Surg* 1998, **33**:1429–1431.
56. Rodriguez-Peralto JL, Lopez-Barea F, Torres A, Rodriguez-Gonzalez JL, Diaz-Faes J: **Tumoral calcinosis in two infants.** *Clin Orthop Relat Res* 1989, **242**:272–276.
57. McGuinness FE: **Hyperphosphatemic tumoral calcinosis in Bedouin Arabs—clinical and radiological features.** *Clin Radiol* 1995, **50**:259–264.
58. Bruns DE, Lieb W, Conway BP, Savory J, Willis MR, Boskey AL: **Band keratopathy and calcific lid lesions in tumoral calcinosis. Case reports.** *Arch Ophthalmol* 1988, **106**:725–726.
59. Berlyne GM: **Microcrystalline conjunctival calcification in renal failure. A useful clinical sign.** *Lancet* 1968, **2**:366–370.
60. Tokuyama T, Ikeda T, Sato K, Mimura O, Morita A, Tabata T: **Conjunctival and corneal calcification and bone metabolism in hemodialysis patients.** *Am J Kidney Dis* 2002, **39**:291–296.
61. Seyahi N, Altiparmak MR, Kahveci A, Yetik H, Kanberoglu K, Serdengecti K, Ataman R, Ereik E: **Association of conjunctival and corneal calcification with vascular calcification in dialysis patients.** *Am J Kidney Dis* 2005, **45**:550–556.
62. Burkes EJ Jr, Lyles KW, Dolan EA, Giammara B, Hunker J: **Dental lesions in tumoral calcinosis.** *J Oral Pathol Med* 1991, **20**:222–227.
63. McGrath E, Harney F, Kinsella F: **An ocular presentation of familial tumoral calcinosis.** *BMJ Case Rep* 2010, **2010**. doi: 10.1136/bcr.05.2010.3044.
64. **The Human Protein Atlas.** <http://www.proteinatlas.org>.
65. Ohata Y, Yamazaki M, Kawai M, Tsugawa N, Tachikawa K, Koinuma T, Miyagawa K, Kimoto A, Nakayama M, Namba N, Yamamoto H, Okano T, Ozono K, Michigami T: **Elevated Fibroblast Growth Factor 23 Exerts Its Effects on Placenta and Regulates Vitamin D Metabolism in Pregnancy of Hyp Pice.** *J Bone Miner Res* 2014, **10**:1002/jbmr.2186.
66. Smith ER, McMahon LP, Holt SG: **Method-specific differences in plasma fibroblast growth factor 23 measurement using four commercial ELISAs.** *Clin Chem Lab Med* 2013, **51**:1971–1981.

doi:10.1186/s12863-014-0098-3

Cite this article as: Rafaelsen *et al.*: Long-term clinical outcome and phenotypic variability in hyperphosphatemic familial tumoral calcinosis and hyperphosphatemic hyperostosis syndrome caused by a novel GALNT3 mutation; case report and review of the literature. *BMC Genetics* 2014 **15**:98.

Submit your next manuscript to BioMed Central and take full advantage of:

- Convenient online submission
- Thorough peer review
- No space constraints or color figure charges
- Immediate publication on acceptance
- Inclusion in PubMed, CAS, Scopus and Google Scholar
- Research which is freely available for redistribution

Submit your manuscript at
www.biomedcentral.com/submit



Supplementary Table

Author Year	Family #	Gene	Genetic mutation	Ref #	Sex	Ethnicity	Phenotype originally	Phenotype revised	Age onset	Hyperphosphatemia	Dephysical/hyperostosis	Calcific tumours	Dental affection	Eye affection	Vascular calcification	FGF23 ng/ml ref:0.52-1.65	dFGF23 ng/ml ref:0.58-1.65	s-P mmol/L	
Togiani et al. 2004	1	GALNT3	c.1524+1G6A, p.S665_Y668del	1	M	Arab	HFTC + HHS	HFTC + HHS	4	yes	yes	yes	MA	MA	MA	NA	NA	high	
	1				M	Arab	HFTC + HHS	HFTC + HHS	4	yes	yes	no	MA	MA	MA	MA	MA	NA	high
	1				M	Arab	HFTC	HFTC	NA	yes	yes	no	MA	MA	MA	MA	MA	MA	NA
Stehrer et al. 1985	1	GALNT3	c.1524+1G6A, p.S665_Y668del	1	M	Arab	HFTC	HFTC	NA	yes	yes	no	MA	MA	MA	MA	MA	high	
	1				F	Arab	HFTC	HFTC	7	yes	yes	no	MA	MA	MA	MA	MA	MA	high
Mukherjee et al. 1988	1	GALNT3	c.1524+1G6A, p.S665_Y668del	1	F	Arab	HFTC	HFTC	NA	yes	yes	no	MA	MA	MA	MA	MA	high	
	1				F	Arab	HFTC	HFTC	NA	yes	yes	no	MA	MA	MA	MA	MA	MA	high
Togiani et al. 2004	2	GALNT3	c.1524+1G6A, p.S665_Y668del	2	M	Alto-american	HFTC	HFTC	4	yes	yes	no	MA	MA	MA	MA	MA	high	
	2				F	Alto-american	HFTC + HHS	HFTC + HHS	5	yes	yes	yes	MA	MA	MA	MA	MA	NA	high
Balderson 1999	2	GALNT3	c.480T>C, p.R163X	1	M	Alto-american	HFTC	HFTC	3	yes	yes	no	MA	MA	MA	MA	MA	high	
	2				M	Alto-american	HFTC	HFTC	4	yes	yes	no	MA	MA	MA	MA	MA	MA	high
Sabin et al. 1993	2	GALNT3	c.1524+1G6A, p.S665_Y668del	2	M	Alto-american	HFTC	HFTC	3	yes	yes	no	MA	MA	MA	MA	MA	high	
	2				F	Alto-american	HFTC	HFTC	3	yes	yes	no	MA	MA	MA	MA	MA	MA	high
Guthrie et al. 1984	2	GALNT3	c.1524+1G6A, p.S665_Y668del	2	M	Alto-american	HFTC + HHS	HFTC + HHS	2	yes	yes	no	MA	MA	MA	MA	MA	high	
	2				F	Alto-american	HFTC	HFTC	2	yes	yes	no	MA	MA	MA	MA	MA	MA	high
Vogler et al. 1985	2	GALNT3	c.1524+1G6A, p.S665_Y668del	2	M	Alto-american	HFTC	HFTC	2	yes	yes	no	MA	MA	MA	MA	MA	high	
	2				F	Alto-american	HFTC	HFTC	2	yes	yes	no	MA	MA	MA	MA	MA	MA	high
Wagner et al. 1989	2	GALNT3	c.1524+1G6A, p.S665_Y668del	2	M	Arab	HHS	HHS	9	yes	yes	no	MA	MA	MA	MA	MA	high	
	2				F	Arab	HHS	HHS	2	yes	yes	no	MA	MA	MA	MA	MA	MA	high
Fridberg et al. 2005	3	GALNT3	c.1524+1G6A, p.S665_Y668del	3	M	Alto-american	HFTC	HFTC	13	yes	yes	no	MA	MA	MA	MA	MA	2.32	
	3				F	Alto-american	HFTC	HFTC	12	yes	yes	no	MA	MA	MA	MA	MA	MA	2.32
Eshwary et al. 2005	4	GALNT3	c.516>2A6T, p.C173Y>Y64	3	M	Alto-american	HFTC	HFTC	12	yes	yes	no	MA	MA	MA	MA	MA	2.38	
	4				F	Alto-american	HFTC	HFTC	12	yes	yes	no	MA	MA	MA	MA	MA	MA	2.38
Yes et al. 1985, Rodriguez et al. 1990	5	GALNT3	c.516>2A6T, p.C173Y>Y64	5	M	Alto-american	HFTC	HFTC	8	yes	yes	no	MA	MA	MA	MA	MA	2.38	
	5				F	Alto-american	HFTC	HFTC	8	yes	yes	no	MA	MA	MA	MA	MA	MA	2.38
Machuga et al. 2006	6	GALNT3	c.1524+1G6A, p.S665_Y668del	6	M	Alto-american	HFTC	HFTC	8	yes	yes	no	MA	MA	MA	MA	MA	high	
	6				F	Alto-american	HFTC	HFTC	8	yes	yes	no	MA	MA	MA	MA	MA	MA	high
Cheng et al. 2006	6	GALNT3	c.1524+1G6A, p.S665_Y668del	6	M	Alto-american	HFTC	HFTC	6	yes	yes	no	MA	MA	MA	MA	MA	high	
	6				F	Alto-american	HFTC	HFTC	6	yes	yes	no	MA	MA	MA	MA	MA	MA	high
Singer et al. 2006	7	GALNT3	c.1720G>T, L1029X	5	M	Alto-american	HFTC	HFTC	<9	yes	yes	no	MA	MA	MA	MA	MA	15.2, 18	
	7				F	Alto-american	HFTC	HFTC	<9	yes	yes	no	MA	MA	MA	MA	MA	MA	15.2, 18
Garringer et al. 2006	8	GALNT3	c.4232G>A, p.R1428H	7	F	Alto-american	HFTC	HFTC	26	yes	yes	no	MA	MA	MA	MA	MA	1222	
	8				F	Alto-american	HFTC	HFTC	22	yes	yes	no	MA	MA	MA	MA	MA	MA	1222
Lubawa et al. 2006	9	GALNT3	c.1524+1G6A, p.S665_Y668del	7	M	Alto-american	HFTC	HFTC	22	yes	yes	no	MA	MA	MA	MA	MA	<1.1	
	9				F	Alto-american	HFTC	HFTC	22	yes	yes	no	MA	MA	MA	MA	MA	MA	<1.1
Lubawa et al. 2007	10	GALNT3	c.480T>C, p.R163X	8	M	Alto-american	HFTC	HFTC	5	yes	yes	no	MA	MA	MA	MA	MA	1139	
	10				F	Alto-american	HFTC	HFTC	5	yes	yes	no	MA	MA	MA	MA	MA	MA	1139
Garringer et al. 2007	11	GALNT3	c.1102>1103del, c.538G>A>G	9	M	Iranian	HFTC	HFTC	17	yes	yes	no	MA	MA	MA	MA	MA	242.2	
	11				F	Iranian	HFTC	HFTC	17	yes	yes	no	MA	MA	MA	MA	MA	MA	242.2
Babiker et al. 2007	12	GALNT3	c.1360G>A, p.W423X	9	M	Turkish	HFTC	HFTC	45	yes	yes	no	MA	MA	MA	MA	MA	777	
	12				F	Turkish	HFTC	HFTC	45	yes	yes	no	MA	MA	MA	MA	MA	MA	777
Lubawa et al. 2008	13	GALNT3	c.516>2A6T, p.C173Y>Y64	10	M	Alto-american	HFTC	HFTC	<10	yes	yes	no	MA	MA	MA	MA	MA	746	
	13				F	Alto-american	HFTC	HFTC	<10	yes	yes	no	MA	MA	MA	MA	MA	MA	746
Lubawa et al. 2008	14	GALNT3	c.516>2A6T, p.C173Y>Y64	11	M	African	HFTC	HFTC	2	yes	yes	no	MA	MA	MA	MA	MA	2.81	
	14				F	African	HFTC	HFTC	2	yes	yes	no	MA	MA	MA	MA	MA	MA	2.81
Ghaouar et al. 2008	15	GALNT3	c.1318G>A, p.R451H	12	F	Colombian	HHS	HHS	5	yes	yes	no	MA	MA	MA	MA	MA	839	
	15				F	Colombian	HHS	HHS	5	yes	yes	no	MA	MA	MA	MA	MA	MA	839
Gok et al. 2009	16	GALNT3	c.273A>G, p.M91	13	F	Turkish	HHS	HHS	8	yes	yes	no	MA	MA	MA	MA	MA	2.97	
	16				F	Turkish	HHS	HHS	8	yes	yes	no	MA	MA	MA	MA	MA	MA	2.97
Dumitrescu et al. 2009	17	GALNT3	c.1312C>T, p.R443C	14	F	Romanian	HHS + HFTC	HHS + HFTC	12	yes	yes	no	MA	MA	MA	MA	MA	7.4	
	17				F	Romanian	HHS + HFTC	HHS + HFTC	12	yes	yes	no	MA	MA	MA	MA	MA	MA	7.4
Joshi et al. 2009	18	GALNT3	c.2870G>A, p.R958H	15	F	Tamil	HHS	HHS	13	yes	yes	no	MA	MA	MA	MA	MA	2.36	
	18				F	Tamil	HHS	HHS	13	yes	yes	no	MA	MA	MA	MA	MA	MA	2.36
Hilawa et al. 2010	19	GALNT3	c.485G>A, p.R162Z	16	F	Turkish	HFTC	HFTC	13	yes	yes	no	MA	MA	MA	MA	MA	high	
	19				F	Turkish	HFTC	HFTC	13	yes	yes	no	MA	MA	MA	MA	MA	MA	high
Hilawa et al. 2010	20	GALNT3	c.673G>C, p.R226V>V63	16	M	Libanese	HHS + HFTC	HHS + HFTC	5	yes	yes	no	MA	MA	MA	MA	MA	2.33	
	20				F	Libanese	HHS + HFTC	HHS + HFTC	5	yes	yes	no	MA	MA	MA	MA	MA	MA	2.33
Yanovich et al. 2011	21	GALNT3	c.1321G>A, p.H451Q	17	M	Turkish	HHS + HFTC	HHS + HFTC	8	yes	yes	no	MA	MA	MA	MA	MA	2.5	
	21				F	Turkish	HHS + HFTC	HHS + HFTC	8	yes	yes	no	MA	MA	MA	MA	MA	MA	2.5
Yanovich et al. 2011	22	GALNT3	c.1321G>A, p.H451Q	17	M	Turkish	HHS + HFTC	HHS + HFTC	13	yes	yes	no	MA	MA	MA	MA	MA	10.66	
	22				F	Turkish	HHS + HFTC	HHS + HFTC	13	yes	yes	no	MA	MA	MA	MA	MA	MA	10.66
Preident Study	23	GALNT3	c.1321G>A, p.H451Q	17	M	Pakistani	HFTC	HFTC	9	yes	yes	no	MA	MA	MA	MA	MA	1.58, 1.81	
	23				F	Pakistani	HFTC	HFTC	9	yes	yes	no	MA	MA	MA	MA	MA	MA	1.58, 1.81
Preident Study	24	GALNT3	c.1321G>A, p.H451Q	17	M	Pakistani	HFTC	HFTC	14	yes	yes	no	MA	MA	MA	MA	MA	2.26	
	24				F	Pakistani	HFTC	HFTC	14	yes	yes	no	MA	MA	MA	MA	MA	MA	2.26
Benedict-Foght et al. 2005	25	GALNT3	c.730G>T, p.G250V	25	M	Quebecian	HFTC	HFTC	0	yes	yes	no	MA	MA	MA	MA	MA	12	
	25				F	Quebecian	HFTC	HFTC	0	yes	yes	no	MA	MA	MA	MA	MA	MA	12
Lubawa et al. 2005	26	GALNT3	c.2130G>C, p.S716I	18	M	Quebecian	HHS + HFTC	HHS + HFTC	12	yes	yes	no	MA	MA	MA	MA	MA	207	
	26				F	Quebecian	HHS + HFTC	HHS + HFTC	12	yes	yes	no	MA	MA	MA	MA	MA	MA	207
Lubawa et al. 2005	27	GALNT3	c.2130G>C, p.S716I	19	F	Quebecian	HFTC	HFTC	30	yes	yes	no	MA	MA	MA	MA	MA	<5	
	27				F	Quebecian	HFTC	HFTC	30	yes	yes	no	MA	MA	MA	MA	MA	MA	<5
Lubawa et al. 2005	28	GALNT3	c.2130G>C, p.S716I	19	M	Quebecian	HFTC	HFTC	42	yes	yes	no	MA	MA	MA	MA	MA	3100	
	28				F	Quebecian	HFTC	HFTC	42	yes	yes	no	MA	MA	MA	MA	MA	MA	3100
Zhang et al. 2005	29	GALNT3	c.2807C>G, p.S591F	20	M	Arabian	HFTC	HFTC	NA	yes	yes	no	MA	MA	MA	MA	MA	11, 40, 51	
	29				F	Arabian	HFTC	HFTC	NA	yes	yes	no	MA	MA	MA	MA	MA	MA	11, 40, 51
Garringer et al. 2005	30	GALNT3	c.2807C>G, p.S591F	20	M	Arabian	HFTC	HFTC	NA	yes	yes	no	MA	MA	MA	MA	MA	2984, 6, 675	
	30				F	Arabian	HFTC	HFTC	NA	yes	yes	no	MA	MA	MA	MA	MA	MA	2984, 6, 675
Garringer et al. 2005	31	GALNT3	c.2807C>G, p.S591F	20	M	Arabian	HFTC	HFTC	NA	yes	yes	no	MA	MA	MA	MA	MA	1, 62, 3	
	31				F	Arabian	HFTC	HFTC	NA	yes	yes	no	MA	MA	MA	MA	MA	MA	1, 62, 3
Bergantini et al. 2005	32	GALNT3	c.180C>A, p.G64K	22	M	Iranian	HFTC	HFTC	20	yes	yes	no	MA	MA	MA	MA	MA	>18000	
	32				F	Iranian	HFTC	HFTC	20	yes	yes	no	MA	MA	MA	MA	MA	MA	>18000
Bergantini et al. 2005	33	GALNT3	c.3817C>T, p.S1339P	23	M	Iranian	HFTC	HFTC	5	yes	yes	no	MA	MA	MA	MA	MA	22	
	33				F	Iranian	HFTC	HFTC	5	yes	yes	no	MA	MA	MA	MA	MA	MA	22
Lubawa et al. 2009	34	GALNT3	c.3817C>T, p.S1339P	23	M	Iranian	HFTC	HFTC	<1	yes	yes	no	MA	MA	MA	MA	MA	10, 28	
	34				F	Iranian	HFTC	HFTC	<1	yes	yes	no	MA	MA	MA	MA	MA	MA	10, 28
Lubawa et al. 2009	35	GALNT3	c.3817C>T, p.S1339P	24	M	Iranian	HFTC	HFTC	2	yes	yes	no	MA	MA	MA	MA	MA	152, 8	
	35				F	Iranian	HFTC	HFTC	2	yes	yes	no	MA	MA	MA	MA	MA	MA	152, 8
Mayer et al. 2009	36	G																	

11 Topaz O, Shuman DL, Bergman R, Rialzak P, Mizrahi M, Khamayel Z, Behar D, Petronius D, Friedman V, Zelikov L, Benzer S, Metzker A, Richard G, Sprecher E. Mutations in GALNT3, encoding a protein involved in O-linked glycosylation, cause familial tumoral calcinosis. *Nat Genet* (2004), 36:579-581.

12 Fritshava Y, Topaz O, Bergman R, Behar D, Fisher D, Gordon D, Richard G, Sprecher E. Identification of a recurrent mutation in GALNT3 demonstrates that hyperostosis-hypophosphatasia syndrome and familial tumoral calcinosis are allelic disorders. *J Mol Med (Berl)* (2005), 83:33-38.

13 Fritshava S, Usher VA, Econs M. A novel GALNT3 mutation in a pseudodominant dominant form of tumoral calcinosis: evidence that the disorder is autosomal recessive. *J Clin Endocrinol Metab* (2005), 90:2420-2423.

14 Sprecher E, Cooper G, Indelman M, Sprecher E. Hypophosphatemic familial tumoral calcinosis: caused by a mutation in GALNT3 in a European kindred. *J Hum Genet* (2006), 55:487-490.

15 Gangerer H, Fisher C, Larsson TE, Davis SJ, Keller DL, Collin M, Demian MS, Conlon N, Amin A, Feldman NS, Desguera B, White KE. The role of mutant UDP-N-acetylglucosaminyltransferase 3 in regulating serum intact fibroblast growth factor 23 and matrix extracellular phosphoglycoprotein in heritable tumoral calcinosis. *J Clin Endocrinol Metab* (2006), 91:4037-4042.

17 Fritshava S, Inel EA, Sorenson AH, Sewer K, Knudson P, Harris GJ, Shaker JL, Econs M. Tumoral calcinosis presenting with eyelid calcifications due to novel missense mutations in the *hPGCyl* transferase domain of the GALNT3 gene. *J Clin Endocrinol Metab* (2006), 91:4472-4475.

18 Fritshava S, Gagnon V, Inel EA, Carrozzini M, Knudson P, Harris G, Henley D, Sprecher E, Econs M. Novel GALNT3 mutations causing hyperostosis-hypophosphatasia syndrome: result in novel mild fibroblast growth factor 23 concentrations. *J Clin Endocrinol Metab* (2007), 92:1943-1947.

19 Gangerer H, Fisher C, Larsson TE, Davis SJ, Keller DL, Collin M, Demian MS, Conlon N, Amin A, Feldman NS, Desguera B, White KE. The role of mutant UDP-N-acetylglucosaminyltransferase 3 in regulating serum intact fibroblast growth factor 23 and matrix extracellular phosphoglycoprotein in heritable tumoral calcinosis. *J Clin Endocrinol Metab* (2007), 92:1943-1947.

20 Fritshava S, Gagnon V, Inel EA, Carrozzini M, Knudson P, Harris G, Henley D, Sprecher E, Econs M. Novel GALNT3 mutations causing hyperostosis-hypophosphatasia syndrome: result in novel mild fibroblast growth factor 23 concentrations. *J Clin Endocrinol Metab* (2007), 92:1943-1947.

21 Lahlawi A, Aïme M, Ghiesb G, Adigba M, Metzker A, Coumy L, Redonnet-Muller L, Lepoux S, Auvil B, Durieux RB, Lecomte D, Avelier B. Tumoral calcinosis due to GALNT3 C.516-2A>T mutation in a Black African family. *Genet Couns* (2008), 19:188-192.

11 Lahlawi A, Kojouhar T, Larsson TE, Lindberg B, Larsson TE. A novel missense mutation in GALNT3 causing hyperostosis-hypophosphatasia syndrome. *Eur J Endocrinol* (2008), 158:929-934.

12 Gokh C, Chedret I, Indelman M, Gagnon V, Sprecher E. Newly discovered mutations in the GALNT3 gene causing autosomal recessive hyperostosis-hypophosphatasia syndrome. *Acta Orthop* (2009), 80:133-134.

13 Gokh C, Chedret I, Indelman M, Gagnon V, Sprecher E. A case of familial tumoral calcinosis/hyperostosis-hypophosphatasia syndrome due to a compound heterozygous mutation in GALNT3 demonstrating new phenotypic features. *Osteoporos Int* (2009), 20:1273-1278.

15 Joseph L, Hing SH, Prensner N, O'Donnell P, Das T, Howell RD, Joseph S, Flanagan AM, Delany D. Familial tumoral calcinosis and hyperostosis-hypophosphatasia syndrome are different manifestations of the same disease: novel missense mutations in GALNT3. *Skeletal Radiol* (2010), 39:63-68.

16 Ichikawa S, Bayraktar G, Seyahi N, Genovelli AG, Inel EA, Pedgett LB, Austin AM, Sorenson AH, Pejin Z, Popovitch V, Quarter P, Cormier-Daire V, Singhalki PV, Le Merrer M, Econs M. Clinical variability of familial tumoral calcinosis caused by novel GALNT3 mutations. *Am J Med Genet A* (2010), 152A:938-903.

17 Hoshikawa D, Indelman M, Gagnon V, Whitfield M, Sprecher E. Effect of novel mutations in GALNT3 causing hypophosphatemic familial tumoral calcinosis. *Bone Miner Metab* (2011), 29:621-625.

18 Benoit Rague A, Orlie P, Strom TM, Jorns-Dempere B. An FGFR3 missense mutation causes familial tumoral calcinosis with hypophosphatasia. *Hum Mol Genet* (2005), 14:385-390.

19 Larson T, Yu X, Davis SJ, Demian MS, Moorey SO, Collin M, White KE. A novel recessive mutation in fibroblast growth factor 23 causes familial tumoral calcinosis. *J Clin Endocrinol Metab* (2005), 90:2424-2427.

20 Araya K, Fukunishi S, Beckenroth B, Thekdi V, Nakayama K, Ito N, Yoshii N, Yamashita Y, Yamashita T, Shiro T, Fujita T. A novel mutation in fibroblast growth factor 23 gene as a cause of tumoral calcinosis. *J Clin Endocrinol Metab* (2005), 90:5523-5527.

21 Gierthy I, Heiler R, Gallif-Tringolova A, Richard G, Wolke B, Indelman M, Koster F, Topaz O, Bergman R, Sprecher E, Schoenau E. A novel homozygous missense mutation in FGFR3 causes Familial Tumoral Calcinosi associated with disseminated skeletal calcification. *Hum Genet* (2005), 118:763-766.

22 Gierthy I, Heiler R, Mabeqou M, Esqigamer C, Morozan SK, Davis SJ, Farow EG, Yu X, Kading DC, Dele R, White KE. Molecular genetic and biochemical analysis of FGFR3 mutations in familial tumoral calcinosis. *Am J Physiol Endocrinol Metab* (2008), 295:929-937.

23 Gierthy I, Heiler R, Mabeqou M, Esqigamer C, Morozan SK, Davis SJ, Farow EG, Yu X, Kading DC, Dele R, White KE. Molecular genetic and biochemical analysis of FGFR3 mutations in familial tumoral calcinosis. *Am J Physiol Endocrinol Metab* (2008), 295:929-937.

24 Lammiel JJ, Mercier V. Familial tumoral calcinosis caused by a novel FGFR3 mutation: response to induction of fibroblast growth factor 23 with acetazolamide and the non-calcium phosphate binder sevelamer. *Horm Res* (2009), 71:178-184.

25 Masai L, Gazzali A, Franzini A, Campanacci D, Amendola A, Fracchetti F, Marzucchi G, Tanzi A, Capanna R, Brandi ML. A novel recessive mutation of fibroblast growth factor-23 in tumoral calcinosis. *J Bone Joint Surg Am* (2009), 91:1190-1198.

26 Ichikawa S, Inel EA, Kreier ML, Yu X, Makretschke DS, Sorenson AH, Geitz R, Mohammedi M, White KE, Econs M. A homozygous missense mutation in human Klotho causes severe tumoral calcinosis. *J Clin Invest* (2007), 117:2684-2691.

Table S1 shows all cases of HFTC and HTS in which the mutation has been identified.

Mutation is listed in two columns for combined heterozygous subjects.

Phenotype originally* in some papers, the described subjects had phenotypic features of both HFTC and HTS, whereas they were described as having either HFTC or HTS.

*Phenotype revised: after review of the original papers, subjects with signs of both phenotypes, are recoded as HFTC/HTS.


The reference ranges given for FGFR3, FGFR3 and FGFR3 are valid for the laboratory used in the present study.


**Errata for
Hereditary phosphate balance disorders in
Norwegian children**

Silje Hjorth Rafaelsen



Thesis for the degree philosophiae doctor (PhD)
at the University of Bergen


(signature of candidate)


(signature of faculty)

12.04.16

Errata

- Page 23 Figure legend Figure 3. Original text: "... (Based on figure from The Royal Children's Hospital Melbourne; <http://www.rch.org.au/fracture-education/remodelling/>)" – Corrected text: "Reproduced with permission, and slightly modified from (*The Royal Children's Hospital, Melbourne, Australia, Clinical Practice Guideline on Paediatric Fracture Education Module, Remodelling, [Cited 12.01.16], Available from: <http://www.rch.org.au/clinicalguide/index.cfm>*).
- Page 24 Figure legend, Figure 4. Original text: "Illustration adapted from <http://www.uptodate.com>." – Corrected text: Reproduced with permission, and slightly modified from (Mathison, DJ and Agrawal, D. General principles of fracture management: Fracture patterns and description in children. In: UpToDate, Bachur RD (Ed), UpToDate, Waltham, MA. (Accessed on January 6, 2016.)

