

ARTICLE IV

Enzyme histochemical studies of acid phosphatase
isoenzymes in induced heterotopic bone formation
in guinea pigs

R. NILSEN ^x AND B. C. MAGNUSSON ^{xx}

^x Department of Oral Pathology and
Forensic Odontology, School of
Dentistry, University of Bergen,
Norway

^{xx} Department of Oral Pathology,
School of Dentistry,
University of Göteborg,
Sweden.

Abstract - A bone induction model was used to study the effect of different pretreatments and inhibitors added to the substrate of acid phosphatase. Two different acid phosphatases (AcP) were demonstrated. The AcP of matrix-producing cells exhibited resistance to pretreatment with EDTA while it was sensitive to tartrate added to the incubation medium.

The AcP in dentin resorbing cells was EDTA sensitive but resistant to tartrate. Both resorbing and matrix-producing cells were generally sensitive to fluoride, copper and molybdate. In some of the dentinoclasts, fluoride resistant AcP was observed.

The results support previous investigations on normal bone formation suggesting that two different isoenzymes of AcP exist. One of these seems to be related to matrix production and mineralization of the new heterotopic bone.

Key words: acid phosphatase, bone, osteoclasts, osteoblasts.

Rune Nilsen, Department of Oral Pathology and Forensic Odontology, 5016-Haukeland Hospital, Norway.

Introduction

Several investigators have shown biochemically (17), histochemically (8,11) and chromatographically (1) that at least two acid phosphatases (AcP) having different substrate specificity and different inhibitor sensitivity are found in normal bone as well as in other hard tissues. Most of these investigations have been done on rats and mice although a few used monkey and man (9, 13). Fluoride resistant acid phosphatase is found in osteoclasts while a fluoride sensitive acid phosphatase is demonstrated in osteoblasts (8). Enzyme activity in formative cells is also totally inhibited by formaldehyde treatment of tissue sections prior to incubation for AcP (10). AcP activity in formative cells in rats is shown to be suppressed by tartrate when these ions are added to the incubation media (8). Osteoblasts in man and monkey, however, are shown to be more resistant to tartrate (9).

Implantation of freeze-dried allogenic dentin in abdominal muscles in guinea pigs has been shown to give a high yield of osteoid and bone, as well as chondroid and cartilage, due to an inductive mechanism (2, 3, 14). An enzyme histochemical study using light microscopy has demonstrated the advantages of this model in studying hard tissue formation as well as matrix resorption, and permits investigation of undemineralized tissue and intrasectional analysis of the different reaction

zones (15). This study has shown strong AcP activity in matrix-producing cells as well as in resorbing cells.

The aim of the present study was to differentiate between possible isoenzymes of AcP in heterotopic bone formation in guinea pigs by means of pretreatments and inhibitors added to the incubation media.

Material and Methods

Eighteen randomly bred young male guinea pigs were used. They were fed a standard mixed diet, supplemented with swedes and hay (Norwegian standard for guinea pigs and rabbits, Statens institutt for folkehelse, Oslo, Norway). During anesthesia implants from demineralized, freeze-dried allogenic teeth were placed intra-muscularly as described elsewhere (2, 14). Three animals in each group were killed with ether after 7, 10, 14, 18, 21, 28 days respectively. The implants, excised with some surrounding tissue, were placed in Histocon[®] for about 6 hours and then frozen at -140°C in pre-chilled isopentane (Kebo, Sweden). Sections, 7 μm thick, were cut; as far as possible these were serial sections.

The sections were incubated for demonstration of AcP using α -naphthyl acid phosphate as substrate and hexazotized pararosanilin as the azodye. The incubation medium, pH 5.0 (8) consisted of 10 ml sodium α -naphthyl AcP (Sigma Chem. Co. USA), 10 ml 0.1 M acetatbuffer, pH 5.1 and 0.1^{ml}/hexazotied

pararosanilin (Sigma chem. Co. USA).

The sections were incubated for 15 or 30 minutes, washed in distilled water and finally mounted in glycerin jelly. Controls were always performed simultaneously without the substrate in the incubation medium and also by heating sections for 10 min. in distilled water of 90°C prior to incubation in complete media.

PRETREATMENTS

Some of the sections were placed in 10% EDTA for 15 min. prior to incubation. Other sections were exposed to 1% formaldehyde (freshly prepared by depolymerization of paraformaldehyde) for 30 min. at room temperature, and then washed 15 min. and immersed in Triton X-100 solution (0.25% in acetatbuffer (pH 5) containing 0,25 M sucrose) for 30 min.

INHIBITORS

Sodium fluoride and sodium tartrate (100 mM final concentration), sodium molybdate (1 mM) and copper chloride (10 mM) respectively were added to the incubation medium.

Combinations of the various pretreatments and inhibitors were also performed. Sections stained at regular intervals with hematoxylin and eosin for morphological identification.

Results

After 14 days osteoid was observed in increasing amounts, and at 28 days considerable amounts of bone and osteoid were seen. Also cartilaginous areas were found. Remineralization of the implanted allogenic dentin was observed regularly at 18 days; this was more pronounced after 21 days and 28 days. After 7 days undifferentiated mononucleated mesenchymal cells were found in a fibrinous matrix near the implants. Multinucleated giant cells, dentinoclasts, appeared in increasing number after 10 days showing active resorption of the dentin. The resorption zones, however, contained also macrophages in addition to dentinoclasts. Especially along non-resorbed areas of the dentin, fibroblasts seemed to make a capsular reaction. (For detailed description of the cellular reactions see Bang (2), Nilsen (14)).

The AcP activity was very sparse in the implantation area at 7 days with positive staining only in some perivascular cells. From 10 days resorption zones showed intense staining intra-cellularly in both mononucleated and, especially, multinucleated cells. As early as after 14 days osteoblasts and osteoid osteocytes showed increased staining for AcP; this feature was evident throughout the experiment (fig.1). In mineralized bone the osteocytes showed only ^aweak staining for AcP in contrast to the cells in the osteoid and unmineralized cartilage. The dentinoclasts resorbing remineralized or unmineralized dentin exhibited intense staining (fig.1).

Suppression of ACP activity in matrix-producing areas occurred in sections incubated with tartrate added to the incubation solution, while the staining in macrophages and dentinoclasts remained unchanged (fig. 2). Pretreatment with EDTA in addition to the tartrate-containing medium resulted in absence of ACP in matrix resorbing cells as well. When sections were treated with EDTA prior to incubation in the inhibitor-free medium, enzyme activity in the matrix resorbing cells was considerably decreased (fig.3). Use of EDTA as pretreatment did not change the staining of the matrix-producing cells. Molybdate reduced enzyme activity generally except in a very few matrix-producing areas where a weak staining was observed. When the tissue sections were exposed to formaldehyde before incubation, the enzyme activity was totally inhibited, except in dentinoclasts where there was moderate staining. This activity, however, was totally inhibited when EDTA treatment was used in addition to formaldehyde before incubation. The addition of NaF to the incubation medium reduced enzyme activity in all areas, except some matrix resorbing areas at 21 days and 28 days, where there was moderate staining in dentinoclasts. In sections incubated with EDTA in addition to NaF this activity was eliminated. The general activity of ACP was reduced by CuCl_2 , except for a weak staining for ACP in some osteoblasts.

No difference in inhibition pattern between bone formation and cartilage formation areas was observed.

Sections incubated for AcP for 15 or 30 min. gave identical results. Control sections showed no AcP activity. The results are summarized in table 1.

Discussion

A considerable amount of osteoid and bone as well as some cartilage formation was found after implantation of freeze-dried allogenic dentin, confirming previous reports (2, 3, 14) suggesting an inductive mechanism for bone formation.

The occurrence of dentin resorption and the production of new bone and cartilage permitted intrasectional comparison between the reaction zones observed. The intense activity of AcP in the dentinoclasts confirmed previous reports of resorbing giant cells (5, 6, 12, 15). The first matrix production was seen at 14 days and already then there was moderate enzyme activity, indicating that AcP may have a function in the production or alteration of the matrix. Before that time AcP was seen from the 10th day on in dentinoclast and mononuclear cells found perivascularily or in the resorption areas. The findings in the resorbing cells are in accordance with the results from a study of bone induction by Böhning (4). He, however, could not demonstrate any AcP in matrix-producing cells. The unmineralized cartilage showed intense staining for AcP which is in keeping with the transversal enzyme histochemical study on the same model (15).

The cellular enzyme activity of bone producing cells is supported by previous reports (7, 11) where ACP in lysosomes and the golgi region of the cells has been demonstrated. High ACP activity in osteoblasts and young osteocytes suggests a role in the mineralization of bone for this enzyme. ACP was also found in osteoid osteocytes by Wergedal & Baylink (18) while Hammarström & Hasselgren (9) were unable to detect ACP in osteoid or the mineralizing front of human and monkey bone formation. Forthcoming results from enzyme electron microscopic studies on the present model have revealed ACP activity in lysosomes and also in the endoplasmic reticulum of the matrix-producing cells (16).

In the newly mineralized tissue the intra-cellular activity of ACP was lower than in osteoblast and osteoid osteocytes, suggesting that acid phosphatase in these matrix-producing cells belong to the bone formation phase rather than being autolytic enzymes or enzymes involved in osteolysis.

Staining for acid phosphatase when inhibitors and pretreatments were used, revealed at least two groups of acid phosphatases, namely ^{ACP} in matrix-resorbing cells and ACP in matrix-producing cells. The ACP in the resorption area was very sensitive to pretreatment by EDTA while it seemed to be rather resistant to tartrate added to the incubation medium, and pretreatment with formaldehyde. These features resemble the ACP in osteoclasts of normal bone (8, 9) and dentinoclasts of internal tooth resorption (12), and this

enzyme activity also strengthens the view that dentinoclasts are the same cells as osteoclasts (14). Göthlin & Ericsson (6) claimed that Na-EDTA did not inhibit AcP activity in mineralized tissues. Our results, however, showed that EDTA has an inhibitory effect on AcP in resorbing cells. In a few areas of resorption a NaF resistant AcP in dentinoclasts was found, while matrix-producing areas always gave negative staining. Hammarstrøm et al. (8) and Hasselgren & Strømberg (12), however, have reported that matrix-producing areas in rats contains AcP which, in contrast to the resorption zone, is slightly sensitive to NaF, when using 100 mM fluoride.

The present study revealed that AcP in the matrix-producing areas of induced heterotopic bone is different from the AcP in resorbing cells, concurring with results from histochemical studies on normal bone of rats (8). The present histochemical results are also in keeping with results from a chromatographic study of homogenates of normal bone (1) showing that the major AcP activity was tartrate resistant, while the second peak was completely inhibited by tartrate. This latter peak is suggested to constitute the AcP of the matrix-producing areas. The results from present histochemical inhibition studies as summarized in table 1 show that there are two distinct AcP isoenzymes in induced heterotopic bone formation in guinea pigs.

Table I.

Acid phosphate activity in the bone induction area.

	Dentinoclast	Osteoblasts	Osteocytes/ chondrocytes	Perivascular cells
AcP	+++	+++	+++	++
AcP+Form.	++	o	o	o
AcP+Form.+EDTA	o	o	o	o
AcP+EDTA	o	++	++	o
AcP+Tartrate	+++	o	o	+
AcP+Tartrate+EDTA	o	o	o	o
AcP+NaF	++ ¹⁾	o	o	o
AcP+NaF+EDTA	o	o	o	o
AcP+Molybdate	o	o	o	o
AcP+CuCl ₂	o	+ ²⁾	o	o

1) found only in some dentinoclasts

2) found only in some osteoblasts

o No or negligible staining
+ Low staining
++ Moderate staining
+++ Intense staining

Legends to figures

Fig. 1 ACP activity in dentinoclasts (arrowhead)
and bone formation area (O) without any
pretreatments or inhibitors in the incubation
medium. Dentin (D). 14 days postoperatively.

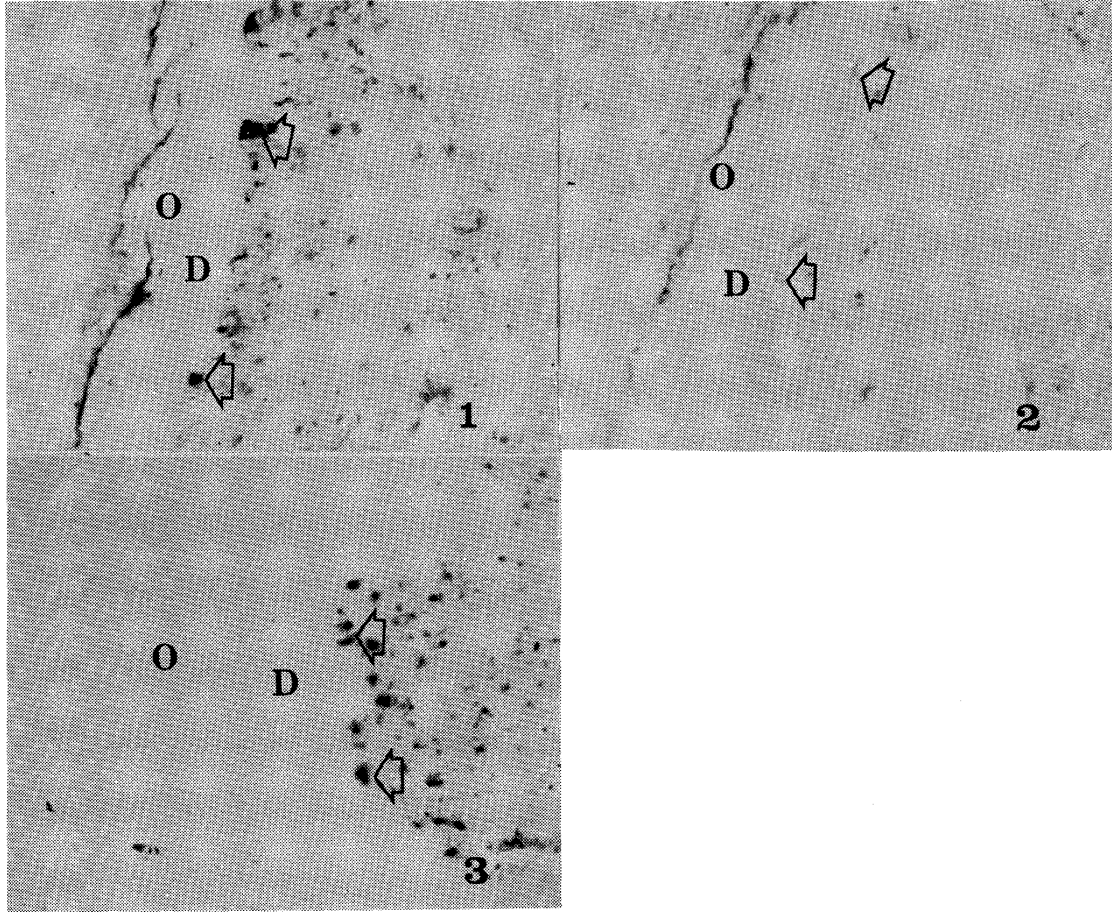
x122

Fig.2 Activity of ACP in dentinoclasts (arrowhead)
when tartrate is added in the incubation
medium. Dentin (D). Osteoid (O). 14 days
postoperatively.

x80

Fig.3 ACP activity after pretreatment with EDTA
showing great depression of the enzyme activity
in dentinoclasts (arrowhead) while the
activity in osteoid osteocytes was mainly
unchanged. Dentin(D). Osteoid (O). 14 days
postoperatively.

x 122



References

1. ANDERSON, T.R. & TOVERUD, S.U.: Chromatographic separation of two acid phosphatases from rat in bone. Calc. Tiss. Res. 1977: 24: 198-190.
2. BANG, G.: Induction of heterotopic bone formation by demineralized dentin : An experimental model in guinea pigs. Scand. J. Dent. Res. 1973: 81: 240-250.
3. BANG, G. & URIST, M.R.: Bone induction in excavation chambers in matrix of decalcified dentin. Arch. Surg. 1967: 94: 781-789
4. BÜHRING, K.: Enzyme pattern during bone induction. In: Studies on bone induction. Thesis Malmø, Sweden, 1974.
5. CABRINI, R.L., SCHAJOWIZ, F. & MERA, C.: Histochemical behaviour of the giant cell of foreign body granulomas as compared with the osteoclast. Experientia 1961: 18: 322-323.
6. GÖTHLIN, G. & ERICSSON, J.L.E.: Fine structural localization of acid phosphomonoesterase in the brush border of osteoclasts. Histochemie 1971: 28: 337-344.
7. GÖTHLIN, G. & ERICSSON, J.L.E.: Fine structural localization of acid phosphomonoesterase in the osteoblasts and osteocytes of fracture callus. Histochemie 1973: 35: 81-91.

8. HAMMARSTRØM, L.E., HANKER J.E. & TOVERUD, S.U.:
Cellular differences in acid phosphatase isoenzymes in
bone and teeth. Clin. Orthop. 1971: 78: 151-167.

9. HAMMARSTRØM, L.E. & HASSELGREN, G.: Acid Phosphatase
in developing teeth and bone of man and Macaque monkey.
Scand. J. Dent. Res. 1974: 84: 381-395.

10. HANKER, J.S., HAMMARSTRØM L.E., TOVERUD, S.U. &
YATES, P.E.: The formaldehydesensitivity of acid phosphatases
involved in osteogenesis and odontogenesis in
the rat. Archs oral Biol. 1972: 17: 503-509.

11. HANKER, J.S., DIXON, A.D. & SMILEY, G.R.: Acid phosphatase
in the golgi apparatus of cells forming extracellular
matrix of hard tissues. Histochemie 1973: 35: 39-50.

12. HASSELGREN, G. & STRØMBERG, T.: Histochemical
demonstration of acid hydrolase activity in internal
dental resorption. Oral. Surg. 1976: 42: 381-385.

13. MATHIESSEN, M.E.: Enzyme histochemistry of the
prenatal development of human deciduous teeth.
Acta Anat. 1967: 66: 375-386.

14. NILSEN, R.: Electron microscopy of induced heterotopic
bone formation in guinea pigs. Archs oral Biol. 1977:
22: 485-493.

15. NILSEN, R. & MAGNUSSON, B.C.: Enzyme histochemical studies of heterotopic bone formation in guinea pigs. Archs oral Biol. 1979: 24: 833-841.

16. NILSEN, R & MAGNUSSON, B.C.: Enzyme histochemical studies of induced heterotopic cartilage and bone formation in guinea pigs with special reference to acid phosphatase. A light and enzyme electron microscopic study. Submitted to Scand.J.Dent.Res.

17. TOVERUD, S.U., HAMMARSTRØM, L.E. & KRISTOFFERSEN, U.M.: Quantitative studies on acid phosphatase in developing rat bones and teeth during hypervitaminosis D. Archs oral Biol. 1975: 20: 175-181.

18. WERGEDAL, J.E. & BAYLINK, D.J.: Distribution of acid and alkaline phosphatase activity in undemineralized sections of the rat tibial diaphysis. J. Histochem. Cytochem. 1969: 17: 799-806.

