

## Anne Ingvarsson-Sundström: HUMAN REMAINS FROM TEGEA

### *Introduction*

During the excavations in 1990–94 and 2004 in the northern sector of the sanctuary of Athena Alea at Tegea human remains from both primary and secondary burials were recovered. The burials belong to a mid-Byzantine necropolis, probably dating to the 11th–12th century A.D. and disturbed by later activities, according to the excavation reports in sections **iii** (Luce), 39–44, and **vi** (Tarditi), 99–101. The skeletal material is heterogeneous: several skeletons belong to secondary assemblages (pit burials) often comprising more than one individual. **Sk 3, 7, 10** and **11** are typical examples. Others were found in very simple, primary grave contexts (without cists or coffins). The primary graves held an individual buried in an outstretched position on the back, in most cases (**Sk 1, 2, 8**) with hands folded on the chest. In some cases (**Sk 2, 4, 8**) there are traces of one or more other individuals, occasionally a child, also with these burials. Four individuals (two females, a male and an infant: **Sk 2, 3, 5, 16**) exhibit metal staining on the cranium or shoulder/chest. (See the skeletal catalogue and *Fig. 3*)

### *Material and methods*

The majority of the skeletons were studied in 2006 at the storage facility of the Tegea museum; one individual, **SkN 16**, was found in 2004 and studied in 2007. The bones had been packed in boxes containing information about the trench number and sometimes the excavation year. Only in some cases was a grave number or find number available, and some boxes had no information except for the number of a grid square. During the osteological examination, each box was therefore treated as a separate find context. After examination, additional information became available from the excavators indicating that some boxes were parts of the same assemblage. Thus, some bone contexts that were initially treated separately, were merged during the data processing without an ocular inspection for matches between morphologically similar bones. In several cases these bone units included bones from more than one individual, sometimes only represented by one or a few “extra” bones. For the sake of consistency, a minimum number of individuals (MNI) figure is included for all bone units; for the entire body material, this MNI figure is 33 individuals.

The age and sex determination of adults generally follows the recommendations in the publications WEA 1980 (Workshop of European Anthropologists) and Bass 1987. The following criteria have been taken into consideration for age determination of adults: 1) tooth wear (most frequently observable criterion) according to the scheme by Brothwell 1972; 2) morphology of *symphysis pubis* (Todd’s phases); 3) epiphyseal union; 4) suture closure (often only observable on fragments of the cranium). The criteria used for sex determination are: 1) morphology of the *os coxae*; 2) morphology of the cranium and mandible; 3) postcranial measurements. Sex determinations were only made on adults since the sex determinations of subadult skeletons (*i.e.* skeletally immature individuals, before puberty) is considered unreliable.

For age determination of subadults tooth formation is known to have the best correlation with chronological age (Ubelaker 1989, 63). Unfortunately, none of the children in the present material had any preserved teeth. Therefore, biological age was assessed through bone size, *i.e.* measurements of long bone diaphysis (registered in *Tab. 3*) and metaphyses according to the growth standard compiled by Sundick 1978. When no measurable bones were present, a more general observation of morphology and size has been used as an indication of age group.

All available criteria have been taken into consideration for the age and sex determinations, but since most skeletons were fragmentary and the find contexts often consisted of mixed bones from more than one individual their accuracy is highly variable. Also, many individuals did not have any age criteria preserved ( $n = 9$ ) and could only be assigned to a general adult category on the basis of size and morphology. For analytical purposes, individuals with inadequately preserved sex characteristics (*i.e.* marked as probable males/females in the catalogue) have been classified as male/female in the tables and figures.

The small and heterogeneous sample makes interpretations of health status difficult, but a short summary of the distribution of pathological conditions has nevertheless been included. In addition, two samples of proto-Byzantine date from other sites, Messene in the Peloponnese and Eleutherna on Crete (Bourbou 2003) are referred to for comparison of stature and pathologies. An inventory of skeletal preservation and an assessment

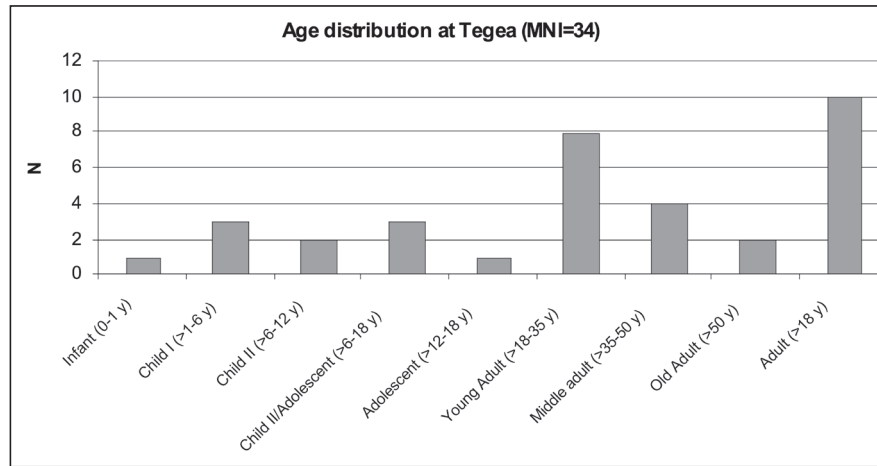


Figure 1. Age distribution. Minimum number of individuals (MNI). (Prepared by the author)

Age	Females	Males	Sex unknown
Infants (0-1 y)	-	-	1
Child I (> 1-6 y)	-	-	3
Child II (> 6-12 y)	-	-	2
Child II/Adolescent (> 6-18 y)	-	-	3
Adolescent (> 12-18 y)	-	-	1
Young Adult (> 18-35 <sup>y</sup> )	4	3	1
Middle Age Adult (> 35-50 y)	1	2	1
Old Adult (> 50 y)	1	1	-
Adult (> 18 y)	2	1	7
Total	8	7	19

Table 1. Age and sex distribution of the skeletal sample (number of individuals). (Prepared by the author)

of age and sex characteristics together with descriptions of pathologies, non-metrical traits and stature for each analytical unit are given in the skeletal catalogue (Tab. 3).

#### Age and sex distribution

An archaeological cemetery population is expected to contain an equal proportion of males and females, and to have the characteristic U-shaped mortality curve which is typical of today's developing countries, where most deaths occur among the very young (0–1 years old) and in the old age groups (Waldron 1994, 20). This sample comprises an equal amount of females and males and an approximately equal number of adults and subadults. (Tab. 1) When the sample is compared to the expected pattern, it is evident that infants and old adults are under-represented, while young adults are over-represented. (Fig. 1) A similar age distribution is commonly found in many diverse archaeological samples, but the same pattern is not seen in documented historical populations, or in model life tables (Chamberlain 2006, 90). The most

probable explanation for this difference is a systematic bias acting upon the skeletal sample. The under-representation of infants is often explained as resulting from 1) poor preservation because of their small and fragile, less mineralized bones, 2) shallow graves which may be easily disturbed or 3) normative funerary rites causing infants to be excluded from, or buried in a separate part of the cemetery (Saunders 2000, 136–7). Furthermore, excavation techniques can also affect the identification of infants since their tiny bones are not always detected or are sometimes mistaken for animal bones. It is likely that a number of factors contributed to the scarcity of infants found at Tegea, but since most adult bones are in good condition even if fragmentary, soil composition probably played a minor role for their under-representation. It should be noted that all bones from subadults were found in mixed contexts (*i.e.* with bones of adults) and there are no indications of primary child burials.

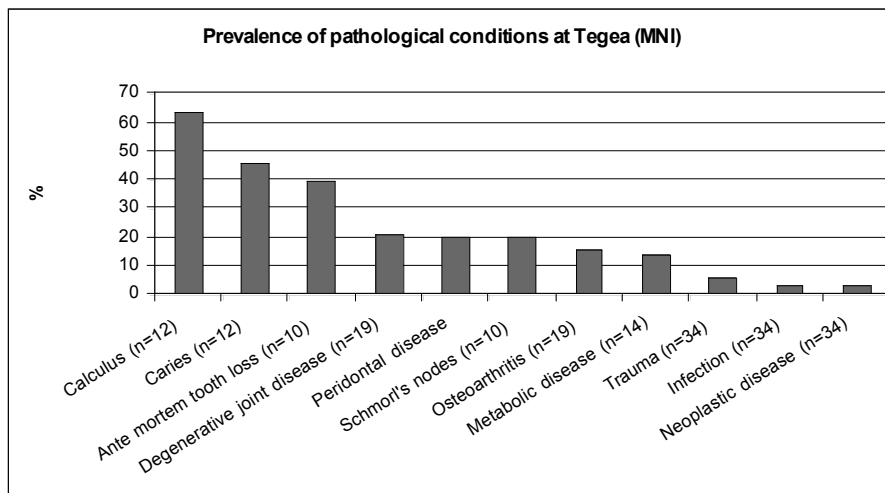
The anomalous pattern of adult mortality with peaks in the young/middle adult age groups is seen in many archaeological skeletal samples, and has for a long time been a subject of scholarly discussion (Chamberlain 2006 with further references). This distribution may be explained by a number of factors, but the most important one is probably the shortcomings of macroscopic osteological age determination techniques which are known to result in a systematic under-aging of old adults (Jackes 2000, 419). Unfortunately, the combination of mixed find contexts, and a fragmentary and small sample with several adults that could not be attributed to an age category makes it difficult to assess which factor had the greatest impact on the adult age distribution.

#### Stature

A mean stature has been calculated using the formula provided by Trotter and Gleser (reproduced in Bass 1987). The mean stature of the females ( $n = 3$ ) and males ( $n = 4$ ) is 157.1 and 169.2 cm respectively (overall mean 163.1 cm). The male stature is comparable to the males

	Females	Males	Sex unknown	Total
MNI with teeth preserved	5	5	1	11
No. of teeth	65	87	14	166
MNI with complete or partial preservation of mandible and/or maxilla	4	5	1	10
No. teeth with caries	3	4	1	8
MNI with caries	2	2	1	5
No. teeth lost before death	15	4	1	20
MNI with teeth lost before death	1	2	1	4
No. teeth with calculus	21	37	7	65
MNI with calculus	3	3	1	7

**Table 2.** Oral status: distribution of preserved teeth and jaws and dental pathologies (number of teeth and MNI). (Prepared by the author)



**Figure 2.** Individually based prevalence of pathological conditions (minimal number of individuals observable for the condition within parenthesis). (Prepared by the author)

in the proto-Byzantine samples used for comparison (Eleutherna 169 cm, Messene 170 cm), while the female stature is between the mean female stature at the two sites (Eleutherna 160 cm, Messene 152 cm). The overall mean stature, ca. 163 cm, is close to the proto-Byzantine samples: Eleutherna, overall mean 164.5 cm; Messene, overall mean 161 cm (Bourbou 2003, 304, tab. 1).

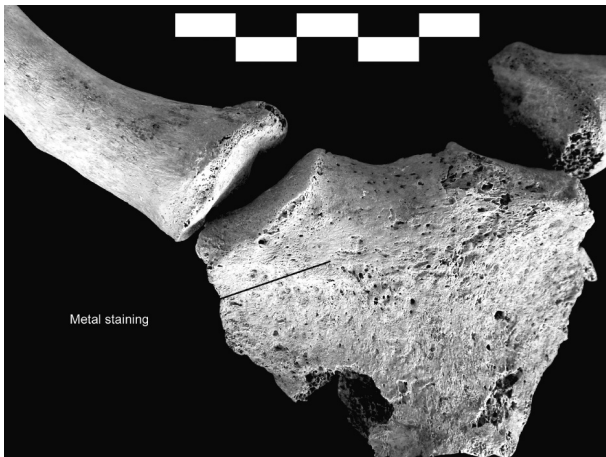
### Palaeopathology

The prevalence of pathological conditions calculated from the number of individuals observable for the condition is summarized in Fig. 2.

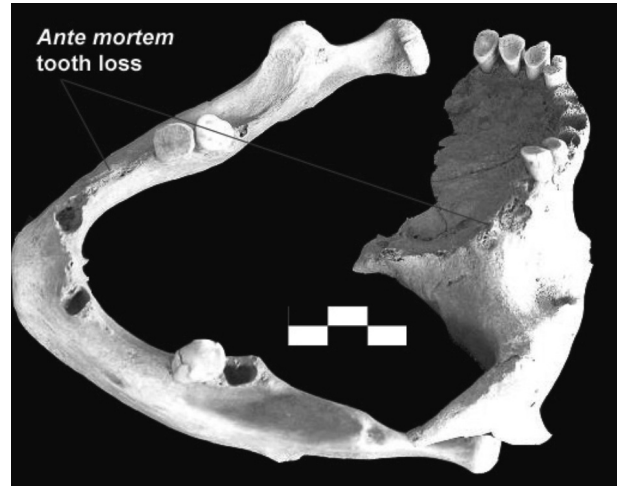### Oral status

Less than half of the adults (48%) and none of the children had teeth and/or jaws preserved. (Tab. 2) Caries affected equal numbers of males and females, all of them young adults. A slight to moderate degree of calculus was found in 64% of the individuals, while *ante mortem* tooth loss (AMTL) was less common (40%). (Fig. 4) However, AMTL probably resulted from advanced caries in many

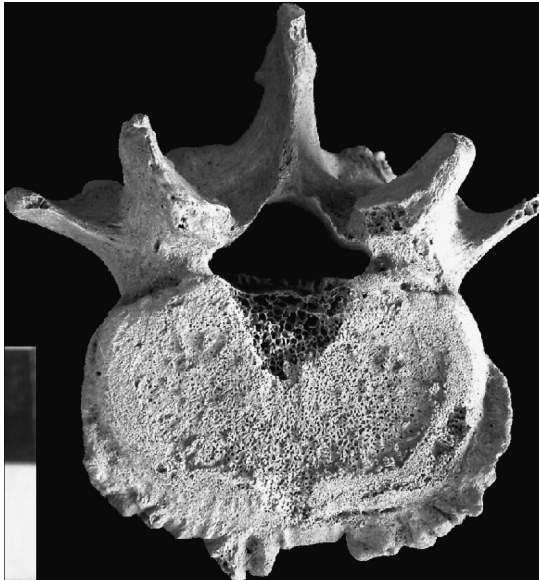cases. Caries is associated with a diet rich in carbohydrates and arises from acid attacks on the enamel produced by bacteria in dental plaque (*i.e.* the accumulation of microorganisms from food debris) (Hillson 1996, 269; Mays 1998, 149–50). Calculus is a mineralized matrix of dental plaque commonly found on the tooth crowns of uncleaned teeth, and it is often associated with foods with high protein content (Hillson 1979, 150). The frequency of teeth with caries at Tegea (5%) is quite low, but comparable to Bourbou's proto-Byzantine samples in which 3–4% of the total number of teeth demonstrate carious lesions (Bourbou 2003, 305, tab. 2). The frequency of teeth with calculus, on the other hand, is much higher at Tegea (39%) than in the previously mentioned proto-Byzantine samples (4–10%). Even if caries and calculus frequencies do not only depend on diet but also on a range of physiological factors, it is likely that a diet low in carbohydrates but with moderate to high protein content could contribute to low frequencies of caries and high frequencies of calculus (Hillson 1979). However, the Tegea sample is much too small to allow generalizations to be made about the diet of the population as a whole.



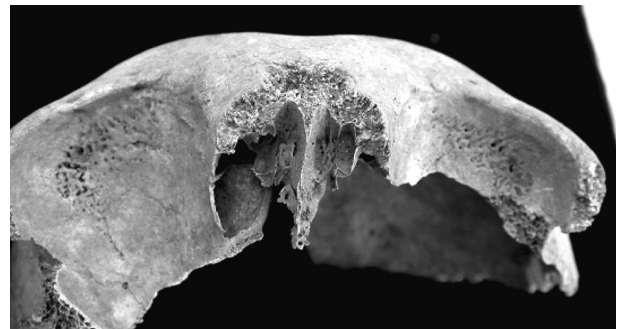
**Figure 3. Sk 16:** Sternum with discoloration from contact with metal. (Photo: Ingvarsson-Sundström)



**Figure 4. Sk 9:** Maxilla and mandible with *ante mortem* tooth loss. (Photo: Ingvarsson-Sundström)



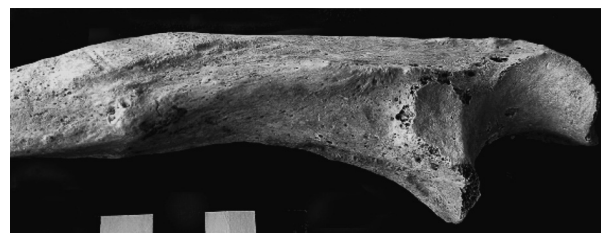
**Figure 5. Sk 8:** Lumbar vertebra with osteophytes. (Photo: Ingvarsson-Sundström)



**Figure 6. Sk 1:** Cribra orbitalia. (Photo: Ingvarsson-Sundström)



**Figure 7. Sk 16:** Rib-fractures. (Photo: Ingvarsson-Sundström)



**Figure 8. Sk 16:** Healed fracture of the right ulna. (Photo: Ingvarsson-Sundström)

*Degenerative joint disease and osteoarthritis*

Only thoracic and lumbar vertebrae were affected by osteophytes, *i.e.* bony spurs around the margins of the vertebral bodies (*Fig. 5*); the overall frequency (calculated from the number of observable vertebrae) of 15% is comparable to the frequency at Eleutherna, and higher than at Messene. Osteophytes may be found in any joints and they are common in adult skeletal remains since they are associated with the natural ageing process. Nevertheless, a strenuous lifestyle with heavy manual work probably increases their frequency (Roberts and Manchester 1997, 106–7). In addition to the presence of vertebral osteophytosis one adult also had osteophytes present in one interphalangeal joint of the foot.

Schmorl's nodes are marks on the vertebral bodies resulting from herniation of the intervertebral disc material through the end plate (Rogers 2000, 169–70). The condition is associated with osteophytes although the aetiology is unclear; physical stress and/or weakness of tissues (discs and/or underlying bone) are thought to be of major importance (Roberts and Manchester 1997, 107; Chamberlain 1994, 32). Schmorl's nodes are found in two young adults and the frequency of affected vertebrae is 10% of the bones (15/153), which is once again similar to the sample from Eleutherna and slightly higher than at Messene (Bourbou 2003).

There are also three cases of osteoarthritis (here defined as porous pitting of articulation surface and/or eburnation); one young adult female had severe osteoarthritis in one of the hip joints and one mature male shows porosity of the sternoclavicular joint, while another individual of unknown sex and age shows porosity and pitting of the medial articulation surface of the right clavicle.

*Other pathological conditions*

There is also some evidence of metabolic disease at Tegea: one young adult male shows a medium degree of *cribra orbitalia* (pitting of the roofs of the orbits; *Fig. 6*) and one old adult female shows medium to marked degree of porotic hyperostosis (*i.e.* fine perforations on the outside of the skull vault). These conditions are commonly associated with different types of anaemia; the body responds to the condition with an increase in the blood-producing red marrow, thus causing thinning of the outer tables of the skull and hypertrophy of the trabecular bone (Aufderheide and Rodriguez-Martin 1998, 348–50; Roberts and Manchester 1997, 167).

Traumas are also attested at Tegea: one adult of unknown sex has a healed rib fracture and another young adult male has three fractured ribs (*Fig. 7*), a healed fracture on the proximal diaphysis of the right ulna (*Fig. 8*) as well as an injury to a hand phalanx.

Furthermore, one old adult male has an ivory osteoma on the left parietal. This type of osteoma is a small, compact, button-shaped formation present on the outer table of the skull. Ivory- or button-shaped osteomata are common in ancient skeletal material and they were

probably symptom-less for the affected individual (Roberts and Manchester 1997, 187–9).

*Summary and conclusion*

The skeletal sample found at Tegea belongs to a minimum number (MNI) of 34 individuals found in primary and secondary grave contexts. There is an equal number of males and females, but half of the adult individuals were too incomplete for sex determination. Infants are clearly under-represented and young adults seem to be over-represented. A range of factors could explain this pattern: the most important factor for the infant underestimation is probably cultural practices whereas the scarcity of old adults is more likely caused by methodological biases in currently available age determination techniques.

However, the distribution of adult age material is difficult to interpret because 42% of the adults were too incomplete for a more detailed age determination.

The health status of the Tegean individuals seems to be quite similar to the Messene and Eleutherna samples which are probably much earlier in date. Mean stature and degenerative vertebral pathology frequency at Tegea are comparable to the Eleutherna sample and slightly higher than at Messene. Also, the caries frequency at Tegea is similar to that of Eleutherna whereas the calculus frequency is much higher, possibly indicating a diet largely based on plant and animal protein.

The skeletons from Tegea are too few and fragmentary to provide any conclusive evidence about the mid-Byzantine demography or disease frequency at the site, but the overall impression gained from the skeletal remains is that strenuous physical activities most certainly formed part of everyday life for the people buried in this cemetery. They were hard-working people, living in simple conditions.

*Skeletal catalogue**Abbreviations:*

Prox	Proximal epiphysis
Prox+dia	Proximal epiphysis and part of or complete diaphysis
Dia	Diaphysis
Dia+dist	Part of or complete diaphysis and distal epiphysis
Dia-prox	Proximal 1/3 of diaphysis (not including the proximal epiphysis)
Dist	Distal diaphysis
R	Right
L	Left
I	Incisive
C	Canine
PM	Premolar
M	Molar
MC	Metacarpal
MT	Metatarsal
AMTL	<i>Ante mortem</i> tooth loss
MNI	Minimum number of individuals
Seq. no.	Serial number in the bone database

**Sk 1**

Unit D7/08 (06.08.90) Seq. nos 1–3, 7

Fairly well-preserved remains of a young adult male missing large parts of the lower limbs (MNI: 1). Photo: section **iii** (Luce), 42 Fig. 6.

**Skull**

Frontal: complete, L/R parietal: fragmentary, L/R temporal: complete, occipital: almost complete, mandible: complete, L/R maxilla: complete, L/R zygomatic: complete.

**Teeth**

*Maxillary L*: I1, I2, C, PM1, PM2, M1, M2, M3. *Maxillary R*: I1, I2, C, PM1, PM2, M2, M3.

*Mandibular L*: I1, I2, C, PM1, PM2, M1, M2, M3. *Mandibular R*: I1, I2, C, PM1, PM2, M1, M2, M3.

**Post-cranial skeleton**

*Upper limb*: L/R humerus: complete, L radius: complete, R radius: almost complete, L ulna: complete, R ulna: prox+dia, distal fragment. *Hand*: L/R scaphoid: complete, L lunate: complete, R lunate: fragment, L triquetral: complete, L/R trapezium: complete, L/R trapezoid: complete, R capitate: complete, R hamate: fragment, L/R MC1: complete, L/R MC2: complete, L/R MC3: complete, L/R MC5: complete, proximal phalanges: 8 complete, intermediate phalanges: 4 complete, distal phalanges: 4 complete.

*Lower limb*: L femur: prox, fragment dia, R femur: 2 fragments prox+dia and dia+dist. Fibula: fragment of dia. *Foot*: proximal phalanges: 1 complete. *Shoulder girdle*: L/R clavicle: complete, L/R scapula: fragment. *Thorax*: sternum-manubrium, L ribs: 9 fragments, R ribs: 10 fragments. *Vertebral column*: atlas: complete, axis: complete, cervical vertebrae: 5 complete, thoracic vertebrae: 12 complete, lumbar vertebrae: 5 complete. *Pelvis*: sacrum: almost complete, L cox: fragmentary ilium and ischium, R cox: fragmentary ilium and ischium and pubis.

**Age**

Young Adult. Criteria: *Pubic symphysis morphology*: Todd's phase 6 (30–35 y). *Epiphyseal union of long bones*: complete. *Dental attrition*: 25–35 y. *Suture closure*: lambdoid: minimal closure, sagittal and coronal sutures: open.

**Sex**

Male. Criteria: *Pelvic morphology*: preauricular sulcus: absent, incisura ischiadica major: narrow and V-shaped, arc compose: single curve, os coxae: slightly male traits, corpus ossis ischii: very broad, crista iliaca: definite S-form, fossa iliaca: high and narrow. *Cranial morphology*: glabella: marked, processus mastoideus: large, relief of the planum nuchale: rough surface, arcus superciliaris: very marked, tuber frontale: missing, protuberantia occipitalis externa: very marked, inclinatio frontalis: medium inclined, forma orbitalis: quadrangular/rounded. *Mandible*: total aspect: robust, mentum: medium, angulus mandibulae: strongly marked eminences. *Post-cranial measurements*: humerus: male? and male, scapula (glenoid cavity): male, femur: male.

**Stature**

165.2 cm (humerus, radius, ulna).

**Oral status**

*Ante-mortem tooth loss*: RM1 (maxilla). *Caries*: RPM2 (maxilla): distal; LI1 (maxilla): mesial; RM2 (mandible): buccal. *Calculus*: Moderate amount on both maxillary and mandibular anterior teeth. *Periodontal disease*: resorption of the alveolar process: maxillary LM1.

**Variation in tooth position**

Crowding of teeth is visible in the lower jaw; the first left incisor has been pushed forward and the right canine is slightly rotated.

**Bone pathology**

*Cribra orbitalia*: present in both orbits (medium degree; see Fig. 6). *Osteoarthritis*: R clavicle: lateral epiphysis.

**Non-metric traits**

Two supra orbital foramina are present on the right side. Sacralized vertebra (L5).

**Sk 2:**

Unit D7/07 (02–03.08.90) Seq. nos 4–6

Fragmentary remains of a young adult female and a few additional bones from an adult of unknown sex and an infant (MNI: 3). The infant has green staining (from metal) on the left clavicle. Photo: section **iii** (Luce), 42 Fig. 5.

**Skull**

L parietal: complete.

**Teeth**

*Maxillary L*: M1.

*Mandibular L*: I1, PM2. *Mandibular R*: PM2.

**Post-cranial skeleton**

*Upper limb*: L humerus: prox+dia, R humerus: complete, L radius: almost complete, R radius: complete, L/R ulna: complete. *Hand*: L scaphoid: complete, L triquetral: complete, L trapezium: complete, L/R capitate: complete, L hamate: complete, L MC1: complete, L MC2: complete, L/R MC3: complete, L MC4: fragmentary, 2 R MC4: complete, L/R MC5: complete, proximal phalanges: 5 complete, intermediate phalanges: 5 complete, distal phalanges: 2 complete. *Lower limb*: R femur: dia+dist (infant), L femur: almost complete, R femur: prox, tibia: almost complete. *Foot*: L/R calcaneus: complete, L/R talus: complete, R navicular: complete, MT: 2 fragments. *Shoulder girdle*: L/R clavicle: fragment, R clavicle: fragment (infant), L clavicle: shaft+dist (infant), L/R scapula: complete. *Thorax*: sternum: fragment, L ribs: 6 fragments, unside ribs: 50 fragments, unside rib: fragment (infant). *Vertebral column*: cervical vertebrae: 1 fragment, thoracic vertebrae: 19 almost complete, thoracic vertebrae: 2 arc fragments, lumbar vertebrae: 9 almost complete. *Pelvis*: sacrum: fragmentary segment nos. 1, 3 and 4, L/R coxa: almost complete ilium and ischium.

**Age**

1 Young Adult; also 1 Adult (unknown age), 1 Infant (probably newborn). Adult criteria: *Epiphyseal union of long bones*: complete. *Dental attrition*: 25–35 y. *Suture closure*: sagittal suture and lambdoid suture beginning to fuse. Subadult criteria: size and morphology.

**Sex**

1 female, 1 adult (unknown sex), 1 infant (no sex determination). Criteria: *Pelvic morphology*: preauricular sulcus: present, incisura ischiadica major: wide. *Cranial morphology*: marked tuber parietale. *Post-cranial measurements*: femur: female, humerus: female, scapula (glenoid cavity): female.

**Stature**

152.8 cm (humerus, radius, ulna).

**Oral status**

*Calculus*: Moderate amount on mandibular left I1.

**Bone pathology**

*Osteoarthritis*: L coxa: pitting and polishing (eburnation) of the acetabulum. L femur, caput femoris: porous pitting and also some deformation of the femoral head. *Degenerative joint disease and Schmorl's nodes*: six thoracic vertebrae inferior/superior body surface, on one vertebra only on the superior body surface. Slight lipping on bodies. *Schmorl's nodes only*: three lumbar vertebrae on the inferior/superior body surface, one lumbar vertebra on the superior body surface.

**Sk 3:**

*Unit D6/04 Seq. no. 8*

Secondary burial. Three fragmentary crania and a few post-cranial remains of three adults (MNI: 3). The female cranium (cranium A) shows green discolouration (from metal) above the left external auditory meatus.

**Skull**

Three fragmentary crania:

*Cranium A*: frontal: complete, L/R parietal: complete, L temporal: complete, occipital: complete. *Cranium B*: frontal: complete, L/R parietal: complete, occipital: complete, L/R temporal, L/R sphenoid, L/R nasale: fragmentary. *Cranium C*: L frontal: fragmentary, L parietal: fragmentary.

**Post-cranial skeleton**

*Upper limb*: L humerus: prox+dia. *Lower limb*: L femur: complete. *Pelvis*: L coxa: fragmentary ilium.

**Age**

2 Middle Adults, 1 Adult.

Criteria: *Suture closure*: Cranium A: ectocranial suture closure complete (coronal suture almost completely obliterated). Cranium B: ectocranial suture closure complete (sagittal suture almost completely obliterated, the spheno-occipital synchondrosis is closed). Cranium C: significant ectocranial closure of coronal suture.

**Sex**

1 female? (middle adult), 2 unknown sex (middle adult and adult).

*Cranium A*: female. Criteria: *Cranial morphology*: glabella: smooth, processus mastoideus: small, relief of the planum nuchale: nuchal lines and occipital crest evident, arcus superciliaris: smooth, tuber frontale and parietale: medium, protuberantia occipitalis externa: very marked, inclinatio frontalis: vertical.

*Cranium B*: male/female? Criteria: *Cranial morphology*: glabella: smooth, processus mastoideus: medium, relief of the planum nuchale: marked, arcus superciliaris: marked, tuber frontale: indistinct, protuberantia occipitalis externa: very marked, inclinatio frontalis: almost vertical.

*Cranium C*: no criteria present.

*Pelvic morphology*: preauricular sulcus: present. *Postcranial measurements*: femur: female?/male, humerus: female/sex indeterminate.

**Stature**

156.6 cm (femur).

**Bone pathology**

*Anaemia*: Cranium A: marked porotic hyperostosis on the parietals, more limited on the frontal bone.

**Non-metric traits**

Cranium B: sutura metopica present; lambdoid ossicles present.

**Sk 4:**

*Units E6-D6/22 Seq. nos 9–17*

Fragmentary remains of an adult and a child (MNI: 2). Photo: section iii (Luce), 43 Fig. 8.

**Skull**

L/R mandible: fragmentary (R ramus missing).

**Teeth**

*Mandibular L*: PM1, PM2, M1, M2. *Mandibular R*: C, PM1, PM2, M1, M2.

**Post-cranial skeleton**

*Upper limb*: R humerus: complete, L humerus: almost complete (part of proximal part missing), L radius: complete, radius: unisided diaphysis fragment (child), L/R ulna: complete. *Hand*: R lunate: fragment, L capitate: complete, R hamate: complete, L/R MC1: complete, L/R MC2: complete, L/R MC3: complete, L/R MC4: complete, L/R MC5: complete, proximal phalanges: 6 complete, intermediate phalanges: 4 complete. *Lower limb*: L femur: prox, L femur: diaphysis (child), R femur: almost complete, L/R tibia: almost complete, L tibia: complete (child), fibula: fragments of diaphysis, R fibula: distal part. *Foot*: L/R calcaneus: complete, R MT3: complete. *Shoulder girdle*: L/R clavicle: complete, L/R scapula: fragmentary. *Thorax*: sternum: fragmentary manubrium, L ribs: 10 fragments, R ribs: 7 fragments, unisided ribs: 41 fragments. *Vertebral column*: cervical vertebrae: 2 almost complete, thoracic vertebrae: 12 almost complete, lumbar vertebrae: 5 almost complete. *Pelvis*: sacrum: complete, L coxa: ilium almost complete and ischium fragmentary, R coxa: ilium complete, ischium and pubis fragmentary.

**Age**

1 Young Adult, 1 Child I (ca. 1–3 y). Adult criteria: *Epiphyseal union*: complete. *Dental attrition*: 25–35 y. *Morphology of pubic symphysis*: Todd's phase 5 (27–30 y). Subadult criteria: size and development, postcranial measurements (tibia).

**Sex**

1 female (child: no sex determination). Criteria: *Pelvic morphology*: preauricular sulcus: present, incisura ischiadica major: very wide and U-shaped, ventral arc: present. *Mandible*: total aspect: gracile, mentum: small, angulus mandibulae: slight eminences, margo inferior: medium. *Post-cranial measurements*: humerus: female, scapula (glenoid cavity): sex undetermined, femur: female.

**Stature**

156.9 cm (humerus, radius, ulna).

**Oral status**

*Caries*: LM1 (mandible): mesial surface.

**Bone pathology**

*Schmorl's nodes*: 4 lumbar vertebrae.

**Non-metric traits**

Medium-sized septal aperture present on distal L/R humerus.

**Sk 5:**

*Grid squares D7-E7 (further dates missing) Seq. no. 10*  
Fragmentary remains of an adult, upper part of post-cranial skeleton well preserved (MNI: 1). Slight traces of green staining from metal above left mastoid process.

**Skull**

L parietal: fragmentary, L temporal: almost complete, L/R occipital: almost complete, L/R mandible: corpus, L/R maxilla: almost complete.

**Teeth**

*Maxillary L:* C, PM1, M1, M2, M3. *Maxillary R:* C, PM1, PM2, M2, M3.

*Mandibular L:* I1, I2, C, PM1, PM2, M1, M2, M3. *Mandibular R:* I1, I2, C, PM1, PM2, M1, M2, M3.

**Post-cranial skeleton**

*Upper limb:* L/R humerus: complete, L/R radius: complete, L ulna: complete, R ulna: almost complete. *Lower limb:* L femur: almost complete (prox+dia and dia+dist), R tibia: proximal part. *Shoulder girdle:* L clavicle: shaft+dist, R clavicle: complete, L/R scapula: almost complete. *Thorax:* sternum: almost complete, unsided ribs: 5 fragments. *Vertebral column:* cervical vertebrae: 7 almost complete, thoracic vertebrae: 3 almost complete. *Pelvis:* sacrum: almost complete, L coxa: almost complete but pubic symphysis missing, R coxa: ilium and ischium present.

**Age**

Young Adult. Criteria: *Epiphyseal union:* long bone epiphyses fused, sacral bodies S1 and S2 not fused, < 27 y of age. Clavicle: epiphysis covers most of the articular surface. Anterior median palatine suture not fused, incisive suture fused. *Dental attrition:* 17–25 y.

**Sex**

Female. Criteria: *Pelvic morphology:* preauricular sulcus: present (marked on right side), incisura ischiadica major: very wide and U-shaped, foramen obturatum: triangular. *Cranium:* mastoid process: medium. *Mandible:* mentum: medium, angulus mandibulae: slight eminences. *Post-cranial measurements:* femur: female?, humerus: female, scapula (glenoid cavity): sex undetermined.

**Stature**

162.1 cm (humerus, radius, ulna).

**Oral status**

*Caries:* RM3 (mandible), RM2 (maxilla). *Calculus:* slight, on all anterior teeth.

**Non-metric traits**

Sternal foramen present. Carabelli's cusp (maxillary RM2).

**Sk 6:**

*Unit D5/02 (season 1991) Seq. no. 11*

A few fragmentary remains (cranium and scapula) from an adult (MNI: 1).

**Skull**

L/F frontal: fragmentary but including L orbit and part of R orbit, L parietal: 3 fragments, R parietal: 7 fragments, occipital: 2 fragments.

**Post-cranial skeleton**

*Shoulder girdle:* scapula: 1 unsided fragment.

**Age**

Old adult? Criteria: *Suture closure:* significant ectocranial closure of coronal and sagittal suture, almost complete obliteration on the endocranial surface.

**Sex**

Male? Criteria: *Cranium:* Arcus supraciliaris: very marked, arched.

**Bone pathology**

*Neoplastic disease:* ivory osteoma on L parietal.

**Sk 7:**

*Unit E6/02 (11., 12. and 15.07.91) Seq. nos 12–16, 24–25*  
Secondary burial. Fragmentary and commingled remains of three adults and a child (MNI: 4).

**Skull**

R parietal: fragmentary, L/R mandible: complete and one part of a R mandible: coracoid process and part of corpus.

**Teeth**

Adult no. 1: *Maxillary R:* M1.

Adult no. 1: *Mandibular L:* I1, I2, C, PM1, M2, M3. *Mandibular R:* I2, C, PM1, PM2, M2, M3.

Adult no. 2: *Mandibular R:* M1, M2, M3.

**Post-cranial skeleton**

*Upper limb:* L humerus: complete, L humerus: dia fragment, L humerus: dist (child), R humerus: dia+dist, R humerus: fragments of dia+dist, L radius: complete, L radius: 2 prox+dia, R radius: almost complete, radius: 2 unsided dia fragments, L ulna: complete, R ulna: almost complete, R ulna: prox+dia, ulna: unsided fragment dia+dist (child). *Hand:* R lunate: complete, R trapezium: complete, L capitate: complete, L/R MC1: complete, L/R MC2: complete, R MC2: complete, L/R MC3: complete, L/R MC4: complete, R MC5: prox+dia, proximal phalanges: 8 complete, intermediate phalanges: 5 complete.

*Lower limb:* L femur: fragment prox (proximal epiphysis missing), L femur: 2 almost complete (proximal epiphyses missing) and 1 prox, R femur: 3 fragments, 1 prox, 1 dia and 1 dia+dist, tibia: 3 unsided fragments of dia and prox, R fibula: dia+dist. *Foot:* L talus: complete, L calcaneus: complete, L MT1: complete, L MT2: complete, 2 L MT3: complete, L MT4: complete, L MT5: complete, proximal phalanges: 1 complete. *Shoulder girdle:* L/R clavicle: complete, L/R scapula: almost complete. *Thorax:* sternum: complete, unsided ribs: 56 fragments. *Vertebral column:* cervical vertebrae: 7 complete, thoracic vertebrae: 12 complete, lumbar vertebrae: 2 complete and one fragment. *Pelvis:* L coxa: fragmentary ilium and ischium and one relatively complete part of ilium, 1 unsided ischium fragment. R coxa: acetabulum fragment.

**Age**

Child II (ca. 6–8 y), 1 Young Adult, 1 Middle Adult and 1 Adult. Adult criteria: *Epiphyseal union:* all long bone epiphyses fused. *Dental attrition:* 25–35 y and 35–45 y. Subadult criteria: size and development, postcranial measurements (humerus).



**Sex**

2 probable males (1 male, 1 male?), 1 probable female, 1 sex undetermined (child). Criteria: *Pelvic morphology*: 1) Ilium+ischium: incisura ischiadica major: narrow V-form (male). 2) Ilium: pre-auricular sulcus: absent, incisura ischiadica major: wide and U-shaped. *Postcranial measurements*: 2 L femurs: both male, 2 R humerus: 1 male, 1 male? and 1 sex undetermined. Scapula (glenoid cavity): male. *Mandible*: total aspect: very robust, angulus mandibulae: marked eminences, mentum: prominent.

**Stature**

178.3 cm (humerus, radius, ulna).

**Oral status**

*Caries*: mandible, LM3: caries on occlusal surface. *Ante mortem* tooth loss: mandible: LPM2, LM1, RM1.

**Bone pathology**

*Trauma*: one unisided rib fragment: healed fracture. *Osteoarthritis*: R clavicle: porous and pitted medial articulation surface. *Degenerative joint disease*: thoracic vertebrae: slight lipping, L1: slight lipping.

**Sk 8:**

*Unit C5-C6/63 (06. and 12.07.93) Seq. nos 18–20, 26–30*  
Fragmentary remains of two adults and a child (MNI: 3).  
Photo: section **iii** (Luce), 43 Fig. 9.

**Skull**

Frontal: complete, L parietal: fragmentary, parietal: 2 unisided fragments, L temporal: almost complete, L mandible: fragmentary, R mandible: fragmentary condyle, R maxilla: fragmentary, R zygomatic: complete, hyoid: complete.

**Teeth**

*Maxillary R*: I1, I2, C, PM2, M2.

*Mandibular L*: I2, PM1, PM2, M1, M2.

**Post-cranial skeleton**

*Upper limb*: L humerus: complete, R humerus: prox+dia, L radius: prox+dia, L radius: dist (child), R radius: dist, R radius: complete (child), radius: 2 unisided dia fragments, L ulna: prox+dia, L ulna: dia+dist (child), R ulna: dist, R ulna: prox+dia (child), ulna: 2 unisided fragments dia+dist.

*Hand*: R lunate: complete, R pisiform: complete, L trapezoid: complete, L hamate: complete, R MC1: complete, L/R MC2: complete, L/R MC3: complete, 2 R MC4: complete, 2 R MC5: complete, L MC5: complete, proximal phalanges: 10 complete, intermediate phalanges: 4 complete, distal phalanges: 3 complete.

*Lower limb*: L femur: 2 fragments dia+dist, L femur: prox+dia, R femur: prox (child), R fibula: prox+dia, L patella: almost complete, L tibia: prox+dia, fibula: unisided dia fragment. *Foot*: L MT5: complete, proximal phalanges: 2 complete, distal phalanges: 3 complete. *Shoulder girdle*: L clavicle: complete, R clavicle: shaft+distal part, L/R scapula: fragmentary. *Thorax*: sternum: corpus and fragmentary manubrium, L ribs: 7 complete, R ribs: 11 complete, L ribs: 4 fragments, R ribs: 2 fragments, unisided ribs: 57 fragments, 3 fragments (child). *Vertebral column*: atlas: fragmentary, cervical vertebrae: 7 complete, thoracic vertebrae: 7 complete and 4 fragmentary, lumbar vertebrae: 2 complete (nos 4–5) and 5 fragmentary. *Pelvis*: sacrum: almost complete, L coxa: fragmentary ilium, ischium and pubis, R coxa: fragmentary pubis, R coxa: fragmentary ischium (child).

**Age**

1 Middle Adult, 1 Adult, 1 Child I (ca. 1–3 y). Criteria: *Epi-physeal union of long bones and clavicle*: complete. *Morphology of pubic symphysis*: Todd's phase 7-8 (35–45 y). *Auricular surface*: phase 7 (50–59 y). *Suture closure*: only a part of L coronal suture preserved, minimal-significant closure on ectocranial surface (endocranial surface: complete obliteration). *Dental attrition*: 35–45 y. Subadult criteria: long bone length (radius).

**Sex**

1 male, 1 sex undetermined (no criteria present) and 1 child (no sex determination) Criteria: *Pelvic morphology*: sacrum: high and narrow, ventral arc: ambiguous, ischiopubic ramus ridge: broad. *Cranium*: arcus superciliaris: very marked and arched, glabella: massive and prominent, mastoid process: medium. *Mandible*: angulus mandibulae: moderate eminences. *Postcranial measurements*: humerus: male?, scapula (glenoid cavity): male.

**Stature**

167.1 cm (humerus).

**Oral status**

*Calculus*: slight amount on all teeth.

**Bone pathology**

*Degenerative joint disease*: thoracic vertebrae: medium lipping of one vertebra. Lumbar vertebrae (corpus): osteophytes present (see Fig. 5).

**Sk 9:**

*Unit C6/110 – /111 and /03, (26. and 28.07.94) Seq. nos 21–23*

Fragmentary remains of an adult with skull and upper part of the skeleton partially preserved (MNI: 1).

**Skull**

R frontal: fragmentary, L/R parietal: fragmentary, R temporal: almost complete, occipital: fragmentary, L/R mandible: complete, L/R maxilla: complete, L/R zygomatic: complete, L/R sphenoid: fragmentary.

**Teeth**

*Maxillary L*: I2, C, PM1. *Maxillary R*: I2, C, PM1, PM2.

*Mandibular L*: M1, M2. *Mandibular R*: M1, M2.

**Post-cranial skeleton**

*Upper limb*: R humerus: prox+dia. *Hand*: R MC2: complete. *Shoulder girdle*: R clavicle: almost complete, R scapula: almost complete. *Thorax*: ribs: 4 unisided fragments. *Vertebral column*: axis: complete, cervical vertebrae: 5 complete, thoracic vertebrae: 2 complete.

**Age**

Old Adult? Criteria: *Suture closure*: fragments of coronal suture and sagittal suture: significant ectocranial closure and complete obliteration on the endocranial surface.

**Sex**

Female? Criteria: *Cranial morphology*: processus mastoideus: small, relief of the planum nuchale: slightly arched traces of nuchal lines, arcus superciliaris: smooth, forma orbitalis: round, very sharp borders, tuber parietale: marked. *Mandible*: total aspect: very gracile, angulus mandibulae: smooth, mentum: small, rounded. *Postcranial measurements*: humerus: female, scapula (glenoid cavity): sex undetermined.

**Oral status**

*Ante mortem* tooth loss: L maxilla: PM2, M1, M2, M3. R maxilla: M1, M2, M3. L mandible: I1, C, PM1, PM2. R mandible: I1, C, PM1, PM2. (See Fig. 4)

**Sk 10:**

*Unit C7/35 (14–17.07.92) Seq. nos 31–35*

Secondary burial. Fragmentary remains of 2 adults, 1 child (A) and 1 child/adolescent (B) (MNI: 4). Photo: section **iii** (Luce), 40 Fig. 3.

**Skull**

Cranium (adult): L/R frontal: complete, nasale: complete, L/R sphenoid, R temporal: complete, occipital: basilar part and R condyle, 2 L/R maxilla: complete, L/R zygomatic: complete. L/R mandible: fragment mentum.

**Teeth**

*Maxilla no. 1: Maxillary L: I2, PM2, M1, M2, maxillary R: I1, I2, PM2, M2.*

*Maxilla no. 2: Maxillary L: I2, C, PM1, PM2, M1, M3, maxillary R: I1, I2, C, PM1, PM2, M1, M2, M3.*

*Mandibular L: I1, I2. Mandibular R: I1, I2, C, PM1, PM2.*

**Post-cranial skeleton**

*Upper limb: R ulna: dia-prox, R ulna: prox (child). Hand: L navicular: complete, R MC2: almost complete, intermediate phalanges: 1 complete.*

*Lower limb: L femur: prox (child A), L femur: prox (child B), L femur: dist (child B) R femur: prox+dia (child A), R tibia: prox+dia. Shoulder girdle: R scapula: fragment. Thorax: R rib no. 1: fragment (child A), unsided ribs: 19 fragments. Vertebral column: thoracic vertebrae: 6 complete. Pelvis: R coxa: ilium and pubis (child A).*

**Age**

2 Young Adults, 1 Child II (A; ca. 6–10 y), 1 Child II/Adolescent (B; ca. 11–16 y).

Criteria, adults: *Fusion* of synchondrosis spheno-occipitalis.

*Dental attrition: 2 individuals: 25–35 y.*

Criteria, children: size and morphology, measurements of postcranial bones (ilium, femur).

**Sex**

1 female?, 1 unidentified sex; 2 children, no sex determination. Criteria: *Cranial morphology: processus mastoideus: small, arcus superciliaris: smooth. Mandible: mentum: small, rounded.*

**Oral status**

*Ante mortem tooth loss: maxilla (no. 1): RC. Calculus: slight on teeth in maxillae nos 1 and 2, medium on teeth in mandible.*

*Caries: occlusal surface on LM3 in maxilla no. 2.*

**Variation in tooth position**

Impaction: LPM2 in maxilla no. 1, crown partly visible with cusps pointing in lingual direction.

**Sk 11:**

*Unit C7/02 (10.07.92) Seq. nos 36–38*

Secondary burial. Only a few fragmentary and commingled remains of an adult and two subadults (MNI: 3).

**Skull**

Un-sided parietal: 2 fragments, L temporal: almost complete, occipital: almost complete.

**Post-cranial skeleton**

*Upper limb: R humerus: dia+dist, R radius: dia, R ulna: prox.*

*Hand: L MC3: prox+dia. Lower limb: L femur: dia, R femur: dist and prox, R femur: dia+dist (subadult), L femur: dia fragment (subadult), 2 L tibia: dia fragments (subadult), R tibia: dia (subadult). Foot: R talus: complete, R calcaneus: complete.*

*Shoulder girdle: R scapula: fragment, L scapula: fragment.*

*Thorax: unsided ribs: 6 fragments. Pelvis: R coxa: fragmentary ilium and ischium.*

**Age**

1 Adult, 2 Child II/Adolescent (> 6–18 y).

Criteria, adult: epiphyseal fusion and morphology.

Criteria, subadult: size and epiphyseal fusion (distal femur: unfused), postcranial measurements (femur).

**Sex**

1 female, 2 adolescent individuals of unknown sex. Criteria:

*Pelvic morphology: preauricular sulcus: present, incisura ischiadica major: very wide and U-shaped. Cranial morphology: processus mastoideus: very small, relief of the planum nuchale: smooth. Post-cranial measurements: femur: female and male?, humerus: female.*

**Sk 12:**

*Unit C6/36 (15.07.92) Seq. no. 39*

A few foot bones from an adult (MNI: 1).

**Post-cranial skeleton**

*Foot: L calcaneus: complete, R cuboid: complete, R second cuneiform, R third cuneiform, L MT1: complete, R MT2: complete, R MT3: complete, R MT4: complete, R MT5: complete, L/R proximal phalanges no. 1: complete, proximal phalanges: 4 complete, L/R intermediate phalanges no. 1: complete.*

**Age**

Adult. Criteria: morphology and size.

**Sex**

No criteria present.

**Bone pathology**

*Degenerative joint disease: proliferative lesions in one proximal interphalangeal joint of the foot.*

**Sk 13:**

*Unit C7/100 (excavation date missing) Seq. no. 40*

Two bone fragments from an adult and a child (MNI: 2).

**Post-cranial**

*Upper limb: R humerus: dist (child). Thorax: unsided rib: 1 fragment (probably adult).*

**Age**

1 Adult?, 1 Child I (1–3 y). Criteria: size and morphology.

**Sex**

No criteria present.

**Sk 14:**

Unit C7/41 (20.07.92) Seq. no. 41

Only three fragments of the lower limb and foot from an adult (MNI: 1).

**Post-cranial**

*Lower limb:* L tibia: dia+dist, L fibula: dia+dist. *Foot:* R calcaneus: complete.

**Age**

Adult. Criteria: size and morphology.

**Sex**

No criteria present.

**Sk 15:**

Unit C7-C8/79 (13.07.94) Seq. no. 42

Fragmentary and commingled post-cranial remains of an adult and an adolescent (MNI: 2).

**Post-cranial skeleton**

*Upper limb:* L humerus: prox+dia, R humerus: dia fragment, R humerus: dia fragment (juvenile), R radius: dia+dist, L ulna: complete, L ulna: dia (juvenile). *Lower limb:* R femur: prox+dia. *Shoulder girdle:* clavicle: fragment, L scapula: acromion fragment. *Thorax:* L/R rib no. 1: 2 fragments, unisided ribs: 5 fragments. *Vertebral column:* thoracic vertebrae: 1 fragment.

**Age**

Adult and Adolescent. Criteria: size and morphology.

**Sex**

Female? Criteria: *Postcranial measurements:* femur: female.

**Sk 16:**

Units B8/09, /15, /16 (season 2004) Seq. no. 44

A well-preserved skeleton of an adult individual (MNI: 1). Before the excavation the lower parts of the legs and the feet of the skeleton had been destroyed by a bulldozer. Due to the fragmentary and fragile state of the skull it was taken up in one piece with soil supporting the cranial bones. Seven small sherds (including one glazed) were found among the bones. The sternum (manubrium) and the sternal end of the right clavicle show green discolouration from metal (see Fig. 3). This discolouration may well derive from the fibula which according to the excavator was found on the skeleton. (Figs 3, 7, 8; see also photo section vi (Tarditi), 101 Fig. 8)

**Skull**

L/R frontal: fragmentary, L/R parietal: fragmentary, L/R temporal: almost complete, L/R zygomatic: fragmentary, occipital: almost complete, mandible: complete, L/R maxilla: fragmentary.

**Teeth**

*Maxillary L:* I1, C, PM1, PM2, M1, M2, M3. *Maxillary R:* I1, I2, C, PM1, PM2, M2, M3.

*Mandibular L:* I1, I2, C, PM1, PM2, M1, M2, M3. *Mandibular R:* I1, I2, C, PM1, PM2, M1, M2, M3.

**Post-cranial skeleton**

*Upper limb:* R humerus: prox, dia+dist, L humerus: prox, dia+dist, L/R radius: complete, L/R ulna: complete. *Hand:* R scaphoid: complete, R lunate: complete, L/R triquetral: complete, L/R trapezium: complete, L/R trapezoid: complete, L/R hamate: complete, L/R navicular: complete, R MC1: complete, L/R MC2: complete, L/R MC3: complete, L/R MC4: complete, L/R MC5: complete, proximal phalanges: 9 complete and 1 fragmentary, intermediate phalanges: 5 complete, distal phalanges: 3 complete.

*Lower limb:* L/R femur: complete, L/R tibia: prox+dia, L/R fibula: prox+dia, L/R patella: almost complete. *Shoulder girdle:* L/R scapula: almost complete, L/R clavicle: almost complete. *Thorax:* sternum-manubrium and body: complete, L ribs: 9 fragments, R ribs: 10 fragments. *Vertebral column:* atlas: complete, axis: complete, cervical vertebrae: 5 complete, thoracic vertebrae: 12 complete, lumbar vertebrae: 5 complete. *Pelvis:* sacrum: complete, L coxa: complete, R coxa: complete ilium and ischium, fragmentary pubis.

**Age**

Young Adult. Criteria: *Pubic symphysis morphology:* Todd's phase 3–4 (22–26 y), Suchey-Brooks phase 2 (19–34 y). *Epiphyseal union:* complete on long bones, sacrum: S1 recently fused to S2 (line visible). *Dental attrition:* ca. 25–35 y.

**Sex**

Male. Criteria: *Pelvic morphology:* ventral arc: male, sub-pubic concavity: male, ischiopubic ramus ridge: male, greater sciatic notch: male, preauricular sulcus: absent. *Cranium:* nuchal crest: probable male, mastoid process: probable male. *Mandible:* mental eminence: ambiguous.

**Stature**

166 cm (femur).

**Oral status**

*Calculus:* slight amount on anterior teeth. *Enamel hypoplasia:* on L/R mandibular and maxillary canines and on mandibular LPM1. *Periodontal disease:* slight horizontal bone loss (alveolar process) below LM1, LM2 and LM3 (mandible).

**Non-metric traits**

Shovel-shaped maxillary incisors.

**Bone pathology**

*Traumas:* Three rib fractures: 1) R rib fragment: healed fracture, 1.5 cm from sternal end. 2) L rib fragment: unhealed fracture. 3) L rib fragment: healed fracture. (See Fig. 7) Healed fracture on R ulna, on proximal 1/3 of diaphysis. (See Fig. 8) Focal bone loss on dorsal side of a proximal hand phalanx, possibly resulting from trauma. *Infection:* L tibia: periosteitis (woven bone formation) on middle 1/3 of the diaphysis.

**References:**

- Aufderheide and Rodriguez-Martin 1998 = A.C. Aufderheide and C. Rodriguez-Martin, *The Cambridge encyclopedia of human palaeopathology*, Cambridge 1998.  
 Bass 1987 = W.M. Bass, *Human osteology. A laboratory and field manual*, Columbia Mo. 1987.  
 Bourbou 2003 = C. Bourbou, "Health patterns of Proto-Byzantine populations (6th–7th centuries AD) in south Greece: the

cases of Eleutherna (Crete) and Messene (Peloponnese),” *International journal of osteoarchaeology* 13, 2003, 303–13.

Brothwell 1972 = D.R. Brothwell, *Digging up bones*, 2nd ed., London 1972.

Chamberlain 1994 = A. Chamberlain, *Human remains*, London 1994.

Chamberlain 2006 = A. Chamberlain, *Demography in archaeology*, Cambridge 2006.

Hillson 1979 = S.W. Hillson, “Diet and dental disease,” *World archaeology*, 11:2, 1979, 147–62.

Hillson 1996 = S. Hillson, *Dental anthropology*, Cambridge 1996.

Jacks 2000 = M. Jackes, “Building the base for paleodemographic analysis,” in M.A. Katzenberg and S.R. Saunders (eds), *Biological anthropology of the human skeleton*, New York 2000, 417–66.

Mays 1998 = S. Mays, *The archaeology of human bones*, London 1998.

Roberts and Manchester 1997 = C. Roberts and K. Manchester, *The archaeology of disease*, 2nd ed., Ithaca 1997.

Rogers 2000 = J. Rogers, “The paleopathology of joint disease,” in M. Cox and S. Mays (eds), *Human osteology in archaeology and forensic science*, Cambridge 2000, 163–82.

Saunders 2000 = S.R. Saunders, “Subadult skeletons and growth related studies,” in M.A. Katzenberg and S.R. Saunders (eds), *Biological anthropology of the human skeleton*, New York 2000, 135–61.

Sundick 1978 = R.I. Sundick, “Human skeletal growth and age determination,” *Homo* 29, 1978, 228–49.

Ubelaker 1989 = D.H. Ubelaker, *Human skeletal remains. Excavation, analysis, interpretation*, Washington 1989.

WEA 1980 = “Workshop of European anthropologists 1980. Recommendations for age and sex diagnoses of skeletons,” *Journal of human evolution* 9, 1980, 517–49.

Waldron 1994 = T. Waldron, *Counting the dead. The epidemiology of skeletal populations*, Chichester 1994.

Seq. no.	Bone no.	Bone	Side	Measurement	mm
3	10	Clavicle	L	Max. length	141
3	10	Clavicle	L	Middle circumference	48
9	2	Clavicle	L	Max. length	139
9	2	Clavicle	L	Middle circumference	45
10	8	Clavicle	R	Max. length	134
10	8	Clavicle	R	Middle circumference	47
21	8	Clavicle	R	Max. length	120*
21	8	Clavicle	R	Middle circumference	48*
24	5	Clavicle	L	Max. length	150
24	5	Clavicle	L	Middle circumference	46
26	6	Clavicle	L	Max. length	145
26	6	Clavicle	L	Middle circumference	50
44	–	Clavicle	L	Max. length	133
9	15	Coxae	R	Max. breadth	151
10	15	Coxae	L	Max. breadth	157*
10	15	Coxae	L	Max. height	212*
8	1	Cranium A		Max. length (g) to (op)	185
8	1	Cranium A		Max. breadth (eu) to (eu)	136
8	2	Cranium B		Max. length (g) to (op)	189
8	2	Cranium B		Max. breadth (eu) to (eu)	148
3	12	Femur	L	Vertical diameter of caput femoris	46
3	12	Femur	L	Sagittal diameter of caput femoris	48

Seq. no.	Bone no.	Bone	Side	Measurement	mm
6	9	Femur	L	Mid-shaft sagittal diameter	23
6	9	Femur	L	Mid-shaft transverse diameter	21
6	9	Femur	L	Mid-shaft circumference	79
6	9	Femur	L	Upper transverse diaphyseal diameter	25
6	9	Femur	L	Upper sagittal diaphyseal diameter	19
6	10	Femur	R	Vertical diameter of caput femoris	37
6	10	Femur	R	Sagittal diameter of caput femoris	36
7	6	Femur	R	Upper transverse diaphyseal diameter	34
7	6	Femur	R	Upper sagittal diaphyseal diameter	26
7	6	Femur	R	Sagittal diameter of caput femoris	48
8	6	Femur	L	Max. length	404
8	6	Femur	L	Bicondylar length	401
8	6	Femur	L	Mid-shaft sagittal diameter	26
8	6	Femur	L	Mid-shaft transverse diameter	28
8	6	Femur	L	Mid-shaft circumference	95
8	6	Femur	L	Upper transverse diaphyseal diameter	32
8	6	Femur	L	Upper sagittal diaphyseal diameter	22
8	6	Femur	L	Vertical diameter of caput femoris	42

Seq. no.	Bone no.	Bone	Side	Measurement	mm	Seq. no.	Bone no.	Bone	Side	Measurement	mm
8	6	Femur	L	Sagittal diameter of caput femoris	42	36	2	Femur	L	Mid-shaft circumference	98
8	6	Femur	L	Epicondylar breadth	73	36	2	Femur	L	Upper transverse diaphyseal diameter	30
9	24	Femur	L	Vertical diameter of caput femoris	41	36	2	Femur	L	Upper sagittal diaphyseal diameter	27
9	24	Femur	L	Sagittal diameter of caput femoris	41	36	3	Femur	R	Vertical diameter of caput femoris	42
10	24	Femur	L	Upper transverse diaphyseal diameter	32	36	3	Femur	R	Sagittal diameter of caput femoris	45
10	24	Femur	L	Upper sagittal diaphyseal diameter	26	37	2	Femur	R	Epicondylar breadth	77
10	24	Femur	L	Vertical diameter of caput femoris	42	42	14	Femur	R	Upper transverse diaphyseal diameter	30
10	24	Femur	L	Sagittal diameter of caput femoris	43	42	14	Femur	R	Upper sagittal diaphyseal diameter	26
10	25	Femur	L	Epicondylar breadth	74	42	14	Femur	R	Vertical diameter of caput femoris	40
12	4	Femur	L	Vertical diameter of caput femoris	53	44	–	Femur	L	Max. length	440
12	4	Femur	L	Sagittal diameter of caput femoris	52	44	–	Femur	L	Bicondylar length	436
14	5	Femur	R	Vertical diameter of caput femoris	50	44	–	Femur	L	Vertical diameter of caput femoris	45
14	5	Femur	R	Sagittal diameter of caput femoris	49	44	–	Femur	L	Sagittal diameter of caput femoris	45
15	1	Femur	R	Mid-shaft sagittal diameter	31	44	–	Femur	L	Epicondylar breadth	82
15	1	Femur	R	Mid-shaft transverse diameter	30	3	13	Humerus	R	Max. length	299
15	1	Femur	R	Mid-shaft circumference	106	3	13	Humerus	R	Epicondylar breadth	63
15	1	Femur	R	Epicondylar breadth	80	3	13	Humerus	R	Max. diameter in the middle of the diaphysis	24
15	2	Femur	L	Mid-shaft sagittal diameter	26	3	13	Humerus	R	Min. diameter in the middle of the diaphysis	23
15	2	Femur	L	Mid-shaft transverse diameter	25	3	13	Humerus	R	Min. diaphyseal circumference	79
15	2	Femur	L	Mid-shaft circumference	90	3	13	Humerus	R	Max. transverse caput diameter	44
16	6	Femur	L	Mid-shaft sagittal diameter	30	3	13	Humerus	R	Max. sagittal caput diameter	49
16	6	Femur	L	Med-shaft transverse diameter	30	5	1	Humerus	R	Max. length	271
16	6	Femur	L	Mid-shaft transverse diameter	30	5	1	Humerus	R	Epicondylar breadth	48
16	6	Femur	L	Mid-shaft circumference	104	5	1	Humerus	R	Max. diameter in the middle of the diaphysis	19
17	7	Femur	R	Epicondylar breadth	63	5	1	Humerus	R	Min. diameter in the middle of the diaphysis	14
26	1	Femur	L	Upper transverse diaphyseal diameter	32*	5	1	Humerus	R	Min. diaphyseal circumference	64
26	1	Femur	L	Upper sagittal diaphyseal diameter	27*	5	1	Humerus	R	Max. transverse caput diameter	36
36	2	Femur	L	Mid-shaft sagittal diameter	29	5	1	Humerus	R	Max. sagittal caput diameter	38
36	2	Femur	L	Mid-shaft transverse diameter	25	8	4	Humerus	L	Max. transverse caput diameter	38

Seq. no.	Bone no.	Bone	Side	Measurement	mm	Seq. no.	Bone no.	Bone	Side	Measurement	mm
8	4	Humerus	L	Max. sagittal caput diameter	47	24	7	Humerus	L	Min. diameter in the middle of the diaphysis	18
9	22	Humerus	R	Max. length	295	24	7	Humerus	L	Min. diaphyseal circumference	79
9	22	Humerus	R	Max. diameter in the middle of the diaphysis	22	24	7	Humerus	L	Max. transverse caput diameter	45
9	22	Humerus	R	Min. diameter in the middle of the diaphysis	15	24	7	Humerus	L	Max. sagittal caput diameter	49
9	22	Humerus	R	Min. diaphyseal circumference	72	25	2	Humerus	R	Epicondylar breadth	61
9	22	Humerus	R	Max. transverse caput diameter	37	38	1	Humerus	R	Epicondylar breadth	57
9	22	Humerus	R	Max. sagittal caput diameter	36	44	–	Humerus	R	Epicondylar breadth	61
9	23	Humerus	L	Epicondylar breadth	50	44	–	Humerus	R	Max. sagittal caput diameter	46
10	17	Humerus	L	Max. length	312	1	3	Mandible	L/R	Bicondylar breadth (cdl) to (cdl)	120
10	17	Humerus	L	Epicondylar breadth	56	1	3	Mandible	L/R	Bigonial breadth (go) to (go)	106
10	17	Humerus	L	Max. diameter in the middle of the diaphysis	21	1	3	Mandible	L/R	Height (length) of ascending ramus (go) to condyl	63
10	17	Humerus	L	Min. diameter in the middle of the diaphysis	16	1	3	Mandible	L/R	Minimum breadth of ascending ramus	30
10	17	Humerus	L	Min. diaphyseal circumference	70	1	3	Mandible	L/R	Height of mandiblar symphysis (gn) to (id)	31
10	17	Humerus	L	Max. transverse caput diameter	38	9	1	Mandible	L/R	Height of mandiblar symphysis (gn) to (id)	26
10	17	Humerus	L	Max. sagittal caput diameter	40	10	1	Mandible	L/R	Bigonial breadth (go) to (go)	96
12	1	Humerus	R	Epicondylar breadth	64	10	1	Mandible	L/R	Height of mandiblar symphysis (gn) to (id)	39
14	3	Humerus	R	Epicondylar breadth	67	19	1	Mandible	L	Height (length) of ascending ramus (go) to condyl	54
20	1	Humerus	L	Maximum length	308	19	1	Mandible	L	Minimum breadth of ascending ramus	34
20	1	Humerus	L	Epicondylar breadth	62	22	1	Mandible	L/R	Bicondylar breadth (cdl) to (cdl)	116
20	1	Humerus	L	Max. diameter in the middle of the diaphysis	23	22	1	Mandible	L/R	Bigonial breadth (go) to (go)	94
20	1	Humerus	L	Min. diameter in the middle of the diaphysis	23	22	1	Mandible	L/R	Height (length) of ascending ramus (go) to condyl	46
20	1	Humerus		Min. diaphyseal circumference	79	22	1	Mandible	L/R	Minimum breadth of ascending ramus	30
20	1	Humerus	L	Max. transverse caput diameter	44	24	1	Mandible	L/R	Bicondylar breadth (cdl) to (cdl)	120
20	1	Humerus	L	Max. sagittal caput diameter	48	24	1	Mandible	L/R	Bigonial breadth (go) to (go)	117
21	7	Humerus	R	Max. transverse caput diameter	38	24	1	Mandible	L/R	Height (length) of ascending ramus (go) to condyl	64
21	7	Humerus	R	Max. sagittal caput diameter	43	24	1	Mandible	L/R	Minimum breadth of ascending ramus	33
24	7	Humerus	L	Max. length	337						
24	7	Humerus	L	Max. diameter in the middle of the diaphysis	21						

Seq. no.	Bone no.	Bone	Side	Measurement	mm	Seq. no.	Bone no.	Bone	Side	Measurement	mm
24	1	Mandible	L/R	Height of mandiblar symphysis (gn) to (id)	29	24	11	Radius	L	Max. length	262
32	1	Mandible	L/R	Height of mandiblar symphysis (gn) to (id)	27	24	11	Radius	L	Min. circumference	54
44	-	Mandible	L/R	Bicondylar breadth (cdl) to (cdl)	112	24	11	Radius	L	Transverse diameter of the shaft	16
44	-	Mandible	L/R	Height (length) of ascending ramus (go) to condyl	62	24	11	Radius	L	Sagittal diameter of the shaft	12
44	-	Mandible	L/R	Minimum breadth of ascending ramus	33	25	4	Radius	R	Transverse diameter of the capitulum	23
3	15	Radius	L	Max. length	224	26	4	Radius	L	Transverse diameter of the capitulum	23
3	15	Radius	L	Min. circumference	54	44	-	Radius	L	Max. length	240
3	15	Radius	L	Transverse diameter of the shaft	17	3	5	Scapula	L	Length of cavitas glenoidalis	42
3	15	Radius	L	Sagittal diameter of the shaft	12	5	4	Scapula	R	Length of cavitas glenoidalis	33
5	3	Radius	L	Max. length	199*	9	5	Scapula	R	Length of cavitas glenoidalis	36
5	3	Radius	L	Min. circumference	44*	10	6	Scapula	L	Length of cavitas glenoidalis	34
5	3	Radius	L	Transverse diameter of the shaft	13*	18	4	Scapula	R	Length of cavitas glenoidalis	42
5	3	Radius	L	Sagittal diameter of the shaft	10*	20	2	Scapula	L	Length of cavitas glenoidalis	41
6	3	Radius	R	Max. length	197	21	6	Scapula	R	Length of cavitas glenoidalis	35
6	3	Radius	R	Minimum circumference	45	24	3	Scapula	L	Length of cavitas glenoidalis	41
6	3	Radius	R	Transverse diameter of the capitulum	18	6	11	Tibia	L	Max. mid-shaft diameter	23
6	3	Radius	R	Transverse diameter of the shaft	13	6	11	Tibia	L	Transverse mid-shaft diameter	18
6	3	Radius	R	Sagittal diameter of the shaft	10	6	11	Tibia	L	Min. diaphyseal circumference	76
9	21	Radius	L	Max. length	216	17	1	Tibia	L	Max. mid-shaft diameter	25
9	21	Radius	L	Min. circumference	47	17	1	Tibia	L	Transverse mid-shaft diameter	19
9	21	Radius	L	Transverse diameter of the shaft	14	17	1	Tibia	L	Min. diaphyseal circumference	76
9	21	Radius	L	Sagittal diameter of the shaft	11	3	19	Ulna	L	Max. length	243
10	22	Radius	R	Max. length	226	6	1	Ulna	L	Max. length	230
10	22	Radius	R	Min. circumference	48	9	19	Ulna	L	Max. length	231
10	22	Radius	R	Transverse diameter of the capitulum	19	10	19	Ulna	L	Max. length	243
10	22	Radius	R	Transverse diameter of the shaft	16	24	8	Ulna	L	Max. length	280
10	22	Radius	R	Sagittal diameter of the shaft	11	42	12	Ulna	L	Max. length	232
						44	-	Ulna	L	Max. length	262

**Table 3.** Measurements of individual bones from adult skeletons. (\* = estimated size)

Seq. no.	Bone no.	Bone	Side	Measurement	mm
12	2	Humerus	L	Max. width of the epiphysis for the capitulum	14
28	1	Radius	R	Max. length without epiphyses	107
9	33	Tibia	L	Max. length without epiphyses	153
34	5	Coxae (ilium)	R	Max. width of ilium (ant./sup. spine – post./sup. spine)	95
34	3	Femur	L	Max. width of the greater trochanter	33
34	3	Femur	L	Max. diameter of the epiphysis for the head	35
34	4	Femur	L	Max. width of the distal epiphysis	67
34	2	Femur	R	Max. diameter of the epiphysis for the head	29
34	2	Femur	R	Max. width of the greater trochanter	25
35	1	Femur	L	Max. diameter of the epiphysis for the head	29
35	1	Femur	L	Max. width of the greater trochanter	25
38	2	Femur	R	Distal width of the distal epiphysis	68

*Table 4.* Measurements of individual bones from sub-adult skeletons.