


Progression of renal disease

pathogenetic aspects and treatment options

Sabine Leh



Dissertation for the degree philosophiae doctor (PhD)
at the University of Bergen

2011

Contents

Contents.....	2
Scientific environment	3
Acknowledgements	4
Abbreviations used.....	6
1. Introduction	7
1.1 Why is it important to study chronic renal failure?	7
1.2 Common final pathway to end stage renal disease	8
1.2.1 Pathogenesis of segmental sclerosis.....	8
1.3 Pathways from glomerular disease to tubular atrophy	10
1.3.1 Proteinuria hypothesis	10
1.3.2 Misdirected filtration hypothesis.....	11
1.3.3 Hypoxia hypothesis	11
1.4 Treatment options.....	12
1.4.1 Angiotensin receptor blockers.....	12
1.4.2 Tetradecylthioacetic acid TTA	13
1.4.3 Pirfenidone	14
2. Aims of the thesis.....	16
3. Material and methods.....	17
3.1 Experimental models.....	17
3.1.1 Spontaneously hypertensive rats (SHR).....	17
3.1.2 Two-kidney one-clip hypertension (2K1C).....	18
3.1.3 Anti-GBM GN.....	19
3.2 Collagen quantification with Sirius Red stain.....	20
4. List of publications.....	22
5. Main results	23
5.1 Paper I.....	23
5.2 Paper II	24
5.3 Paper III.....	24
5.4 Paper IV.....	25
5.5 Paper V	26
6. General discussion	27
6.1 Overload in the JMC of SHR	27
6.2 Fibrosis in the JMC of SHR	28
6.3 Tubular atrophy is a consequence of inactivity	29
6.4 Tubular atrophy because of inactivity might be a universal principle.....	32
6.5 TTA in 2K1C	34
6.6 Candesartan and pirfenidone in anti-GBM GN.....	34
6.7 The novel drugs TTA and pirfenidone in clinical studies	36
7. Conclusions	37
8. Errata.....	38
9. References	39


Scientific environment

The study was performed at the Renal Research Group, Institute of Medicine, University of Bergen.

Animal experiments were conducted at the Laboratory animal facility, University of Bergen.

Morphological investigations were carried out at the Department of Pathology, Haukeland University Hospital.

The work was funded by grants from the Western Norway Regional Health Authority and the Haukeland University Hospital Strategic Research Programme.



Acknowledgements

I cannot find words that adequately express my gratitude to my supervisor Professor Bjarne Iversen. He discovered and nourished my first research interests. Through all these years, he guided me and yet let me find my own way. His never-ending optimism, enthusiasm and encouragement were highly appreciated. I am grateful for more than a decade of excitement and joy in doing renal research. Bjarne did not live to see the fulfilment of this thesis; he passed away when I was writing the introduction and looking forward to discussing the draft with him. I miss him deeply, but I hope to see him once again and telling him how I coped.

I gratefully thank Bjørn Egil Vikse and Michael Hultström for stepping in as co-supervisors. I owe them my deepest respect for how bravely, professionally and quickly they managed this task.

I would like to thank Bendik Nordanger for cutting innumerable sections, Aud Strømme, Tina Straus Dahl, Kalairasy Kugarajh for wonderful histological stains, Nina Holmelid, Turid Gulbrandsen and Anne-Marie Austrheim for providing me with a deeper insight into the ultrastructure of the kidney, Edith Fick for magnificent immunostains, Heike Immervoll and Gerd Lilian Hallseth for sharing their experience in immunohistochemistry. I am most thankful to Hilda Andersen and Tor Stormark for their support at the animal facility.

My warmest gratitude goes to the co-authors of the papers in the thesis: Rolf Christiansen, Olav Tenstad, Øyvind Vaagnes, Terje Forslund, Oddrun Gudbrandsen, Liliana Bivol, Rolf Berge, Trude Skogstrand and Christian Rosenberger.

All members of the Renal Research Group have been an invaluable source of good advice and fruitful collaboration. I am very grateful for our Monday meetings during all these years, and would like to thank you most sincerely.

I derived much of my inspiration for doing research from discussions about renal biopsy findings. I am indebted to the physicians at the Section of Nephrology and the Department of Pathology at Haukeland University Hospital who participated in the renal biopsy meetings.

I am grateful to the former and present heads of the Department of Pathology and of the Gade Institute, especially Lisbet Sviland, who provided me with an excellent working environment and superb facilities such as the digital camera on my microscope and the image analysis programs on my computer.

My deepest gratitude goes to my family for their care and love. I wish to thank my husband Friedemann for sometimes letting me believe that research is the most important thing.

August 2011

Sabine Leh

Abbreviations used

AT1	angiotensin II type 1 receptor
anti-GBM GN	anti-glomerular basement membrane glomerulonephritis
Colla1	collagen-1-alpha-1
FSGS	focal and segmental glomerulosclerosis
GFR	glomerular filtration rate
JMC	juxtamedullary cortex
MMP	matrix metalloprotease
SHR	spontaneously hypertensive rats
TTA	tetradecylthioacetic acid
TIMP	tissue inhibitor of metalloprotease
2K1C	two kidney one clip
WKY	Wistar Kyoto rats

1. Introduction

1.1 Why is it important to study chronic renal failure?

When we wrote the first application for the thesis grant in 2004, the annual incidence of end-stage renal disease in Norway was 92,3 per million and the prevalence 641,4 per million. Incidence and prevalence have increased continuously since the start of registration in 1980, and the newest numbers from 2009 are 116 per million for annual incidence and 843 per million for prevalence¹ (Figure 1).

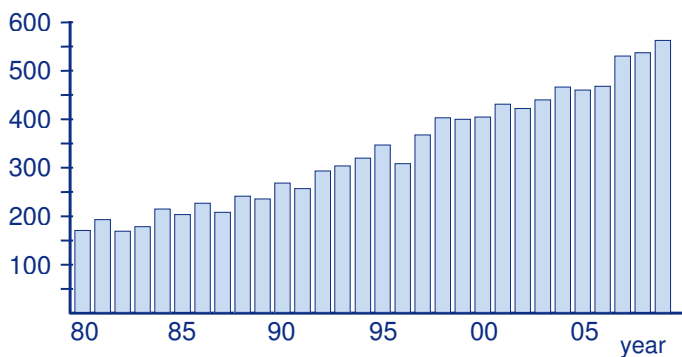


Figure 1: New patients in renal replacement therapy in Norway from 1980 - 2009¹

As the Norwegian population is expected to become older and more obese, the prevalence of renal risk factors are expected to increase, resulting in higher incidence and prevalence of end stage renal disease during the next decades.² Apart from the physical and psychological stress for the patient, the economic burdens of renal replacement therapy for the health care systems are huge. Considerable efforts have been undertaken to understand how and why chronic kidney failure develops, and to find drugs that prevent or slow-down this process. However, our understanding of renal disease progression is still limited in the majority of cases.

1.2 Common final pathway to end stage renal disease

Despite different underlying diseases, the degenerating process in the kidney seems to follow a similar morphological pattern, often referred to as the common final pathway of renal disease progression. The morphological hallmarks of this pathway are segmental and global glomerulosclerosis, tubular atrophy, and interstitial fibrosis (Figure 2).³

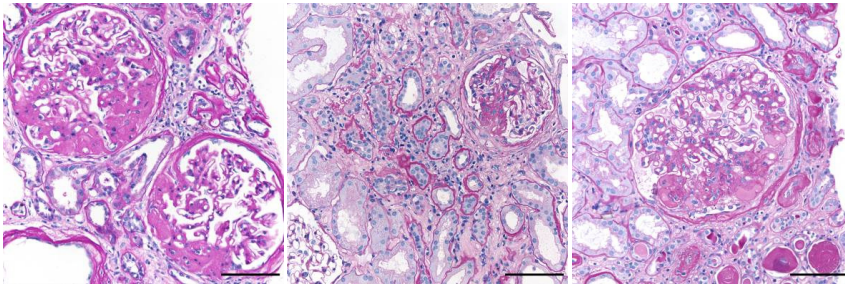


Figure 2: Morphological hallmarks of renal disease progression. Three different diseases (from left to right membranous nephropathy, crescentic glomerulonephritis, focal and segmental glomerulosclerosis) show uniform changes: segmental sclerosis, tubular atrophy, and interstitial fibrosis. Scale bar 100 μ m, periodic acid Schiff stain.

1.2.1 Pathogenesis of segmental sclerosis

The pathogenesis of segmental sclerosis is extensively described by Kriz in a series of papers in the 1990s.⁴⁻⁸ The initial event in the development of segmental sclerosis is thought to be damage to the glomerular epithelial cell, the podocyte.⁹ Damage may be caused by different agents (toxic, hemodynamic, inflammatory and immune-mediated). Damaged podocytes detach from the glomerular basement membrane, leaving bare areas. Capillary wall sections denuded of podocytes tend to become adherent to the Bowman's capsule. Segmental sclerosis develops from this adhesion through several processes, often occurring simultaneously:

- Damage spreads to neighbouring podocytes, initiating the described events repeatedly.

-
- Still open and perfused capillaries in an adhesion will have ongoing filtration. The filtrate is now directed to the Bowman's capsule and the interstitium behind, forming a paraglomerular space and enlarging the adherence.
 - Capillaries close to the adherence become narrowed by hyaline lesions or thrombosis, and eventually obliterate.
 - Cells disappear from the area and extracellular matrix increases.

A well-developed lesion of segmental sclerosis commonly shows obliteration of the capillary tuft, increased extracellular matrix and adherence with the Bowman's capsule. Usually, there is podocyte hypertrophy; often, absorption droplets and pseudocysts (syn. cytoplasmic vacuoles) are seen. Hyalinosis and endocapillary foam cells might be present. Electron microscopy shows variable podocyte foot process effacement, typically accompanied by prominent cytoskeleton along the glomerular basement membrane, increase of cellular organelles, and some degree of microvillous transformation.¹⁰

This glomerular lesion is morphologically well defined but entirely unspecific. It includes both primary (idiopathic) and secondary forms with known aetiology. The term used is focal and segmental glomerulosclerosis (FSGS). However, when FSGS is investigated in serial sections, it is often diffuse (present in more than 50% of glomeruli),^{11, 12} and in advanced cases, FSGS is no longer segmental either.

Secondary FSGS includes diverse diseases such as hereditary forms, drug associated diseases, viral infections, and glomerular scarring in various forms of chronic glomerulonephritis.

Finally, and most important in the context of the present thesis, secondary FSGS might develop as a consequence of altered glomerular hemodynamics with hyperperfusion and increased glomerular pressure in conditions like hypertension, obesity, diabetes, and considerable nephron loss due to any advanced renal disease. It is generally accepted that the common final pathway to end stage renal disease is based on this mechanism, also called the overload hypothesis. The hypothesis was first described 1981 in a milestone paper by Hostetter, Brenner et al¹³ studying the

remaining rat kidney after subtotal renal ablation. Substantial loss of kidney tissue leads to compensatory increase of single nephron glomerular filtration rate in the remaining glomeruli. To increase glomerular filtration rate, glomerular plasma flow and glomerular pressure have to be elevated. Altered hemodynamics give rise to podocyte changes: podocytes show absorption droplets, pseudocysts, effacement of foot processes, and microvillous transformation. As a consequence of glomerular hypertension, focal and segmental glomerulosclerosis develops, increases, and eventually proceeds to global glomerulosclerosis, leading to further nephron loss and continuing in a vicious circle.

1.3 Pathways from glomerular disease to tubular atrophy

It is still not well understood how the glomerular process is transmitted to tubules and interstitium, but several hypotheses have been put forward.

1.3.1 Proteinuria hypothesis

In proteinuric glomerular diseases tubules are chronically damaged by uptake of filtered protein.¹⁴

The filtration barrier is damaged in most glomerular diseases. Proteins that usually are not filtered then appear in the primary filtrate. These proteins are reabsorbed by the proximal tubules and degraded in lysosomes. The capacity for lysosomal protein degradation is limited. Lysosomes will eventually rupture and expose tubular cells to lysosomal enzymes. This triggers an inflammatory reaction with upregulation of inflammatory and vasoactive genes, finally leading to interstitial fibrosis and tubular atrophy.¹⁴

1.3.2 Misdirected filtration hypothesis

Misdirected filtration in areas of segmental glomerulosclerosis towards the Bowman's capsule, along the capsule to the tubular outlet, and downstream along the proximal tubule causes tubular atrophy.¹⁵

Areas with segmental sclerosis often contain open capillary loops. These capillaries are still perfused but miss the most important part of the filtration barrier, the podocyte. The capillaries filter, but the composition of the primary filtrate is changed, and the primary filtrate does not reach the Bowman's room but is led to a paraglomerular space. Ongoing filtration will expand this space and extend it further along the Bowman's capsule via the tubular origin to the proximal tubule. From there, the misdirected filtrate spreads downstream along the course of the proximal tubule, expanding the space between the tubular cells and the tubular basement membrane, eventually leading to tubular degeneration (Figure 3).^{16, 17}

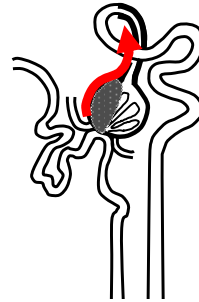


Figure 3: Schematic drawing to illustrate the misfiltration hypothesis. There is a misdirected filtrate from the area of segmental sclerosis along the Bowman's capsule to the proximal tubule (red arrow).

1.3.3 Hypoxia hypothesis

Impairment of blood flow to the tubulointerstitial compartment causes ischemic damage of the tubules. Chronic ischemia leads to tubular atrophy and interstitial fibrosis.¹⁸

The vascular organisation of the kidney is exceptional as two capillary beds are connected in series. There are only two other systems in the human body that include two successive capillary beds: the hypophyseal portal system connecting hypothalamus and pituitary, and the hepatic portal system connecting the capillary plexus in the intestine via the vena portae with the sinusoids in the liver. The first

capillary bed in the kidney is the glomerulus supplied by the afferent arteriole. The efferent arteriole connects the glomerulus to the second capillary bed, the peritubular capillaries, providing the tubules with oxygen and nutrients. Blood flow impairment to the tubulointerstitial compartment could occur through several mechanisms: constriction of the afferent arteriole, obliteration of the glomerular capillaries, for example through segmental sclerosis, or loss of peritubular capillaries (Figure 4).^{19, 20} Hypoxia has been shown to be associated with upregulation of pro-inflammatory and pro-fibrotic mediators,

and this would cause tubular atrophy and interstitial fibrosis. When fibrosis develops, extension of the diffusion distance from the capillaries to the tubules cell will further diminish oxygen supply.

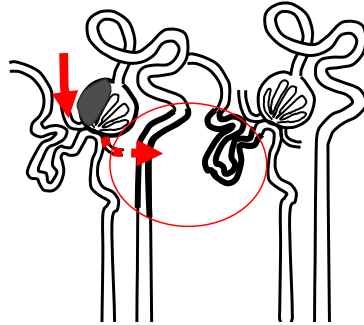


Figure 4: Schematic drawing to illustrate the hypoxia hypothesis. Due to segmental sclerosis there is reduced outflow from the glomerulus and hypoperfusion of the peritubular capillaries. Tubular segments from several nephrons develop atrophy.

1.4 Treatment options

1.4.1 Angiotensin receptor blockers

The introduction of drugs interfering with the renin angiotensin system has been a breakthrough in the treatment of renal diseases. The stabilisation of the previously strongly increasing incidence rate of end stage renal disease in the USA during the last 5-10 years has been at least partially ascribed to the introduction of these drugs.

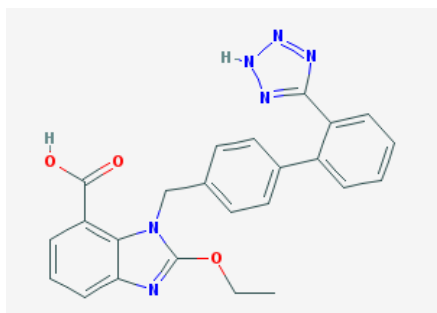


Figure 5: Chemical structure of candesartan ²¹

Angiotensin receptor blockers (examples include losartan and candesartan, Figure 5) inhibit the effects of the renin angiotensin system by blocking its angiotensin II type 1 (AT1) receptor, and the angiotensin convertase inhibitors (for example captopril and enalapril) by reducing the production of angiotensin II. The renoprotective effects of these drugs are based on their ability to reduce systemic blood pressure, to normalize glomerular pressure by dilatation of the efferent arteriole²², and to inhibit the non-hemodynamic profibrotic effects of angiotensin II.²³

However Angiotensin converting enzyme inhibitors or AT1 receptor blockers are mostly not capable to halt or even reverse the atrophy process, and other treatment options are badly needed.

In this thesis we have focused on 2 novel drugs that could have renoprotective effects.

1.4.2 Tetradecylthioacetic acid TTA

Tetradecylthioacetic acid (TTA) is a saturated straight-chain thia fatty acid with a backbone of 14 carbon atoms and a sulfur atom inserted into the 3-position (Figure 6).

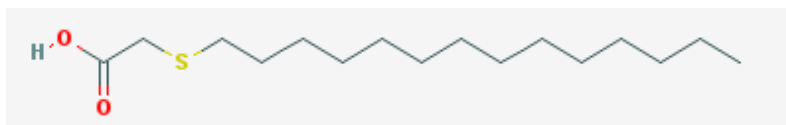


Figure 6: Chemical structure of tetradecylthioacetic acid (TTA) ^{24, 25}

TTA increases both cellular uptake and oxidation of fatty acids by proliferation of mitochondria. These effects are partly ascribed to activation of PPAR alpha by TTA. TTA can thus decrease free fatty acid content in the serum and change the serum composition of fatty acids. Decreased free fatty acid concentration in the serum facilitates glucose uptake in muscle and adipose tissues, and has thus a beneficial effect on insulin sensitivity.^{26, 27} Hypertension is both a component of chronic renal disease and metabolic syndrome, and alteration of lipid profiles in the serum has an impact on blood pressure levels.^{28, 29} In addition, dyslipidemia worsens renal insufficiency.³⁰ Other PPAR agonists interact with the renin angiotensin system, and this could also have a blood-pressure reducing effect.³¹ We therefore hypothesised that TTA might reduce hypertension and morphological damage in chronic hypertensive kidney disease.

1.4.3 Pirfenidone

Tubular atrophy and interstitial fibrosis in advanced renal disease are well correlated with kidney function measured by serum creatinine.^{32, 33} Antifibrotic drugs might therefore have a renoprotective potential.

Pirfenidone is a new antifibrotic drug (Figure 7). The antifibrotic effect of pirfenidone was first described in bleomycin induced lung fibrosis in the hamster.³⁴ Subsequently, the drug was tested in animal models of fibrosis in different organs.³⁵⁻⁴³

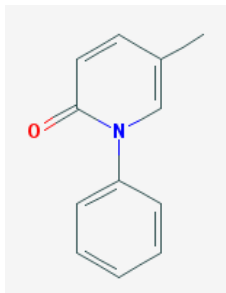


Figure 7: Chemical structure of pirfenidone⁴⁴

Pirfenidone has been tested in several models of kidney disease: anti-Thy-1 glomerulonephritis,⁴⁵ unilateral ureteral obstruction,⁴⁶ subtotal nephrectomy,⁴⁷ streptozotocin diabetes,⁴⁸ cyclosporine toxicity,⁴⁹ vanadate⁵⁰ and doxorubicin induced kidney fibrosis.⁵¹ These studies confirmed the antifibrotic effect of pirfenidone in various kidney diseases, but its mechanism of action is not well understood. It has however been shown that pirfenidone reduces transforming growth factor beta production and that this is associated with reduced collagen production.⁵² Furthermore, pirfenidone decreases oxidative stress^{51,52} and has anti-inflammatory properties.⁵³⁻⁵⁵

2. Aims of the thesis

To study the pathogenesis of chronic glomerular damage, tubular atrophy, and interstitial fibrosis in a rat model of hypertensive renal damage.

- to describe the morphological changes
- to understand the development of interstitial fibrosis
- to test common hypotheses regarding development of tubular atrophy

To study the effect of potential renoprotective drugs in a rat model of hypertensive renal damage and in a rat model of chronic glomerulonephritis.

- Tetradecylthioacetic acid in two kidney one clip (2K1C) hypertension
- Pirfenidone in anti-glomerular basement membrane glomerulonephritis (anti-GBM GN)

3. Material and methods

This chapter contains only methods that are not described in detail in the material and methods sections of the respective papers.

3.1 Experimental models

3.1.1 Spontaneously hypertensive rats (SHR)

The spontaneously hypertensive rat was developed by inbreeding of Wistar Kyoto rats with high blood pressure^{56,57} and is now one of the most studied animal models for genetic hypertension.⁵⁸

Measured by a vascular cast model, the lumen diameter of the afferent arteriole in SHR is reduced compared to Wistar Kyoto rats (WKY), and this is so already in the prehypertensive state.^{59,60} Reduced lumen diameter is not caused by media hypertrophy in young SHR.⁶¹ Reduced lumen diameter increases the vascular resistance in the kidney and in order to maintain renal blood flow and glomerular filtration rate, arterial pressure has to be raised. Reduced lumen diameter may thus contribute to development of systemic hypertension in this rat strain.⁶²

Glomerular capillary pressure increases with age in the juxtamedullary cortex (JMC) accompanied by increased glomerular tuft diameter.⁶³ Increased glomerular capillary pressure is considered an important mechanism for development of segmental glomerulosclerosis.¹³ Chronic glomerular and tubulointerstitial damage starts in the JMC, is present from about 40 weeks of age, and increases with higher age.^{63,64}

An overview of physiological and morphological parameters is shown in figure 8.

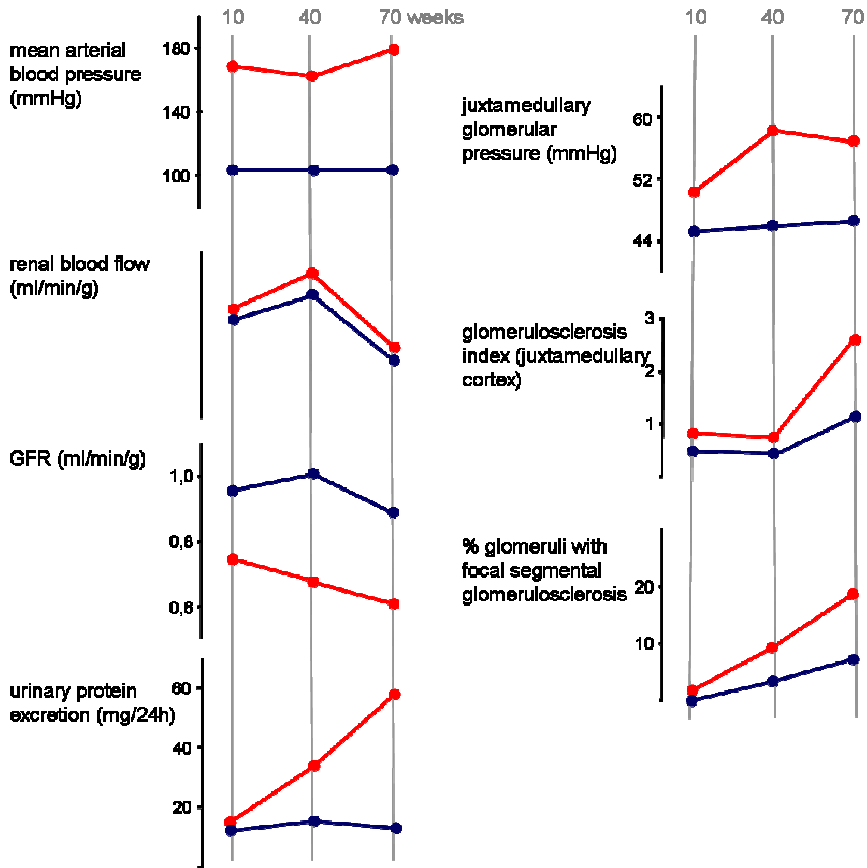


Figure 8: Hemodynamic and morphological parameters in WKY (blue) and SHR (red) at various ages⁶⁵

3.1.2 Two-kidney one-clip hypertension (2K1C)

The model was first described by Goldblatt in 1934, who induced hypertension in dogs by constricting the renal arteries.⁶⁶

A clip around the left renal artery causes reduced perfusion of the left kidney (Figure 9) inducing increased renin secretion. Thereafter, the angiotensin II level rises, and mainly due to its vasoconstrictory effect blood pressure increases rapidly.⁶⁷ The non-clipped kidney is exposed to elevated blood pressure, and morphological signs of

hypertensive damage develop about 20 weeks after clipping. In paper IV, we studied the kidney 24 weeks after surgery when damage was well established.

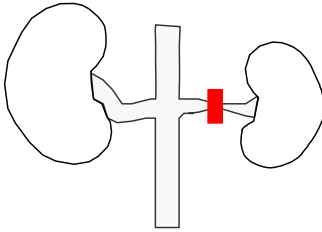


Figure 9: 2K1C hypertension. A clip around the left renal artery leads to reduced perfusion of the left kidney and to compensatory hypertrophy of the right kidney.

3.1.3 Anti-GBM GN

Rabbits were sensitised by a purified preparation from glomerular basement membranes from rats. Samples of venous blood were taken from rabbits every 3-4 weeks. Serum was separated by centrifugation and stored. Glomerulonephritis was induced by a single dose of pooled serum intravenously.⁶⁸ Rabbit anti-GBM antibodies bind to glomerular basement membranes (heterologous phase).

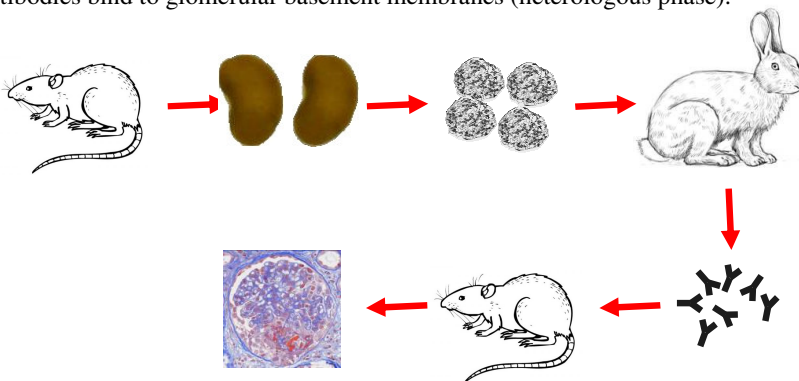


Figure 10: Schematic drawing to show the sensitisation of rabbits by a purified suspension of glomerular basement membranes from rats. Rabbit serum is so injected in rats and induces a crescentic GN.

Subsequently, rat antibodies react with rabbit antibodies fixed to the basement membrane (autologous phase). A glomerulonephritis develops with necrosis and

crescents in the acute phase and segmental sclerosis, tubular atrophy and interstitial fibrosis in the chronic phase (Figure 10).

3.2 Collagen quantification with Sirius Red stain

Sirius Red stain is specific for collagens.^{69, 70} The natural birefringence of interstitial collagens is enhanced by Sirius Red and makes the stain particularly suitable for quantification by image analysis. The amount of birefringence is dependent on staining conditions and section thickness.⁷¹ The use of tissue macroarray paraffin blocks containing kidney tissue from all rats, ensured minimal variation regarding section thickness and staining quality (Figure 11).



Figure 11: tissue macroarray block (left) and section stained with Sirius Red (centre). The label (right) identifies the coded tissue pieces. + designates a piece of liver tissue for proper orientation.

Sections with five μm thickness were stained in 1% Sirius Red F3B in a saturated solution of picric acid for one hour, rapidly dehydrated in graded alcohols, cleared, and mounted. The sections were investigated under polarized light in a Leica DMLB microscope connected to a CCD ColorView IIIu camera. For image acquisition Olympus DP-soft 5.0 software was used. Colour images from outer cortex and JMC were obtained by taking consecutive samples parallel to the kidney capsule and to the corticomedullary border. Seven images from outer and five images from juxtamedullary cortex were analysed per rat. Images were acquired with a 20x

objective under constant identical illumination and polarisation settings. An online shading correction was performed. An image resolution of 480 x 480 pixels was chosen, corresponding to an area of 477 x 477 μm and a resolution of 0,99 $\mu\text{m}^2/\text{pixel}$. Images were stored as TIFF (tagged image file format). For automatic image analysis analySISD 5.0 software was used. The HSI (hue, saturation, intensity) colour space was used, and the image was separated into the hue component resulting in a 256 grey scale image. Lower and upper thresholds for recognition of birefringent collagen were set on the grey scale image. The same thresholds were used for all images. Collagen content was expressed as per cent detected area. The investigation was done blindly on coded sections (Figure 12).

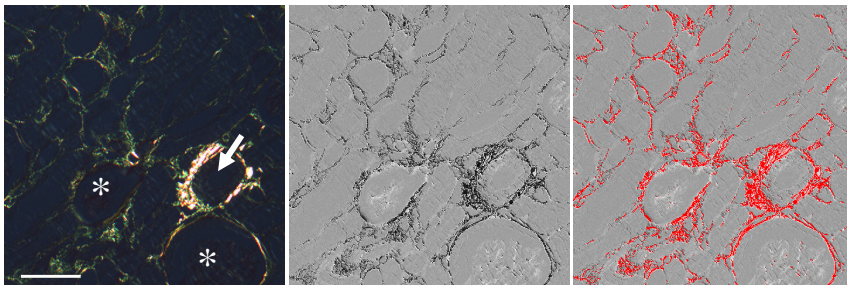


Figure 12: JMC of SHR with one artery (arrow) and two glomeruli (*). The left image is taken under polarized light. The image in the centre is a grey scale image after separation with the hue component. The image to the right shows the detected area (red) after setting an appropriate threshold. Scale bar 100 μm , Sirius red stain.

4. List of publications

Paper I

Christiansen RE, Tenstad O, Leh S, Iversen BM. Glomerular charge selectivity is impaired in hypertensive nephropathy. *Nephrol Dial Transplant* 2004; 19: 1083-1091

Paper II

Hultström M, Leh S, Skogstrand T, Iversen BM. Upregulation of Tissue Inhibitor of Metalloproteases-1 (TIMP-1) and Procollagen-N-Peptidase in Hypertension-Induced Renal Damage. *Nephrol Dial Transplant* 2008; 23: 896-903

Paper III

Leh S, Hultström M, Rosenberger C, Iversen BM. Afferent arteriolopathy and glomerular collapse but not segmental sclerosis induce tubular atrophy in old spontaneously hypertensive rats. *Virchows Arch* 2011; 459: 99-108

Paper IV

Gudbrandsen OA, Hultström M, Leh S, Monica Bivol L, Vågnes Ø, Berge RK, Iversen BM. Prevention of hypertension and organ damage in 2-kidney, 1-clip rats by tetradecylthioacetic acid. *Hypertension* 2006; 48: 460-466

Paper V

Leh S, Vågnes Ø, Margolin SB, Iversen BM, Forslund T. Pirfenidone and candesartan ameliorate morphological damage in mild chronic anti-GBM nephritis in rats. *Nephrol Dial Transplant* 2005; 20: 71-82

5. Main results

The first three papers describe chronic hypertensive nephropathy in a rat model of genetic hypertension, the spontaneously hypertensive rat (SHR). The papers describe the pattern of kidney damage, mechanisms behind interstitial fibrosis, and conclude in the end that tubular atrophy is caused by reduced urinary flow induced by afferent arteriopathy and glomerular collapse.

Paper IV and V describe the effect of treatment in two different rat models, the chronic 2K1C hypertensive rat, and a rat model of chronic glomerulonephritis. Both models develop kidney damage in a considerable shorter time than SHR and are suitable for testing the effect of renoprotective drugs.

5.1 Paper I

Glomerular charge selectivity is impaired in hypertensive nephropathy.

The study investigated the mechanism of proteinuria and described the associated morphological changes in 80-week-old SHR. A disturbance of the glomerular filtration barrier with loss of negative charges in the JMC was demonstrated by the increased sieving coefficient of anionic chymotrypsinogen compared to the sieving coefficient of neutral chymotrypsinogen and compared to WKY. Morphological parameters of a distorted glomerular filter were absorption droplets in podocytes and effacement of foot processes, while podocyte pseudocysts indicated more advanced podocyte damage. In the JMC of SHR an increased number of glomeruli with absorption droplets in podocytes was found by light microscopy and effacement of foot processes as well as pseudocysts demonstrated by electron microscopy. Adherences of the glomerular tuft to Bowman's capsule, a consequence of podocyte damage, were abundant. Glomerular changes were accompanied by increased tubulointerstitial damage in the JMC of SHR.

5.2 Paper II

Upregulation of tissue inhibitor of metalloproteases-1 (TIMP-1) and procollagen-N-peptidase in hypertension-induced renal damage.

The pattern of interstitial fibrosis and some of the mechanisms behind collagen deposition were investigated in 60-week-old spontaneously hypertensive rats.

Both vascular, glomerular and tubulointerstitial changes were mainly present in the JMC of SHR. Arteries and arterioles showed muscular wall hypertrophy and intima thickening. There were glomerular collapse and glomerular segmental sclerosis.

Tubular atrophy and interstitial fibrosis were still focal. Quantification of collagen with Sirius red stain and image analysis showed significantly increased amount in the JMC of SHR compared with outer cortex of SHR and compared with JMC of the control group WKY.

Increased collagen deposition was a consequence of increased collagen production as shown by increased mRNA expression for collagen-1-alpha-1 (col1a1) and for procollagen-n-peptidase. Collagen content was further modified by disturbed collagen metabolism. mRNA expression of the collagen digesting proteins matrix metalloprotease (MMP) 2 and 9 and the tissue inhibitors of metalloproteases (TIMP) 1 and 2 were increased in SHR compared to WKY. TIMP-1 followed closely the expression pattern of col1a1 at the mRNA and protein level and might therefore be of particular importance. Interstitial fibrosis in SHR is thus a consequence of increased collagen production, increased collagen deposition and disturbed collagen breakdown.

5.3 Paper III

Afferent arteriopathy and glomerular collapse but not segmental sclerosis induce tubular atrophy in old spontaneously hypertensive rats.

The relationship between morphological changes of afferent arteriole, glomerulus and proximal tubule were studied in 60-week-old SHR by serial sections.

Only nephrons with glomerular collapse showed both tubular atrophy and an increased wall hypertrophy of the afferent arteriole. Nephrons with glomerular segmental sclerosis did not show tubular atrophy. Afferent arteriolar diameter negatively correlated with glomerular capillary volume fraction and tubular diameter, implying reduced glomerular and tubular flow. Tubular cells are ciliated. Bending of cilia by urine flow induces an increase of inversin positivity in tubular cells. Degenerating and atrophic tubules showed reduced inversin positivity indicating changed ciliary signalling due to reduced urinary flow. We concluded that nephron loss in SHR is initiated by afferent arteriolopathy, leading to glomerular collapse and reduced urinary flow with subsequent tubular atrophy.

5.4 Paper IV

Prevention of hypertension and organ damage in 2-kidney 1-clip rats by tetradecylthioacetic acid.

Dietary lipids affect blood pressure. 2K1C hypertensive rats were treated with the modified fatty acid tetradecylthioacetic acid (TTA). TTA reduced blood pressure both when given immediately after clipping and when treatment started with a delay of five weeks. There was no proteinuria in treated animals six months after clipping. Kidney damage, measured by podocyte changes, segmental and global glomerulosclerosis, and a tubulointerstitial damage score, was greatly reduced.

The effect of TTA is explained by interference with the renin angiotensin system, which we confirmed by showing that renin production in the clipped kidney was decreased, and that plasma renin activity and angiotensinogen production in the adipose tissue were reduced. Furthermore, TTA altered the composition of serum fatty acids, resulting in an increase of oleic acid, which has a blood pressure lowering effect. Finally, the urinary excretion of the potent vasoconstrictor 8-iso-prostaglandin F₂ was reduced. Kidney damage in this study thus seemed to be prevented mainly by the blood pressure lowering effects of TTA.

5.5 Paper V

Pirfenidone and candesartan ameliorate morphologic damage in mild chronic anti-GBM nephritis in rats.

The renoprotective effect of inhibitors of the renin angiotensin system is well known. Pirfenidone is a new drug with antifibrotic properties. The effect of pirfenidone was compared to the angiotensin II type I receptor antagonist candesartan, and a combination of both drugs was tested in chronic anti-GBM GN. Absorption droplets in podocytes indicated a defect in the filtration barrier, and the percentage of glomeruli with absorption droplets was well correlated with the amount of proteinuria. Both pirfenidone and candesartan reduced the number of glomeruli with absorption droplets in podocytes and decreased proteinuria. Tubular degeneration and cortical col1a1 expression were reduced by both drugs. There was no difference regarding the various parameters between pirfenidone and candesartan, underlining the renoprotective potential of pirfenidone. The more consistent pattern of beneficial effects on morphological damage shown by candesartan treatment however suggested a slightly better beneficial effect. Combination therapy was superior to candesartan monotherapy regarding reduction of blood pressure after 3 weeks as well as reduction of percentage glomeruli with absorption droplets.

6. General discussion

In the first part, the morphological damage pattern in the JMC of SHR is discussed, and it will be argued that tubular atrophy is a consequence of reduced flow due to glomerular hypoperfusion and hypertrophy of the afferent arteriole.

The second part discusses the renoprotective effects of TTA, candesartan and pirfenidone.

6.1 Overload in the JMC of SHR

Papers I – III studied pathogenetic aspects of nephron loss in a rat model of chronic hypertension, commonly accepted as a model for essential hypertension in man. The glomerular findings in paper I fit nicely with the description of glomerular damage caused by overload in Hostetter and Brenner's milestone paper.¹³ The overload in old SHR, the increased glomerular pressure in the JMC, is a consequence of systemic hypertension and loss of autoregulation. Afferent arterioles in JMC originate either from the initial parts of the interlobular arteries, where the autoregulatory capacity of the interlobular arteries still is limited,⁷² or directly from the arcuate arteries.^{73, 74} These arterioles are therefore particularly exposed to increased arterial pressure. Chronically elevated arterial pressure impairs autoregulation,⁷⁵ and the glomerular capillary pressure rises. Moreover, the buffering of pressure variations is impaired in the JMC.⁷⁶ Increased glomerular pressure is associated with glomerular hypertrophy (paper III) and leads at first to adaptive podocyte hypertrophy and then to maladaptive changes⁴ such as pseudocyst formation and footprocess effacement. Podocytes might even detach from the basement membrane and can be detected in the urine.⁷⁷ Podocytes form the smallest pores of the glomerular filtration barrier, the filtration slits with the diaphragm, and contribute with their negative charges to its charge selectivity. It is conceivable that podocyte damage and even more podocyte loss will have an impact on the filtration barrier. This is easily verified by the amount of albuminuria and proteinuria in old SHR. Two findings in paper I support that the

filtration defect indeed is localised to the juxtamedullary glomeruli. Firstly, increased filtration of the anionic peptide chymotrypsinogen is only found in the JMC of SHR. Secondly, podocytes with absorption droplets are predominantly present in the JMC. Absorption droplets are reabsorbed proteins that leak through the glomerular filter.^{7,9}

6.2 Fibrosis in the JMC of SHR

The common final pathway in renal disease progression encompasses not only segmental glomerulosclerosis but also tubular atrophy and interstitial fibrosis. Both are found together with the glomerular changes in the JMC of SHR.

Collagen fibers are the hallmark of fibrosis. Fibrous collagen can be visualised in histological sections by histochemical stains or by immunohistochemistry. Sirius Red specifically visualizes fibrillar collagens under polarised light and has been used widely for quantitative assessment of collagen content. It has been questioned whether the Sirius Red stain truly is quantitative.⁷⁸ However, the amount of hydroxyprolin content compared with morphometry of Sirius Red stained sections revealed a highly significant correlation,⁷⁹ indicating that Sirius Red stain combined with polarisation and automatic image analysis indeed is a solid tool for estimation of collagen content. The method shows excellent interobserver agreement.⁸⁰ Lately, the clinical significance of the method has been doubted, because it has been shown in transplant kidney biopsies, that visual assessment of the fibrotic area was better correlated with serum creatinine and glomerular filtration rate (GFR) than Sirius Red using polarisation and image analysis.⁸¹ In this respect, it should be noted that visual assessment will interpret the entire interstitial area as fibrotic since it is done with low magnification for good overview. Interstitium as a whole is well correlated with serum creatinine and GFR; it consists not only of collagen but a multitude of proteins and tissue fluid, which as well might increase under pathological conditions. Therefore, the superior correlation of visual assessment with serum creatinine and GFR is not surprising. However, the result of visual assessment might be rather a parameter for interstitial area than a measure for fibrillar collagen.

In old SHR both GFR (paper I) and fibrillar collagen (paper II) are increased in the JMC. Furthermore, it was shown that increased collagen deposition is not only a consequence of increased collagen production but also a consequence of disturbed metabolism (Paper II).

6.3 Tubular atrophy is a consequence of inactivity

The morphological hallmarks of the common final pathway – segmental glomerulosclerosis, tubular atrophy and interstitial fibrosis - are present in the JMC of SHR. However, their interrelation and the significance of vascular changes remained unclear. By means of morphology these questions could only be answered by visualising single nephrons and their supplying arterioles. Paper III investigated the matter by serial sectioning.

It was shown that collapsed glomeruli without signs of segmental sclerosis were connected to atrophic tubules. These collapsed glomeruli were supplied by arterioles with significant media hypertrophy. The conclusion, drawn from these observations, is that nephrons in the JMC of SHR atrophy because of tubular inactivity, since glomerular blood flow and in consequence tubular urine flow were reduced by hypertrophy of afferent arterioles (Figure 13).

This conclusion seems at first glance to be in contrast to some of our previous findings. Micropuncture studies in 70-week-old SHR showed increased mean glomerular pressure in the juxtamedullary glomeruli compared to WKY.⁶³ Looking at the distribution of measured glomerular pressures in that previous study, all but one or two juxtamedullary SHR glomeruli had higher pressures than the WKY glomeruli, and no SHR glomerulus had a lower pressure than the lowest pressure of the WKY glomeruli. In contrast to this 4 of 28 glomeruli in 2 representative areas of the kidney cortex were collapsed (paper III), implying that there has to be a subset of glomeruli with reduced glomerular pressure.

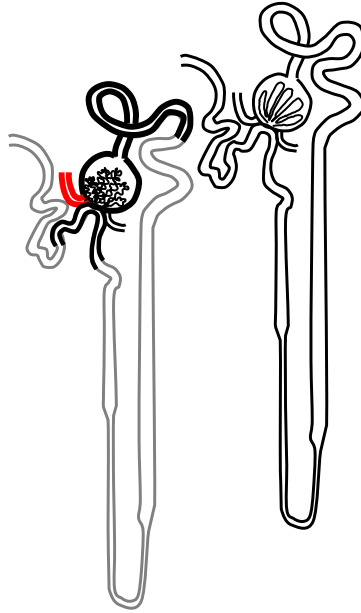


Figure 13: Schematic diagram to show the morphologic changes in a degenerating nephron in the JMC of SHR compared to a normal nephron (right). The hypertrophied afferent arteriole is red, the glomerular convolute retracted and collapsed and tubular atrophy is indicated by thickened black lines. Not investigated parts of the nephron are depicted grey.

The most probable reason that these glomeruli are not found by micropuncture is that the reduced perfusion makes them difficult to puncture and to identify by their pressure profile. Moreover, collapsed glomeruli show a thickened and multilayered Bowman's capsule and the periglomerular tissue usually is inflamed and fibrotic, which might make them even harder to puncture. They might therefore have escaped the investigation procedure for glomerular intracapillary pressure.

In addition, the rats in the previous investigation are 10 weeks older than the rats in paper III. The fraction of glomeruli with elevated intracapillary pressure might have increased in this time period along with the morphological signs of hypertensive renal damage, while insufficient perfusion of glomeruli might have become less important as cause for nephron loss.⁸² This explanation is supported by the fact, that glomeruli

with segmental sclerosis in the 60-week-old SHR were, unlike collapsed glomeruli, not a frequent finding. That segmental sclerosis increases in higher age is further supported by the fact that about 30% of juxtaglomerular glomeruli of the 80-week-old rats (paper I) showed adherences. An adhesion is considered the focus where segmental sclerosis starts.⁴

Our initial assumption was that tubular atrophy is linked to segmental sclerosis, either by reduction of the blood supply to the tubulointerstitial compartment leading to hypoxia, or by misdirected filtration towards and along the Bowman's capsule and along the proximal tubule.

If the misfiltration hypothesis were true, then segmental sclerosis and tubular atrophy would have to be present in the same nephron.¹⁷ Since glomeruli with segmental sclerosis were not connected to atrophic tubules, this hypothesis has to be rejected for this stage of renal disease progression in SHR. Apart from that, the misfiltration hypothesis and our findings of tubular atrophy because of reduced tubular flow are not mutually exclusive. It is conceivable, that a misdirected filtrate, which spreads along the Bowman's capsule to the tubular outlet and the initial parts of the proximal tubule, might expand and then compress the tubular orifice, thus stopping tubular flow. Some of the illustrations in related publications are consistent with this mechanism.^{15, 83}

That tubular atrophy and glomerular damage were confined to the same nephron, and that nephrons with tubular atrophy were found in close proximity to preserved nephrons, argues strongly against the hypoxia hypothesis. If the assumption is true that reduced glomerular outflow causes tubular atrophy because of reduced oxygen supply, zonal atrophy affecting several nephrons in close proximity has to be expected.¹⁶ In agreement with our observation, a recent *in vivo* study in 2K1C rats provided further evidence that hypoxia is not the cause of tubular atrophy when the blood flow is chronically reduced. Despite significant reduction of renal blood flow, the renal oxygen content in the clipped kidney did not diminish but rather showed a tendency to increase during the study period of 28 days.⁸⁴

Our study was not designed to test the proteinuria hypothesis specifically. However, there are observations arguing against proteinuria as cause of tubular atrophy. That absorption droplets in podocytes identify nephrons that leak protein, is supported by two observations in our studies. Firstly, there is a close correlation between percentage of glomeruli with absorption droplets in podocytes and amount of proteinuria (paper V). Secondly, glomeruli with absorption droplets were found in the JMC in SHR (paper I), where proteinuria in SHR originates.⁸⁵ Serial sections in SHR showed that 8 of altogether 64 nephrons contained glomeruli with absorption droplets in podocytes, and these glomeruli were connected to normal tubules. Vice versa, 13 nephrons showed atrophic tubules and none of the parent glomeruli did contain podocytes with absorption droplets (unpublished observation, Sabine Leh). In 60-week-old SHR, there was thus morphologically no evidence that nephrons with proteinuria develop tubular atrophy.

6.4 Tubular atrophy because of inactivity might be a universal principle

Inactivity is a well known cause for atrophy.⁸⁶ Reduced flow is equivalent to reduced activity, and tubular atrophy because of inactivity may be a mechanism in renal disease progression. At the pre-tubular level, flow can be reduced by hypoperfusion, as we argue in the SHR, by damage to the glomerular filter or by obstruction of the tubular outlet. There are several examples of how tubular flow might be reduced in other models of kidney disease, and where this is directly connected to tubular atrophy.

In a rat model of puromycin nephrosis, a subset of glomeruli was small and connected to atrophic tubules 10 weeks after induction.⁸⁷ Impairment of the glomerular filter by reduced filtration coefficient might have contributed to the tubular degeneration.⁸⁸ Both mechanisms – hypoperfusion and obstruction of the tubular outlet – have been described in a rat model of mesangioproliferative glomerulonephritis with crescents.⁸⁹ Two subsets of glomeruli were connected to atrophic or degenerating tubules: a

subset of small glomeruli with collapse of the capillary convolute and another subset of glomeruli with crescents that covered the tubular orifice. The pathogenetic mechanism of atrophy by obstruction of the tubular outlet has also been shown in a study of murine anti-GBM GN. In that study only nephrons with glomerular crescents obstructing the tubular outlet showed tubular degeneration.⁹⁰

In a study of uninephrectomy in rats treated with desoxycorticosterone-trimethylacetate to produce hypertension, there was a subset of small shrunken glomeruli supplied by afferent arterioles with obstructive lesions,⁵ a finding that corresponds to our findings in paper III.

A morphological study of tubular and glomerular pathology in subtotal nephrectomy⁹¹ presented a number of observations that fit well with the concept of reduced tubular flow as reason for tubular atrophy. The degree of segmental sclerosis in individual glomeruli was well correlated with the degree of atrophy of the corresponding tubules, which is compatible with reduced single nephron GFR as the link between glomerular and tubular changes. Moreover, the volumes of glomeruli connected to atrophic tubules were significantly lower compared to glomeruli connected to normal tubules, an observation compatible with reduced glomerular perfusion and subsequent reduced tubular flow.

We have argued that reduced tubular flow induces tubular atrophy in 60-week-old SHR, and that this mechanism may be common in renal disease progression in a variety of renal diseases. This raised the question how reduced tubular flow could be visualised in histological sections.

Tubular cells contain primary cilia,⁹² which act as mechanosensors for tubular flow.⁹³⁻⁹⁵ Ciliary function has been widely studied in developmental diseases of mutated proteins connected to cilia, so called ciliopathies.⁹⁶ Inversin is a ciliary protein, whose mutation causes nephronophthisis type 2.⁹⁷ Inversin might be present in different subcellular localisations.^{98,99} It has been shown that bending of cilia by flow increases inversin positivity.¹⁰⁰ In SHR, degenerating tubules still have cilia, but compared to preserved tubules, they do not show apical cytoplasmic and nuclear positivity for inversin. We assume that absent inversin positivity is caused by reduced bending of

cilia due to reduced flow (paper III). Changes in length and number of tubular cilia have been shown in studies of acute renal failure, reperfusion injury and unilateral ureteral obstruction,¹⁰¹⁻¹⁰³ but the function of cilia in acute and chronic kidney diseases is largely unknown. It can be deduced from studies in developmental diseases that cilia, by mechanosensation, may play an important role in regulation of epithelial cell differentiation. Further studies are needed to learn more about the role of ciliary signalling in the development of chronic kidney disease.

6.5 TTA in 2K1C

The main result in paper IV was the favourable effect of TTA on hypertension and hypertension induced renal damage. Even if the cause of hypertension is different in SHR and 2K1C, the pathogenetic mechanism of renal disease progression might be largely the same. As in SHR, morphological damage is more prominent in the JMC.¹⁰⁴ Arteries and arterioles show wall hypertrophy, endothelial cell proliferation and fibrinoid wall necrosis. It is conceivable that both glomerular hypoperfusion due to lumen obstruction and hyperperfusion due to loss of autoregulation might ensue. Hyperperfusion changes are well documented (paper IV). Whether there is a subset of glomeruli with collapsed capillary convolute, remains to be investigated.

The pressure lowering effect of TTA in 2K1C hypertension is attributed primarily to its interference with the renin angiotensin system, as renin production in the clipped kidney as well as plasma renin activity are reduced, and as there is a strong tendency to reduce the plasma angiotensin II level (paper IV).

6.6 Candesartan and pirfenidone in anti-GBM GN

The rat model of anti-GBM GN used in paper V is in its acute phase characterised by glomerular basement defects with development of crescents.¹⁰⁵ In the acute phase, obliteration of the tubular outlet by crescents might have been an important

mechanism of tubular degeneration.^{89, 90} Eight weeks after induction of glomerulonephritis, segmental glomerulosclerosis associated with absorption droplets and pseudocysts prevail, indicative of hyperperfusion damage (paper V).

The renoprotective effect of candesartan in anti-GBM GN is probably based on inhibition of acute glomerular injury,¹⁰⁶ as well as preventing chronic glomerular injury mainly by reduction of the intraglomerular pressure.^{22, 107} The former will preserve tubular flow, the latter will reduce glomerular overload.

Candesartan does not reduce glomerular and tubulointerstitial changes to the level of the control group. This opens for a combination with other drugs with a different mechanism of action. The antifibrotic effect of pirfenidone is documented in many animal studies¹⁰⁸, and confirmed in our study by reduction of mRNA expression of *coll1a1*, and further supported by decrease of tubular degeneration and interstitial inflammation (paper V). Interestingly, pirfenidone also reduced proteinuria and the percentage of glomeruli with absorption droplets in podocytes. The beneficial effect on proteinuria was confirmed in some^{45, 51, 109} but not all^{47, 110, 111} studies in mouse and rat models of renal disease. In our study pirfenidone seemed to prevent glomerular damage and in consequence preserve tubular flow and inhibit tubular damage. As reactive oxygen species play a role in the early phase of anti-GBM GN,¹¹² prevention of glomerular damage could be ascribed to the antioxidative properties of pirfenidone.^{34, 51, 113-115} Nitrotyrosine is an end product of peroxynitrite formation by nitric oxide and superoxide, and considered a marker of oxidative stress.¹¹⁶ Nitrotyrosine positivity in tubules point to oxidative injury in these structures, and even if pirfenidone alone only numerically but not significantly decreased nitrotyrosine positivity, the significant favourable effect of combination therapy might have been achieved at least in part by the antioxidative properties of pirfenidone (paper V). That glomeruli did not show nitrotyrosine positivity at the end of the study, does not argue against oxidative stress in the acute phase of the disease but merely reflects the fact, that oxidative stress may be less important in the chronic phase.

6.7 The novel drugs TTA and pirfenidone in clinical studies

What do we know about the effect of TTA and pirfenidone in clinical studies of chronic renal disease?

There are no ongoing clinical trials for TTA in chronic renal disease. TTA changed the lipid profile and decreased the plasma concentration of free fatty acids in a phase II clinical trial for diabetes mellitus type II.¹¹⁷ The drug was also tested in a pilot study in 8 patients with psoriasis without significant effect.¹¹⁸

Pirfenidone has been studied predominantly in fibrotic lung diseases, both in phase II and phase III trials¹¹⁹⁻¹²³ with overall beneficial effect on tested parameters. There are also a couple of phase II studies in other organ systems with fibrotic diseases,¹²⁴⁻¹³⁰ in which pirfenidone showed either no or an uncertain effect. Studies of pirfenidone in chronic renal diseases are sparse. Pirfenidone has been tested in a clinical phase II trial in FSGS.¹³¹ Treatment improved glomerular filtration rate. However, blood pressure and proteinuria remained unchanged. A phase III trial in diabetic nephropathy¹³² showed a significant improvement of glomerular filtration rate compared to the placebo group. Another phase II trial in FSGS is ongoing.¹³³

7. Conclusions

60-week-old SHR show hypertensive glomerular damage, tubular atrophy, and interstitial fibrosis predominantly in the JMC.

Interstitial fibrosis is the result of a disturbed collagen metabolism due to an increase of collagen production as well as an imbalance of collagen digestion and inhibition of digestion.

Tubular atrophy is only found in nephrons with collapsed glomeruli and hypertrophied afferent arterioles, indicating that reduced glomerular and subsequent tubular flow induce tubular atrophy. The misdirected filtration hypothesis and the hypoxia hypothesis are not supported by our findings in 60-week-old SHR.

The hypothesis that tubular atrophy is due to reduced tubular flow has to be evaluated in other rat models of chronic renal disease. The function of tubular cilia and its significance in renal disease should be further investigated.

TTA decreases blood pressure and largely prevents damage in 2K1C hypertension mainly by interference with the renin angiotensin system.

Pirfenidone ameliorates glomerular and tubulointerstitial damage in chronic anti-GBM GN. Its effect is comparable to candesartan, however with a trend to slightly better results with candesartan treatment. Our results suggest an additive effect of combination treatment.

8. Errata

Paper I

Page 1087, first paragraph: The sentence “The θ aChym of ~ 0.85 was similar in all cortical zones in SHR ($P = 0.36$), and the ratio of θ aChym to θ Chym was increased from ...” should read: The θ Chym of ~ 0.85 was similar in all cortical zones in SHR ($P = 0.36$), and the ratio of θ aChym to θ Chym was increased from ...”

“Adsorption droplets” in **paper I, IV** and **V** should read “absorption droplets”.

9. References

1. Leivestad T. Annual Report 2009. The Norwegian Renal Registry (Norsk Nefrologiregister). <http://www.nephro.no/nnr.html>. 2011.
2. Statistics Norway (Statistisk sentralbyrå). <http://www.ssb.no>. 2011.
3. Theilig F. Spread of glomerular to tubulointerstitial disease with a focus on proteinuria. *Ann. Anat.* 2010 May 20;192(3):125-132.
4. Nagata M, Kriz W. Glomerular damage after uninephrectomy in young rats. II. Mechanical stress on podocytes as a pathway to sclerosis. *Kidney International* 1992 Jul;42(1):148-160.
5. Kretzler M, Koepfen-Hagemann I, Kriz W. Podocyte damage is a critical step in the development of glomerulosclerosis in the uninephrectomised-desoxycorticosterone hypertensive rat. *Virchows Arch.* 1994;425(2):181-193.
6. Kriz W, Hahnel B, Rosener S, Elger M. Long-term treatment of rats with FGF-2 results in focal segmental glomerulosclerosis. *Kidney Int.* 1995 Nov;48(5):1435-1450.
7. Shirato I, Hosser H, Kimura K, Sakai T, Tomino Y, Kriz W. The development of focal segmental glomerulosclerosis in masugi nephritis is based on progressive podocyte damage. *Virchows Arch.* 1996 Nov;429(4-5):255-273.
8. Kriz W, Hosser H, Hahnel B, Simons JL, Provoost AP. Development of vascular pole-associated glomerulosclerosis in the Fawn-hooded rat. *J Am Soc Nephrol* 1998 Mar;9(3):381-396.
9. Kriz W, Gretz N, Lemley KV. Progression of glomerular diseases: Is the podocyte the culprit? *Kidney International* 1998 Sep 1;54(3):687-697.
10. D'Agati VD, Fogo AB, Bruijn JA, Jennette JC. Pathologic classification of focal segmental glomerulosclerosis: a working proposal. *Am J Kidney Dis.* 2004 Feb;43(2):368-382.
11. Fogo A, Glick AD, Horn SL, Horn RG. Is focal segmental glomerulosclerosis really focal? Distribution of lesions in adults and children. *Kidney Int.* 1995 Jun;47(6):1690-1696.
12. Fuiano G, Comi N, Magri P, *et al.* Serial morphometric analysis of sclerotic lesions in primary "focal" segmental glomerulosclerosis. *J Am Soc. Nephrol.* 1996 Jan;7(1):49-55.
13. Hostetter TH, Olson JL, Rennke HG, Venkatachalam MA, Brenner BM. Hyperfiltration in remnant nephrons: a potentially adverse response to renal ablation. *Am J Physiol* 1981 Jul;241(1):F85-F93.

14. Remuzzi G, Ruggenenti P, Benigni A. Understanding the nature of renal disease progression. *Kidney International* 1997 Jan;51(1):2-15.
15. Kriz W, Hosser H, Hahnel B, Gretz N, Provoost A. From segmental glomerulosclerosis to total nephron degeneration and interstitial fibrosis: a histopathological study in rat models and human glomerulopathies. *Nephrology Dialysis Transplantation* 1998 Nov 1;13(11):2781-2798.
16. Kriz W, Hartmann I, Hosser H, *et al.* Tracer studies in the rat demonstrate misdirected filtration and peritubular filtrate spreading in nephrons with segmental glomerulosclerosis. *J Am Soc Nephrol* 2001 Mar;12(3):496-506.
17. Kriz W, LeHir M. Pathways to nephron loss starting from glomerular diseases- insights from animal models. *Kidney International* 2005 Feb;67(2):404-419.
18. Fine LG, Bandyopadhyay D, Norman JT. Is there a common mechanism for the progression of different types of renal diseases other than proteinuria? Towards the unifying theme of chronic hypoxia. *Kidney Int. Suppl* 2000 Apr;75:S22-S26.
19. Kang DH, Kanellis J, Hugo C, *et al.* Role of the microvascular endothelium in progressive renal disease. *J Am Soc Nephrol* 2002 Mar;13(3):806-816.
20. Nangaku M. Chronic hypoxia and tubulointerstitial injury: a final common pathway to end-stage renal failure. *J. Am. Soc. Nephrol.* 2006 Jan;17(1):17-25.
21. National Center for Biotechnology Information. PubChem Substance Database.SID=53788093, source=Comparative Toxigenomics Database, <http://pubchem.ncbi.nlm.nih.gov/summary/summary.cgi?sid=53788093&viewopt=D> eposited. 2011.
22. Anderson S, Rennke HG, Brenner BM. Therapeutic advantage of converting enzyme inhibitors in arresting progressive renal disease associated with systemic hypertension in the rat. *J Clin. Invest* 1986 Jun;77(6):1993-2000.
23. Brewster UC, Perazella MA. The renin-angiotensin-aldosterone system and the kidney: effects on kidney disease. *Am J Med.* 2004 Feb 15;116(4):263-272.
24. Gudbrandsen OA. Impact of modified fatty acids and dietary proteins on risk factors of the metabolic syndrome. University of Bergen; 2006.
25. National Center for Biotechnology Information. PubChem Substance Database.SID=112378972, source=Comparative Toxigenomics Database, <http://pubchem.ncbi.nlm.nih.gov/summary/summary.cgi?sid=112378972&loc=es_rss>. 2011.
26. Asiedu DK, Froyland L, Vaagenes H, Lie O, Demoz A, Berge RK. Long-term effect of tetradecylthioacetic acid: a study on plasma lipid profile and fatty acid composition and oxidation in different rat organs. *Biochim. Biophys. Acta* 1996 Apr 19;1300(2):86-96.

-
27. Berge RK, Skorve J, Tronstad KJ, Berge K, Gudbrandsen OA, Grav H. Metabolic effects of thia fatty acids. *Curr. Opin. Lipidol.* 2002 Jun;13(3):295-304.
 28. Psaltopoulou T, Naska A, Orfanos P, Trichopoulos D, Mountokalakis T, Trichopoulou A. Olive oil, the Mediterranean diet, and arterial blood pressure: the Greek European Prospective Investigation into Cancer and Nutrition (EPIC) study. *Am J Clin. Nutr.* 2004 Oct;80(4):1012-1018.
 29. Zheng ZJ, Folsom AR, Ma J, Arnett DK, McGovern PG, Eckfeldt JH. Plasma fatty acid composition and 6-year incidence of hypertension in middle-aged adults: the Atherosclerosis Risk in Communities (ARIC) Study. *Am J Epidemiol.* 1999 Sep 1;150(5):492-500.
 30. Cases A, Coll E. Dyslipidemia and the progression of renal disease in chronic renal failure patients. *Kidney Int. Suppl* 2005 Dec;(99):S87-S93.
 31. Roszer T, Ricote M. PPARs in the Renal Regulation of Systemic Blood Pressure. *Ppar Research* 2010.
 32. Risdon RA, Sloper JC, De Wardener HE. Relationship between renal function and histological changes found in renal-biopsy specimens from patients with persistent glomerular nephritis. *Lancet* 1968 Aug 17;2(7564):363-366.
 33. Schainuck LI, Striker GE, Cutler RE, Benditt EP. Structural-functional correlations in renal disease. II. The correlations. *Hum. Pathol* 1970 Dec;1(4):631-641.
 34. Iyer SN, Wild JS, Schiedt MJ, Hyde DM, Margolin SB, Giri SN. Dietary intake of pirfenidone ameliorates bleomycin-induced lung fibrosis in hamsters. *J Lab Clin Med* 1995 Jun;125(6):779-785.
 35. Suga H, Teraoka S, Ota K, *et al.* Preventive effect of pirfenidone against experimental sclerosing peritonitis in rats. *Exp Toxicol. Pathol* 1995 Sep;47(4):287-291.
 36. Kehrer JP, Margolin SB. Pirfenidone diminishes cyclophosphamide-induced lung fibrosis in mice. *Toxicol. Lett.* 1997 Feb 7;90(2-3):125-132.
 37. Shetlar MR, Shetlar DJ, Bloom RF, Shetlar CL, Margolin SB. Involution of keloid implants in athymic mice treated with pirfenidone or with triamcinolone. *J Lab Clin Med* 1998 Dec;132(6):491-496.
 38. Tada S, Nakamuta M, Enjoji M, *et al.* Pirfenidone inhibits dimethylnitrosamine-induced hepatic fibrosis in rats. *Clin Exp Pharmacol Physiol* 2001 Jul;28(7):522-527.
 39. Garcia L, Hernandez I, Sandoval A, *et al.* Pirfenidone effectively reverses experimental liver fibrosis. *J Hepatol.* 2002 Dec;37(6):797-805.
 40. Mirkovic S, Seymour AM, Fenning A, *et al.* Attenuation of cardiac fibrosis by pirfenidone and amiloride in DOCA- salt hypertensive rats. *Br J Pharmacol* 2002 Feb;135(4):961-968.

41. Waller JR, Murphy GJ, Bicknell GR, Sandford R, Margolin SB, Nicholson ML. Pirfenidone inhibits early myointimal proliferation but has no effect on late lesion size in rats. *Eur J Vasc. Endovasc. Surg* 2002 Mar;23(3):234-240.
42. Spond J, Case N, Chapman RW, *et al.* Inhibition of experimental acute pulmonary inflammation by pirfenidone. *Pulm. Pharmacol Ther* 2003;16(4):207-214.
43. Di SA, Bendia E, Macarri G, *et al.* The anti-fibrotic effect of pirfenidone in rat liver fibrosis is mediated by downregulation of procollagen alpha1(I), TIMP-1 and MMP-2. *Dig. Liver Dis.* 2004 Nov;36(11):744-751.
44. National Center for Biotechnology Information. PubChem Substance Database.SID=53787735, source=Comparative Toxigenomics Database, http://pubchem.ncbi.nlm.nih.gov/summary/summary.cgi?sid=53787735&loc=es_rss. 2011.
45. Shimizu F, Fukagawa M, Yamauchi S, *et al.* Pirfenidone prevents the progression of irreversible glomerular sclerotic lesions in rats. *Nephrology* 1997;3(4):315-321.
46. Shimizu T, Kuroda T, Hata S, Fukagawa M, Margolin SB, Kurokawa K. Pirfenidone improves renal function and fibrosis in the post-obstructed kidney. *Kidney Int* 1998 Jul;54(1):99-109.
47. Shimizu T, Fukagawa M, Kuroda T, *et al.* Pirfenidone prevents collagen accumulation in the remnant kidney in rats with partial nephrectomy. *Kidney Int Suppl* 1997 Dec;63:S239-S243.
48. Miric G, Dallemagne C, Endre Z, Margolin S, Taylor SM, Brown L. Reversal of cardiac and renal fibrosis by pirfenidone and spironolactone in streptozotocin-diabetic rats. *Br J Pharmacol* 2001 Jul;133(5):687-694.
49. Shihab FS, Bennett WM, Yi H, Andoh TF. Pirfenidone treatment decreases transforming growth factor-beta1 and matrix proteins and ameliorates fibrosis in chronic cyclosporine nephrotoxicity. *Am J Transplant.* 2002 Feb;2(2):111-119.
50. Al Bayati MA, Xie Y, Mohr FC, Margolin SB, Giri SN. Effect of pirfenidone against vanadate-induced kidney fibrosis in rats. *Biochem Pharmacol* 2002 Aug 1;64(3):517-525.
51. Giri SN, Al Bayati MA, Du X, Schelegle E, Mohr FC, Margolin SB. Amelioration of doxorubicin-induced cardiac and renal toxicity by pirfenidone in rats. *Cancer Chemother Pharmacol* 2004;53(2):141-150.
52. Iyer SN, Gurujeyalakshmi G, Giri SN. Effects of pirfenidone on procollagen gene expression at the transcriptional level in bleomycin hamster model of lung fibrosis. *J Pharmacol Exp Ther* 1999 Apr;289(1):211-218.
53. Arumugam TV, Shiels IA, Margolin SB, Taylor SM, Brown L. Pirfenidone attenuates ischaemia-reperfusion injury in the rat small intestine. *Clin Exp Pharmacol Physiol* 2002 Nov;29(11):996-1000.

-
54. Nakazato H, Oku H, Yamane S, Tsuruta Y, Suzuki R. A novel anti-fibrotic agent pirfenidone suppresses tumor necrosis factor-alpha at the translational level. *Eur J Pharmacol* 2002 Jun 20;446(1-3):177-185.
 55. Hale ML, Margolin SB, Krakauer T, Roy CJ, Stiles BG. Pirfenidone blocks the in vitro and in vivo effects of staphylococcal enterotoxin B. *Infect. Immun* 2002 Jun;70(6):2989-2994.
 56. Okamoto K, Aoki K. Development of a strain of spontaneously hypertensive rats. *Japanese Circulation Journal* 1963;27:282-293.
 57. Okamoto K. Spontaneous hypertension in rats. *Int. Rev. Exp. Pathol* 1969;7:227-270.
 58. Pinto YM, Paul M, Ganten D. Lessons from rat models of hypertension: from Goldblatt to genetic engineering. *Cardiovasc. Res.* 1998 Jul;39(1):77-88.
 59. Gattone VH, Evan AP, Willis LR, Luft FC. Renal afferent arteriole in the spontaneously hypertensive rat. *Hypertension* 1983 Jan;5(1):8-16.
 60. Kimura K, Nanba S, Tojo A, Hirata Y, Matsuoka H, Sugimoto T. Variations in arterioles in spontaneously hypertensive rats. Morphometric analysis of afferent and efferent arterioles. *Virchows Arch. A Pathol Anat. Histopathol.* 1989;415(6):565-569.
 61. Skov K, Mulvany MJ, Korsgaard N. Morphology of renal afferent arterioles in spontaneously hypertensive rats. *Hypertension* 1992 Dec;20(6):821-827.
 62. Skov K, Mulvany MJ. Structure of renal afferent arterioles in the pathogenesis of hypertension. *Acta Physiol Scand* 2004 Aug;181(4):397-405.
 63. Iversen BM, Amann K, Kvam FI, Wang X, Ofstad J. Increased glomerular capillary pressure and size mediate glomerulosclerosis in SHR juxtamedullary cortex. *Am J Physiol* 1998 Feb;274(2 Pt 2):F365-F373.
 64. Feld LG, Van Liew JB, Galaske RG, Boylan JW. Selectivity of renal injury and proteinuria in the spontaneously hypertensive rat. *Kidney Int.* 1977 Nov;12(5):332-343.
 65. Ofstad J, Iversen BM. Glomerular and tubular damage in normotensive and hypertensive rats. *Am J Physiol Renal Physiol* 2005 Apr;288(4):F665-F672.
 66. Goldblatt H, Lynch J, Hanzal RF, Summerville WW. I. The production of persistent elevation of systolic blood pressure by means of renal ischemia. *J. Exp. Med.* 1934;59:347-379.
 67. Iversen BM, Morkrid L, Ofstad J. Afferent arteriolar diameter in DOCA-salt and two-kidney one-clip hypertensive rats. *Am J Physiol* 1983 Dec;245(6):F755-F762.
 68. Iversen BM, Matre R, Tonder O. Indirect haemagglutination for the demonstration of antibodies to renal antigens from rats. *Scand J Immunol* 1981;13(1):19-23.

-
69. Sweat F, Puchtler H, ROSENTHAL SI. Sirius red F3BA as a stain for connective tissue. *Arch. Pathol* 1964 Jul;78:69-72.
 70. Junqueira LC, Bignolas G, Brentani RR. Picrosirius staining plus polarization microscopy, a specific method for collagen detection in tissue sections. *Histochem. J* 1979 Jul;11(4):447-455.
 71. Junqueira LC, Montes GS, Sanchez EM. The influence of tissue section thickness on the study of collagen by the Picrosirius-polarization method. *Histochemistry* 1982;74(1):153-156.
 72. Heyeraas KJ, Aukland K. Interlobular arterial resistance: influence of renal arterial pressure and angiotensin II. *Kidney Int.* 1987 Jun;31(6):1291-1298.
 73. Kriz W, Barrett JM, Peter S. The renal vasculature: anatomical-functional aspects. *Int Rev Physiol* 1976;11:1-21.
 74. Bertram JF. Structure of the renal circulation. *Advances in Organ Biology* 2000;9:1-16.
 75. Inscho EW, Cook AK, Murzynowski JB, Imig JD. Elevated arterial pressure impairs autoregulation independently of AT(1) receptor activation. *J Hypertens.* 2004 Apr;22(4):811-818.
 76. Roald AB, Ofstad J, Iversen BM. Attenuated buffering of renal perfusion pressure variation in juxtamedullary cortex in SHR. *Am J Physiol Renal Physiol* 2002 Mar;282(3):F506-F511.
 77. Hara M, Yanagihara T, Kihara I. Urinary podocytes in primary focal segmental glomerulosclerosis. *Nephron* 2001 Nov;89(3):342-347.
 78. Puchtler H, Meloan SN, Waldrop FS. Are picro-dye reactions for collagens quantitative? Chemical and histochemical considerations. *Histochemistry* 1988;88(3-6):243-256.
 79. James J, Bosch KS, Aronson DC, Houtkooper JM. Sirius Red Histophotometry and Spectrophotometry of Sections in the Assessment of the Collagen Content of Liver-Tissue and Its Application in Growing Rat-Liver. *Liver* 1990;10(1):1-5.
 80. Grimm PC, Nickerson P, Gough J, *et al.* Computerized image analysis of Sirius Red-stained renal allograft biopsies as a surrogate marker to predict long-term allograft function. *J Am Soc. Nephrol.* 2003 Jun;14(6):1662-1668.
 81. Farris AB, Adams CD, Brousaides N, *et al.* Morphometric and visual evaluation of fibrosis in renal biopsies. *J Am Soc. Nephrol.* 2011 Jan;22(1):176-186.
 82. Luke RG. Hypertensive nephrosclerosis: pathogenesis and prevalence. Essential hypertension is an important cause of end-stage renal disease. *Nephrol Dial. Transplant.* 1999 Oct;14(10):2271-2278.

-
83. Javaid B, Olson JL, Meyer TW. Glomerular injury and tubular loss in adriamycin nephrosis. *J Am Soc Nephrol* 2001 Jul;12(7):1391-1400.
 84. Rognant N, Guebre-Egziabher F, Bacchetta J, *et al.* Evolution of renal oxygen content measured by BOLD MRI downstream a chronic renal artery stenosis. *Nephrology Dialysis Transplantation* 2011;26(4):1205-1210.
 85. Hoyer JR, Fogo AB, Terrell CH, Delaney MM. Immunomorphometric studies of proteinuria in individual deep and superficial nephrons of rats. *Lab Invest* 2000 Nov;80(11):1691-1700.
 86. Majno G, Joris I. *Cells, Tissues, and Disease: Principles of General Pathology*. 1 ed. Oxford: Blackwell Science; 1996.
 87. Rasch R, Nyengaard JR, Marcussen N, Meyer TW. Renal structural abnormalities following recovery from acute puromycin nephrosis. *Kidney Int.* 2002 Aug;62(2):496-506.
 88. Anderson S, Diamond JR, Karnovsky MJ, Brenner BM. Mechanisms underlying transition from acute glomerular injury to late glomerular sclerosis in a rat model of nephrotic syndrome. *J Clin. Invest* 1988 Nov;82(5):1757-1768.
 89. Kriz W, Hahnel B, Hosser H, *et al.* Pathways to recovery and loss of nephrons in anti-Thy-1 nephritis. *J Am Soc Nephrol* 2003 Jul;14(7):1904-1926.
 90. Le Hir M, Besse-Eschmann V. A novel mechanism of nephron loss in a murine model of crescentic glomerulonephritis. *Kidney Int.* 2003 Feb;63(2):591-599.
 91. Gandhi M, Olson JL, Meyer TW. Contribution of tubular injury to loss of remnant kidney function. *Kidney Int.* 1998 Oct;54(4):1157-1165.
 92. Latta H, Maunsbach AB, Madden SC. Cilia in different segments of the rat nephron. *J. Biophys. Biochem. Cytol.* 1961 Oct;11:248-252.
 93. Schwartz EA, Leonard ML, Bizios R, Bowser SS. Analysis and modeling of the primary cilium bending response to fluid shear. *Am. J. Physiol* 1997 Jan;272(1 Pt 2):F132-F138.
 94. Praetorius HA, Spring KR. Bending the MDCK cell primary cilium increases intracellular calcium. *J Membr. Biol.* 2001 Nov 1;184(1):71-79.
 95. Besschetnova TY, Kolpakova-Hart E, Guan Y, Zhou J, Olsen BR, Shah JV. Identification of signaling pathways regulating primary cilium length and flow-mediated adaptation. *Curr. Biol.* 2010 Jan 26;20(2):182-187.
 96. Waters AM, Beales PL. Ciliopathies: an expanding disease spectrum. *Pediatr. Nephrol.* 2011 Jul;26(7):1039-1056.
 97. Otto EA, Schermer B, Obara T, *et al.* Mutations in INVS encoding inversin cause nephronophthisis type 2, linking renal cystic disease to the function of primary cilia and left-right axis determination. *Nat. Genet.* 2003 Aug;34(4):413-420.

-
98. Nurnberger J, Bacallao RL, Phillips CL. Inversin forms a complex with catenins and N-cadherin in polarized epithelial cells. *Mol. Biol. Cell* 2002 Sep;13(9):3096-3106.
 99. Morgan D, Eley L, Sayer J, *et al.* Expression analyses and interaction with the anaphase promoting complex protein Apc2 suggest a role for inversin in primary cilia and involvement in the cell cycle. *Hum. Mol. Genet.* 2002 Dec 15;11(26):3345-3350.
 100. Simons M, Gloy J, Ganner A, *et al.* Inversin, the gene product mutated in nephronophthisis type II, functions as a molecular switch between Wnt signaling pathways. *Nat. Genet.* 2005 May;37(5):537-543.
 101. Jones DB. Ultrastructure of human acute renal failure. *Lab Invest* 1982 Mar;46(3):254-264.
 102. Wang L, Weidenfeld R, Verghese E, Ricardo SD, Deane JA. Alterations in renal cilium length during transient complete ureteral obstruction in the mouse. *J. Anat.* 2008 Jun 5;213(2):79-85.
 103. Verghese E, Weidenfeld R, Bertram JF, Ricardo SD, Deane JA. Renal cilia display length alterations following tubular injury and are present early in epithelial repair. *Nephrol. Dial. Transplant.* 2008 Mar;23(3):834-841.
 104. Skogstrand T, Hultstrom M, Leh S, Iversen BM. Juxtamedullary Cortex Has A Higher Degree of Renal Damage Than the Outer Cortex in the Non-Clipped Kidney in Two Kidney One Clip Rats After Long Exposure to Hypertension. *Journal of Hypertension* 2010 Jun;28:E491.
 105. Foellmer HG, Sterzel RB, Kashgarian M. Progressive glomerular sclerosis in experimental antiglomerular basement membrane glomerulonephritis. *Am J Kidney Dis* 1986 Jan;7(1):5-11.
 106. Mii A, Shimizu A, Masuda Y, *et al.* Angiotensin II receptor blockade inhibits acute glomerular injuries with the alteration of receptor expression. *Lab Invest* 2009 Feb;89(2):164-177.
 107. Maddox DA, Bennett CM, Deen WM, *et al.* Determinants of glomerular filtration in experimental glomerulonephritis in the rat. *J Clin Invest* 1975 Feb;55(2):305-318.
 108. Cho ME, Kopp JB. Pirfenidone: an anti-fibrotic therapy for progressive kidney disease. *Expert. Opin. Investig. Drugs* 2010 Feb;19(2):275-283.
 109. Park HS, Bao L, Kim YJ, *et al.* Pirfenidone Suppressed the Development of Glomerulosclerosis in the FGS/Kist mouse. *J Korean Med Sci* 2003 Aug;18(4):527-533.
 110. Brook NR, Waller JR, Bicknell GR, Nicholson ML. The experimental agent pirfenidone reduces pro-fibrotic gene expression in a model of tacrolimus-induced nephrotoxicity. *Journal of Surgical Research* 2005;125(2):137-143.

-
111. Takakuta K, Fujimori A, Chikanishi T, *et al.* Renoprotective properties of pirfenidone in subtotally nephrectomized rats. *European Journal of Pharmacology* 2010;629(1-3):118-124.
 112. Gwinner W, Grone HJ. Role of reactive oxygen species in glomerulonephritis. *Nephrology Dialysis Transplantation* 2000 Aug 1;15(8):1127-1132.
 113. Misra HP, Rabideau C. Pirfenidone inhibits NADPH-dependent microsomal lipid peroxidation and scavenges hydroxyl radicals. *Mol Cell Biochem* 2000 Jan;204(1-2):119-126.
 114. Iyer SN, Margolin SB, Hyde DM, Giri SN. Lung fibrosis is ameliorated by pirfenidone fed in diet after the second dose in a three-dose bleomycin-hamster model. *Exp Lung Res* 1998 Jan;24(1):119-132.
 115. Mitani Y, Sato K, Muramoto Y, *et al.* Superoxide scavenging activity of pirfenidone-iron complex. *Biochemical and Biophysical Research Communications* 2008;372(1):19-23.
 116. Pacher P, Beckman JS, Liaudet L. Nitric oxide and peroxynitrite in health and disease. *Physiol. Rev.* 2007;87(1):315-424.
 117. Lovas K, Rost TH, Skorve J, *et al.* Tetradecylthioacetic acid attenuates dyslipidaemia in male patients with type 2 diabetes mellitus, possibly by dual PPAR-alpha/delta activation and increased mitochondrial fatty acid oxidation. *Diabetes Obes. Metab* 2009 Apr;11(4):304-314.
 118. Kuenzli S, Saurat JH. Effect of topical PPARbeta/delta and PPARgamma agonists on plaque psoriasis. A pilot study. *Dermatology* 2003;206(3):252-256.
 119. Raghu G, Johnson WC, Lockhart D, Mageto Y. Treatment of idiopathic pulmonary fibrosis with a new antifibrotic agent, pirfenidone: results of a prospective, open-label Phase II study. *Am J Respir Crit Care Med* 1999 Apr;159(4 Pt 1):1061-1069.
 120. Nagai S, Hamada K, Shigematsu M, Taniyama M, Yamauchi S, Izumi T. Open-label compassionate use one year-treatment with pirfenidone to patients with chronic pulmonary fibrosis. *Intern. Med* 2002 Dec;41(12):1118-1123.
 121. Gahl WA, Brantly M, Troendle J, *et al.* Effect of pirfenidone on the pulmonary fibrosis of Hermansky-Pudlak syndrome. *Mol Genet. Metab* 2002 Jul;76(3):234-242.
 122. Azuma A, Nukiwa T, Tsuboi E, *et al.* Double-blind, placebo-controlled trial of pirfenidone in patients with idiopathic pulmonary fibrosis. *Am J Respir. Crit Care Med.* 2005 May 1;171(9):1040-1047.
 123. Noble PW, Albera C, Bradford WZ, *et al.* Pirfenidone in patients with idiopathic pulmonary fibrosis (CAPACITY): two randomised trials. *Lancet* 2011 May 21;377(9779):1760-1769.

-
124. Mesa RA, Tefferi A, Elliott MA, *et al.* A phase II trial of pirfenidone (5-methyl-1-phenyl-2-[1H]-pyridone), a novel anti-fibrosing agent, in myelofibrosis with myeloid metaplasia. *Br J Haematol.* 2001 Jul;114(1):111-113.
 125. Angulo P, MacCarty RL, Sylvestre PB, *et al.* Pirfenidone in the treatment of primary sclerosing cholangitis. *Dig Dis Sci* 2002 Jan;47(1):157-161.
 126. Bowen JD, Maravilla K, Margolin SB. Open-label study of pirfenidone in patients with progressive forms of multiple sclerosis. *Mult. Scler.* 2003 Jun;9(3):280-283.
 127. Lindor NM, Dozois R, Nelson H, *et al.* Desmoid tumors in familial adenomatous polyposis: a pilot project evaluating efficacy of treatment with pirfenidone. *Am J Gastroenterol* 2003 Aug;98(8):1868-1874.
 128. Armendariz-Borunda J, Islas-Carbajal MC, Meza-Garcia E, *et al.* A pilot study in patients with established advanced liver fibrosis using pirfenidone. *Gut* 2006 Nov;55(11):1663-1665.
 129. Babovic-Vuksanovic D, Ballman K, Michels V, *et al.* Phase II trial of pirfenidone in adults with neurofibromatosis type 1. *Neurology* 2006 Nov 28;67(10):1860-1862.
 130. Simone NL, Soule BP, Gerber L, *et al.* Oral pirfenidone in patients with chronic fibrosis resulting from radiotherapy: a pilot study. *Radiat. Oncol.* 2007;2:19.
 131. Cho ME, Smith DC, Branton MH, Penzak SR, Kopp JB. Pirfenidone Slows Renal Function Decline in Patients with Focal Segmental Glomerulosclerosis. *Clinical Journal of the American Society of Nephrology* 2007 Sep;2(5):906-913.
 132. Sharma K, Ix JH, Mathew AV, *et al.* Pirfenidone for diabetic nephropathy. *J. Am. Soc. Nephrol.* 2011 Jun;22(6):1144-1151.
 133. Kopp JB. "Permeability factor in focal segmental glomerulosclerosis." [Clinicaltrials.gov](http://clinicaltrials.gov).
<http://clinicaltrials.gov/ct2/show/NCT00007475?term=pirfenidone&rank=17>. Accessed 14.08.2011: 2011.