


---

# Ultrasound in Crohn's Disease

*- bowel wall characteristics and perfusion estimates using  
microbubbles*

**Kim Nylund**



Dissertation for the degree philosophiae doctor (PhD)  
at the University of Bergen  
2012

Dissertation date: 18.01.2013

“Gentlemen, we will skip the next chapter, since there are no recognized diseases of the small intestine, except tuberculosis.”

Professor Evan M. Evans holding a lecture for the medical student Burril B. Crohn

“I can’t believe schools are still teaching kids about the null hypothesis. I remember reading a big study that conclusively disproved it *years* ago.”

XKCD

---

## SCIENTIFIC ENVIRONMENT

This work was funded by the University of Bergen and Helse Bergen and performed at the Institute of Medicine, University of Bergen and Department of Medicine, Haukeland University Hospital.

The candidate also cooperated with the National Centre for Ultrasound in Gastroenterology, a Norwegian Centre of Excellence, and with Medviz, a Norwegian research consortium in medical imaging and visualisation.



FROM VISION TO DECISION



**HELSE BERGEN**

Haukeland universitetssjukehus



---

# TABLE OF CONTENTS

SCIENTIFIC ENVIRONMENT..... 3

TABLE OF CONTENTS..... 5

ACKNOWLEDGEMENTS..... 7

ABBREVIATIONS ..... 9

ABSTRACT..... 11

LIST OF PUBLICATIONS..... 13

**1. INTRODUCTION ..... 15**

    1.1 *Crohn’s disease* ..... 15

        1.1.1 Background ..... 15

        1.1.2 Symptoms and findings ..... 16

        1.1.3 Macroscopic and histological findings ..... 17

        1.1.4 Imaging in Crohn’s disease ..... 17

    1.2 *Diagnostic ultrasound* ..... 18

        1.2.1 General ..... 18

        1.2.2 B-mode ..... 19

        1.2.3 Doppler ..... 20

        1.2.4 Ultrasound of the GI tract ..... 21

    1.3 *Contrast-enhanced ultrasound and perfusion* ..... 23

        1.3.1 Microbubbles and contrast-enhanced ultrasound ..... 23

        1.3.2 Perfusion estimation with CEUS ..... 26

**2. AIMS OF THE STUDY ..... 33**

**3. MATERIALS AND METHODS ..... 35**

    3.1 *Study population*..... 35

    3.2 *Clinical scores*..... 36

    3.3 *Biochemical analysis*..... 36

---

3.4	<i>Macroscopic and histological examination</i> .....	36
3.5	<i>Ultrasound methods</i> .....	37
3.5.1	Ultrasound scanners and transducers.....	37
3.5.2	In vitro ultrasound .....	37
3.5.3	B-mode.....	38
3.5.4	Doppler techniques.....	39
3.5.5	Contrast enhanced ultrasound.....	39
3.6	<i>Software for perfusion analysis</i> .....	40
3.7	<i>Post-processing of exported video-loops</i> .....	40
3.8	<i>Ethics</i> .....	41
3.9	<i>Statistics</i> .....	41
<b>4.</b>	<b>SUMMARY OF PAPERS</b> .....	<b>43</b>
4.1	<i>Paper I:</i> .....	43
4.2	<i>Paper II:</i> .....	43
4.3	<i>Paper III:</i> .....	44
<b>5.</b>	<b>RESULTS AND DISCUSSION</b> .....	<b>45</b>
5.1	<i>Normal findings with ultrasound in the GI tract</i> .....	45
5.2	<i>Pathological ultrasound findings in patients with CD</i> .....	46
5.3	<i>CEUS perfusion measurements of bowel</i> .....	47
5.4	<i>Fibrosis and inflammation</i> .....	48
5.5	<i>Other limitations:</i> .....	49
5.6	<i>Conclusions and future perspectives</i> .....	50
	<b>REFERENCES</b> .....	<b>52</b>
	<b>PAPER I-III</b> .....	<b>62</b>

---

## ACKNOWLEDGEMENTS

First and foremost I would like to thank my main supervisor Trygve Hausken. It was his idea that we should work with Crohn's patients and the problem of fibrosis/inflammation. When I started working in the Gastroenterology Section in July 2002, I was instantly welcomed and almost before I had dirtied my first set of whites, they asked if I had considered going into research. I do not think it was because of my poor bedside manner, but rather due to a heartfelt belief that clinical medicine and research always should be paired. Trygve was there from the start egging me on with enthusiasm, energy and a multitude of ideas, and during my PhD period he has always been supportive both on a personal and professional level.

I also extend my gratitude to both my co-supervisors. Svein Ødegaard did most of the work trying to guide me through my first paper. Being a pioneer in diagnostic ultrasound his experience was invaluable in the planning and follow through of paper I. He also guided me in the mystery of gastrointestinal wall layers and the secret art of language precision which must have been an ungrateful task. Odd Helge Gilja offered countless possibilities and urged me on continuously with new challenges during my PhD period. A great network-builder he has introduced me to many of the other people contributing to this thesis, and he has taught me that research-life does not end with the PhD scholarship.

I am indebted to Eva Fosse at NCUG who always have been friendly and helpful and to the all the employees at the endoscopy and ultrasound unit at Haukeland University Hospital without which this work would have been impossible.

Sabine Leh and Heike Immervoll were there from the start giving me friendly help and advice in the world of histology where the real truth is hidden. Also guiding me early on was Knut Matre, who helped me with the set up in my first paper and who is always a patient advocate of ultrasounds physics. Arne Skarstein had a special interest in this patient group from a surgeon's perspective, and I thank him for being an enthusiastic teacher that helped me get started with the project. Frank Pfeffer continued the work offering fresh perspectives from the side of the surgeons and in

helping me recruit patients. I am also extremely grateful for the help and trust from Martin Mezl, Radovan Jirik and Torfinn Taxt who have deconvolved the blind more than once. Geir Egil Eide has with his knowledge of statistics given me help sorting out my data, my thoughts and thoughts about my data which has been of great value, especially in paper II where he also is a co-author. I would also like to thank the whole Visualisation group at the department of informatics including Helwig Hauser, Ivan Viola, Veronica Soltzesowa, Åsmund Birkeland, but especially, Paolo Angelelli who worked on issues of visualisation and data analysis relating to my thesis. None of the work born from the co-operation was included in the thesis at the end, but it was nevertheless a very fruitful relationship which gave birth to four papers. At the end of my PhD period I was also happy to be acquainted with Linn Helljesen organising the recruitment of healthy volunteers in paper III, and Spiros Kotoupolis who was very helpful in making a poor physician understand the wonderfully annoying world of microbubbles.

I have greatly enjoyed the warm company of my fellow PhD students in the cold office clinging to the clinical section of Haukeland University Hospital. Kristine Lillestøl, Maja Mujic, Vernesa Dizdar, Jørgen Valeur, Kurt Hanevik and Roald Flesland Havre have all been invaluable when discussing the big questions in science and the small aspects of everyday life.

Finally, I would like to thank my wife, Unn Jenny, for being clever and critical, strong and supportive, loving and lovely, and for being there. Magnar and Siri were born during my PhD period and have both yanked me from the laptop more than once and shown me that life works fine even without a proper protocol. In fact, it might even work better. Someone ought to investigate that.



---

# ABBREVIATIONS

- AIF - arterial input function
- Bv - Blood volume
- CEUS - Contrast-Enhanced Ultrasound
- CD - Crohn's disease
- CDAI - Crohn's disease activity index
- CT - computer tomography
- GI - gastrointestinal
- IBD - inflammatory bowel disease
- MI - mechanical index
- MHz - megahertz
- MRI - Magnetic resonance imaging
- MTT - Mean transit time
- PE - piezoelectric
- PET - positron emission tomography
- RI - resistive index
- ROI -region of interest
- SF<sub>6</sub> - sulphur hexafluoride
- US - ultrasound
- vb - speed of blood
- µms - micrometres



---

## ABSTRACT

Crohn's disease (CD) is a chronic inflammatory bowel disease which often presents early in life and sometimes can be debilitating. The patients need frequent diagnostic work-up to assess disease activity, location, extent and if complications have occurred. This warrants diagnostic tools which are of little nuisance to the patient, available, affordable and objective. Diagnostic ultrasound imaging could potentially fulfil these criteria. A specific problem in patients with CD is the differentiation of inflammation and fibrosis in the thickened bowel wall when an obstruction develops. Improved differentiation could lead to better tailoring of treatment.

The main aim of this thesis was to examine if there were ultrasound criteria which could separate fibrosis and inflammation.

In the first study 14 bowel specimens from patients operated for CD was examined with ultrasound in vitro and compared directly to histology. We found that some histological findings typical for CD which cannot be investigated in mucosal biopsies can be identified with ultrasound. A thickened muscular mucosa, echo changes in the submucosa and proper muscles are features of fibrotic disease while lymphocyte aggregates along the outer border of muscularis propria is a feature of chronic inflammation.

Since the main measurement used for detecting bowel disease is bowel wall thickness and proper reference values were wanting, study two was performed. The bowel wall thickness was measured in several locations in the gastrointestinal tract in 122 healthy volunteers. The results indicated that the normal bowel wall should not exceed 2 millimetres in most of the GI tract except for the stomach, duodenum and rectum. Furthermore, the reference values can be used for ultrasound probes with a frequency  $>8$  megahertz regardless of fasting state, age, weight sex and height.

In paper three two patient groups allocated for medical treatment (n=19) or surgical treatment (n=20) through a regular clinical work up were compared to identify features separating the two groups. Contrast enhanced ultrasound was used in combination

with a perfusion model to estimate blood flow in the bowel wall. We found that the surgical group had decreased blood volume and flow when compared to the medical group and markedly thicker bowel wall including the muscularis propria and mucosa.

From our results we conclude that a thickened muscular mucosa and echo changes in the submucosa as well as a reduced blood volume and flow could be indications of fibrostenotic disease and thus might support a decision for surgical treatment. Work remains on verifying the perfusion results with histology and to see if these findings can be reproduced in a larger group of patients. The perfusion model also needs further validation before implementation in regular clinical work.

---

## LIST OF PUBLICATIONS

This thesis is founded on the following papers, referred to in the text by their roman numerals:

- I. Nylund K, Leh S, Immervoll H, Matre K, Skarstein A, Hausken T, Gilja OH, Nesje LB and Ødegaard S. Crohn's disease: Comparison of in vitro ultrasonographic images and histology, *Scandinavian Journal of Gastroenterology*, 2008; 43:6, 719 — 726.
  
- II. Nylund K, Hausken T, Ødegaard S, Eide GE, Gilja OH. Gastrointestinal wall thickness measured with transabdominal ultrasonography and its relationship to demographic factors in healthy subjects. *Ultraschall in der Medizin*, Efirst, April, 2012.
  
- III. Nylund, K, Jirik, R, Mezl, M, Hausken, T, Pfeffer, F, Ødegaard, S, Taxt, T, Gilja, OH. Absolute perfusion measured with contrast enhanced ultrasound could be used to separate inflammation and fibrosis in patients with Crohn's disease. Manuscript accepted by *Ultrasound in Medicine and Biology* December 2012

Previously published papers were reprinted with permissions from the publishers.



---

# 1. INTRODUCTION

## 1.1 Crohn's disease

### 1.1.1 Background

Crohn's disease (CD) is a chronic inflammatory disease of the gastrointestinal (GI) tract named after one of the first to recognize it as a clinical entity in 1932 (1). Case reports have documented the disease back to 1769 (2).

The incidence of CD is higher in western, industrialized countries with an increasing incidence from south to the north in the northern hemisphere and including New Zealand and Australia in the southern hemisphere (3). In Norway, recent studies from the south-eastern part of the country show that the incidence of CD for those <16 years was about 6.9/ 100 000 in the period 2005-2007 while it was around 2.8 in the period from 1993-2004 (4;5). The overall incidence for a larger region in south eastern Norway was found to be 5,8/ 100 000 for the period 1990-93 (6). Prevalence in Norway is not known, but since mortality is not substantially increased in patients with CD and median age at diagnosis is about 30 years, in time one should expect prevalence of around 300/100 000 with a stable incidence.

CD affects the full depth of the GI wall and has a remitting course with inflammation and repair. It is also associated with complications such as fistulas, abscesses, intestinal perforation and obstruction of the intestinal lumen through the formation of strictures and stenosis.

The afflicted are usually young when first diagnosed and need frequent diagnostic care to evaluate disease activity and treatment effect. There is often a large discrepancy between symptoms and disease activity. This warrants a diagnostic tool that is objective, causes little patient distress and cumulative risk, is cost efficient and can show both the affected intestine and the peri-intestinal complications. Transabdominal ultrasound (US) could potentially fill many of these roles.

This thesis is focused on describing ultrasonographic findings in the intestinal wall in patients with CD using high frequency US probes and contrast-enhanced ultrasound and how these findings relate to findings in the healthy subjects, clinical outcome, histology and biochemical tests. Patients with only perianal CD are not a subject in this thesis as the focus is on transabdominal ultrasound.

### 1.1.2 Symptoms and findings

Symptoms and findings in CD depend on the location of disease in the GI tract or if complications have occurred. Typical symptoms at the time of diagnosis are long-lasting diarrhoea (85%) with or without traces of blood, abdominal pain (70%), and fatigue, anorexia and weight loss (60%).

Some patients present with complicated disease already at the time of diagnosis with GI obstruction symptoms due to stenosis, fistulas or abscesses. The interval between disease debut and time of diagnosis could be caused by patient's delay, doctor's delay or simply due to longstanding, indolent disease (7;8).

Some patients present with perianal disease (1-30%) (9), suspected appendicitis (10) and others also have extra-intestinal manifestations such as arthritis, sacro-ileitis, uveitis, erythema nodosum, pyoderma gangrenosum or kidney stones (8).

There is no biochemical test in blood or faeces that is specific for CD. Prolonged blood loss through bloody diarrhoea causes iron deficiency and lowered haemoglobin, but anaemia can also be a consequence of chronic inflammation, or CD associated vitamin B12 or folat deficiency (11). With pronounced inflammation there is an increase in leucocyte and platelet count and C-reactive protein (CRP), which are general markers of inflammation. Serum-albumin has a negative correlation with other activity markers, but this is rather unspecific, as both malnutrition and malabsorption, complications that could occur in these patients, also cause lowered albumin levels (12). Stool samples can be analysed for lactoferrin and calprotectin which both are markers of the migration of polymorphonuclear leucocytes to the intestinal mucosa. These are both more sensitive to intestinal inflammation than CRP, but not specific to CD (13).



---

### 1.1.3 Macroscopic and histological findings

In CD there is typically a patchy spread of disease in the bowel. In the affected areas, a thick, stiffened bowel wall with hypertrophy of the serosal fat, or fatty wrapping, can be found. Stenosis, fistulas and abscesses are other typical findings (14-16). When the specimen is cut open typical findings are deep, serpiginous and longitudinal ulcers, cobblestone appearance of the ileum, skip lesions and strictures (17).

In mucosal biopsies granulomas are pathognomonic of CD, but they are more frequent in children (about 50%) than in adults (about 20%). This is probably a reflection of that granulomas can be found more frequently in the early stages of the disease (18). In the same histological sections both normal crypts and crypts invaded by neutrophils, can be seen.

CD does, however, affect the wall transmurally. In full wall biopsies from operation specimens several other structures typical of CD can be found. Such features as a thickening of the muscularis mucosa (19), perivascular inflammation and inflammation of plexus myentericus are also common. A thickened muscularis mucosa is often associated with submucosal fibrosis (20). Lymphocyte aggregates can be found throughout the GI wall, also along the outer border of muscularis propria. These aggregates are a typical feature of CD and resemble a string of rosary beads when seen in cross section, hence the term Crohn's rosary (17).

### 1.1.4 Imaging in Crohn's disease

Endoscopy, particularly ileocolonoscopy, is currently the main tool for detecting CD. It allows inspection of the intestinal mucosa from the terminal ileum to the rectum and biopsies from all the inspected areas can be obtained. CD lesions can typically be found in any segment of the GI tract. Typical findings are as previously described. For study purposes there are validated indexes such as the simple endoscopic index of Crohn's disease (SES-CD) which can be useful for quantifying endoscopic disease activity (21).

Conventional small bowel enteroclysis and small bowel follow through was the main method for the diagnosis of CD in the small bowel for a long time and experienced examiners could diagnose CD with high sensitivity and specificity (22). Unfortunately, only the superficial and intraluminal features of the gastrointestinal wall can be evaluated and the extra-intestinal features of CD cannot be seen with these modalities.

Computer tomography enterography has high sensitivity and specificity for detection of disease, relapse and complications. Due to the cumulative load of ionizing radiation with repeated examinations it is not considered suitable for the follow up of CD patients, however (23).

Magnetic resonance imaging (MRI) enterography or enteroclysis has been shown to have a good accuracy for diagnosing CD, detecting the extent of disease, disease activity in the small bowel and for detecting extra-intestinal complications (23). To obtain high quality images fast imaging sequences in combination with drugs that reduce motility are needed. The intestine should be properly distended which is achieved either through installation of contrast via a naso-jejunal tube or per-oral ingestion. Intravenous contrast with gadolinium is used to evaluate bowel wall vascularity and perfusion. MRI has been suggested as the imaging modality for assessing bowel damage in CD (Lemann score) due to its good accuracy and non-ionizing nature (24). To obtain proper images of the whole GI tract, however, several different imaging sequences must be used. The availability cost of MRI and strain on the patient are arguments against such an implementation.

## **1.2 Diagnostic ultrasound**

### **1.2.1 General**

Ultrasound is sound that cannot be detected by the human ear, which means it must have a frequency above 20 000 Hertz (Hz). Typically diagnostic US is in the frequency range of 1000 000 Hz, or 1 Mega-hertz (MHz), to 40 MHz. Sound waves can be mathematically described as

---

$$\lambda = \frac{c}{f} \quad (1)$$

Where  $\lambda$ =the wavelength,  $f$ =frequency and  $c$ =speed of sound through a medium. This means that if the speed does not change, wavelength is directly proportional to the frequency. For most US scanners the speed of sound is defined as 1540 m/s which is the average sound speed through different human tissues.

In an US probe the ultrasound is emitted and received by one or more piezoelectric (PE) crystals. Axial resolution is dependent on the spatial pulse length (SPL) which is derived from the equation

$$SPL = \lambda \times n \quad (2)$$

Where  $n$ =the number of pulses per cycle. This means that a high frequency transducer ( $>7.5$ MHz) with a short pulse length will give better axial resolution than a low or median frequency transducer with a longer pulse length. The lateral resolution is dependent on the number of PE-crystals and focusing of the ultrasound beam.

The ultrasound wave is attenuated in the tissue through absorption, reflection and diffraction. It is the reflected sound that can be registered by the US probe. To compensate for the loss of return-signal or echo due to attenuation most scanners have time-gain compensation which basically enhances the return echo according to the time from the last pulse.

### 1.2.2 B-mode

In real-time B-mode (Brightness mode) imaging the echo from a specific depth is registered by a PE crystal and represented as a point of intensity varying according to the amplitude of the echo. Echo points from all the depths registered along the scan line of one PE crystal together with the scan lines of the other PE crystals are combined into an image.

### 1.2.3 Doppler

The different Doppler methods are based on the Doppler effect which causes a shift in frequency when a wave is reflected or emitted from an object in relative motion to the observer. It is mostly used for the detection and measurement of blood velocity. For reflected US it can be described by the equation

$$\delta f = 2 \times (f_e \times v_b \times \frac{\cos \theta}{c}) \quad (3)$$

where  $\delta f$  = change in frequency,  $f_e$  = emitted frequency,  $v_b$  = speed of blood,  $\theta$  = the angle between the ultrasound beam and the blood vessel and  $c$  = speed of sound in the medium.

With colour Doppler the speed and direction of blood moving within the analysed sector is represented with colours of different hues and intensity. Typically, blue colour represents movement away from the US probe while red colour represents movement towards the probe. Higher colour intensity indicates higher blood velocity. Examination of the GI wall typically warrants high sensitivity for the slow moving blood in small arteries and the scale should be set lower than  $\pm 5$ cm/s.

With pulse wave Doppler the Doppler shift is measured within a defined region along the US beam. If the angle between the blood flow and the US beam is known, the actual velocity of the blood within the vessel can be measured. Spectral pulse wave Doppler allows measurement of the average velocity which together with the cross sectional vessel area enables calculation of the actual blood flow. Resistive index (RI) is another useful parameter which is based on the relationship between the peak systolic (PSV) and end diastolic velocities (EDV). It is calculated as follows:

$$RI = \frac{PSV+EDV}{PSV} \quad (4)$$

This parameter has no units and gives a value between 0 and 1. It describes the blood flow resistance within the vessel and is independent of the angle between the US beam and the vessel. The combination of the colour Doppler information on the B-mode image coupled with spectral pulse wave Doppler is called triplex scanning. In this

---

modality the information from the colour Doppler image can be used as a guide to place the pulse wave Doppler sample region which is particularly useful in the intestinal wall where the vessels are small (25).

#### 1.2.4 Ultrasonography of the GI tract

The GI wall has a layered appearance on US images and according to the quality of the scanning system five to nine layers can be seen. The layers correlate to the histological layers to a certain degree. However, due to interface echoes the size and borders of the US layers differ slightly from the histological layers (26-30)(See figure 1, Paper II). When none of the wall layers can be seen with high frequency US, there is loss of stratification.

GI wall thickness measurements in healthy volunteers have indicated values between 0.9- 2 mm in the small intestine and 1.4-4.6 mm in the large intestine (31-35). In clinical studies 3-4 mm is typically used as a cut off between normal and pathological bowel wall (36-40).

In many European countries transabdominal US has been used for a long time in the diagnosis and follow-up of CD patients. US of the bowel can be performed by an experienced operator without technical assistance. Typically an US scanner with a curvilinear abdominal probe (1-5MHz) and a linear probe with a higher frequency range (7-15 MHz) are used (41). No preparation of the patient is required, the examination causes little discomfort or cumulative risk for the patients and the equipment has low buying and running costs when compared to CT and MRI. Another major advantage is that US of most of the GI tract from the stomach to the rectum can be performed during a relatively short time.

An US finding in patients with CD is often a thickened bowel wall in the range of 3 to 15 millimetres. US can also detect stenosis and extra-intestinal features like fatty wrapping, mesenteric lymph nodes, abscesses and fistulas (Figure 1)(42;43).

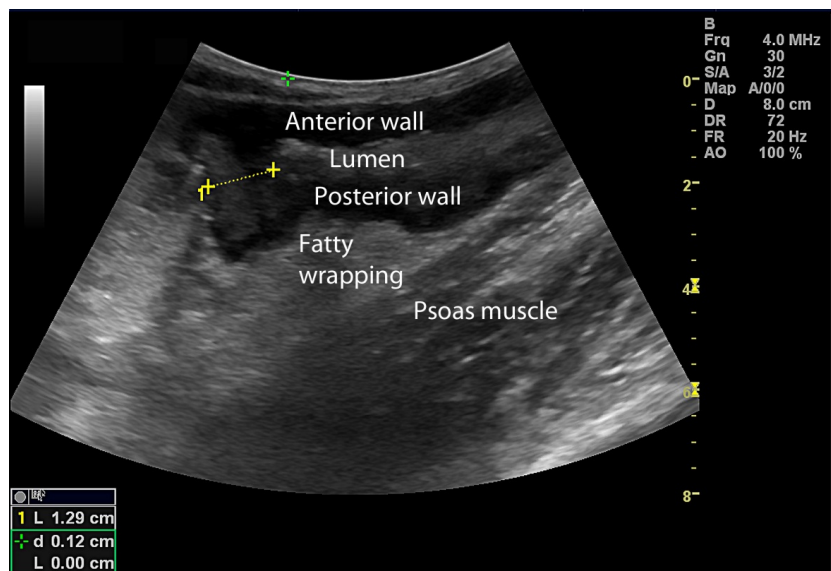


Figure 1: Stenosis in the terminal ileum with fatty wrapping and prestenotic dilatation.

For primary diagnostics and detection of relapse of CD ultrasonography has a high sensitivity (86-95%) and specificity (93-97%) which is comparable to MRI and CT (44-46). Ultrasonography is, however, less sensitive in the detection of deeply located abscesses and fistulas than the other techniques (47-49). These problems are mainly an issue in obese patients or patients with deeply located lesions in the lesser pelvis (50). Few studies explore the relationship between US findings and the differentiation between inflammation and fibrosis in the GI wall. Maconi et al. found that a thickened GI wall with preserved stratification in patients with otherwise low disease activity suggested that a stenosis was fibrotic while loss of stratification suggested an inflammatory stenosis (51;52). If the affected bowel section is shorter than 2 cm, this might also suggest intramural fibrosis (53).

Continuous Doppler examinations of central vessels supplying the intestine such as the superior and inferior mesenteric arteries have shown that increased perfusion seems to be related to disease activity (54;55). The challenge of using flow in these vessels as an indicator of disease activity is, however, that there is a large intra-individual variation making it difficult to suggest a reliable cut-off (51;54). Furthermore, other

---

factors may also influence the results such as disease location, previous surgery and GI wall thickness (56).

Assessing flow locally in the affected GI wall may be more useful since there are fewer confounding factors. This has been explored using a semi-quantitative scoring system with colour Doppler (57;58) as well as quantification through pixel analysis of colour Doppler recordings (59). Such Doppler techniques require strict standardization making them difficult to implement in clinical routine and sensitivity is markedly reduced with increasing depth (53). Yet another approach has been to measure the resistive index of intramural arteries in the GI wall. Some studies have shown promise yielding useful cut-off values (57;60;61). In practice, such measurements are difficult and quite often intramural arteries are not detected.

Finally, contrast-enhanced ultrasound (CEUS) techniques have been applied in patients with CD. Mostly, a semi-quantitative approach has been used, but two studies indicate that some parameters derived from the analysis of contrast intensity over time correlates with the degree of inflammation on histology (62;63). Recent studies also show that, CEUS can be used to separate inflammatory lesions from fibrotic lesions (62-64).

### **1.3 Contrast-enhanced ultrasound and perfusion**

#### **1.3.1 Microbubbles and contrast-enhanced ultrasound**

In this thesis, the term contrast enhanced ultrasound (CEUS) is applied to the combination of intravenous administration of microbubbles and the detection of these bubbles using ultrasound.

Microbubbles are gas-filled bubbles which are small enough to pass the smallest capillaries in the body, the pulmonary capillaries which means that they have to be less than 7 micrometre ( $\mu\text{m}$ ) in diameter (Figure 2).

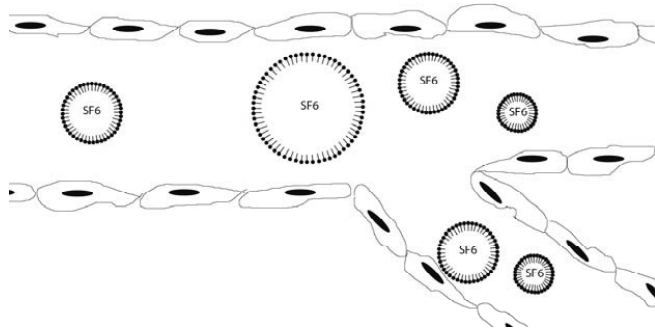


Figure 2: Sonovue microbubbles consist of a phospholipid monolayer enveloping sulphurhexafluoride gas with a diameter between 1-10  $\mu\text{m}$ . The microbubbles are drawn to scale in a capillary.

One of the key elements of a microbubble is its gas content. In principle, it can be any gas since it is the compressibility of a gas in comparison to the near-incompressibility of tissue which is exploited in imaging. In practice, however, it should be a biologically inert gas, and it should have a high molecular weight since this reduces diffusion speed. Another important component is the shell of the microbubble. It should be biologically inert as well and promote stability and a long bubble life, but it also affects the resonance features of the microbubble. Commonly, a phospholipid shell is used (65;66).

Sonovue (Bracco, Milan, Italy) consist of a monolayer phospholipid shell encasing the hydrophobic gas sulphur hexafluoride ( $\text{SF}_6$ ). The suspension contains from 100-500 million microbubbles/millilitre, 80% of the microbubbles have a diameter less than 8  $\mu\text{m}$ , the average bubble diameter is 2.5  $\mu\text{m}$  and the size range is from 0.7-10  $\mu\text{m}$  (67). It is currently the only US contrast agent approved for non-cardiac use in Norway.

The unique behaviour of microbubbles has led to a rapidly expanding field of bubble physics. There are two main aspects which are crucial in relation to perfusion quantification. First, some microbubbles such as Sonovue are true intravascular agents, which mean that they do not leak into the extravascular space between the endothelial cells and are not phagocytized. In this way, they behave like erythrocytes and anywhere there is blood flow microbubbles can be detected. Secondly, the microbubbles resonate in an US field giving a non-linear response that can be



---

separated from the tissue signal by various techniques. The resonance frequency of a microbubble is partly dependent on its diameter (68) and by chance microbubbles with a diameter of 3-5  $\mu\text{m}$  resonates with frequencies commonly used in imaging (3-5MHz)(Figure 3).

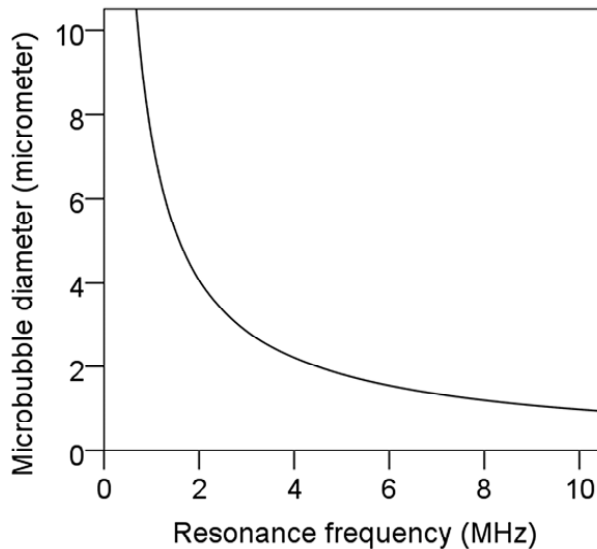


Figure 3: Microbubble diameter of Sonovue plotted against resonance frequency

The mechanical index (MI) indicates the amount of negative acoustic pressure in tissue in an US field. It is indicated in all commercial US scanners as a safety measure and it is an indication of the probability of inducing tissue effects through streaming or cavitation. Commonly the MI is between 0.5 and 1 in regular B-mode imaging. However, this amount of acoustic energy will cause microbubbles to burst. To observe microbubbles over time low MI imaging is required. Typically, this means MI lower than 0.2. However, to minimize bubble destruction MI should be set as low as possible without compromising image quality.

There are various ways to separate microbubbles from the tissue signal. All the resonating microbubbles generate harmonics or overtones. The second harmonic is double the transmit frequency and the easiest to detect, but also 3<sup>rd</sup> and 4<sup>th</sup> harmonics are produced as well as subharmonics (half the frequency). However, harmonics are

also reflected from the tissue and harmonic imaging has poor depth penetration due to attenuation and increasing sensitivity leads to reduced resolution.

Pulse inversion is another technique where two pulses of fundamental frequency with inverted phases are sent along the same scan line and cancel each other out when they are received. The microbubbles on the other hand generate non-linear signals which are out of phase and can thus be separated from the tissue signal (69). In older pulse inversion techniques harmonics were also often generated contaminating the images with tissue signal.

Non-linear fundamental signals can be detected with amplitude modulation. This technique seems to allow better cancellation of the tissue signal and the image resolution can be improved as the frequency of the non-linear received signal is close to the transmitted signal and a broader spectrum of signals can thus be received (70).

In vitro studies have shown that there is a linear relationship between microbubble concentration and ultrasound intensity within the clinical range if large vessels are avoided (71). Also, exported video data can be re-linearized to provide estimates similar to radiofrequency data if the gain is not set too low or high and if the dynamic range of the video is over 45 decibel. If these criteria are met this permits a reproducible estimation of microbubble concentration over time and thus permits perfusion estimation (72).

### 1.3.2 Perfusion estimation with CEUS

According to the central volume theorem there is a fundamental relationship between blood volume (Bv) and mean transit time (MTT):

$$\frac{Bv}{MTT} = \text{Blood flow} \quad (5)$$

Hence, if Bv and MTT of the blood through a location are known, blood flow can be calculated. In fact, knowing both Bv and MTT in a region could be more useful than knowing the blood flow alone. As both parameters contribute to the blood flow

---

estimate it could lead to better differentiation between conditions mostly affecting one parameter over the other.

Currently, the two main techniques for measuring perfusion with CEUS are burst replenishment and bolus tracking.

In the burst replenishment technique, the microbubbles are given as a continuous infusion. When steady state has been reached, all the bubbles in the imaging plane and in a small region surrounding it are burst by a high MI pulse (commonly MI=1).

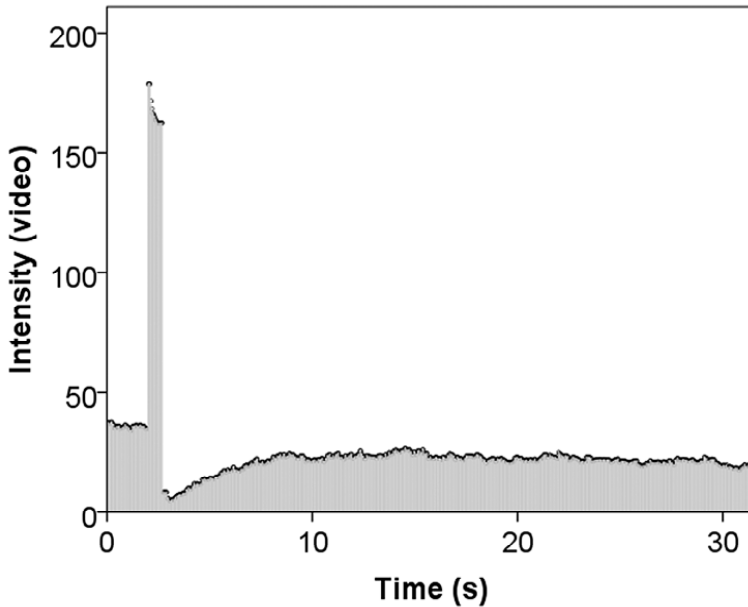


Figure 4: Video-intensity plotted against time (seconds) for the burst-replenishment technique. When a steady contrast enhancement is obtained through constant infusion, the microbubbles in the imaging plane are burst with high MI ultrasound giving rise to a flash. This leads to the destruction of all the bubbles in the imaging plane, the intensity drops to base level and then reperfusion occurs to steady state again is obtained. (Video-intensity is used for illustration purposes since the linearized intensity has such a large range.)

Then the reperfusion in the same area is observed (Figure 4). This reperfusion can be modelled as a simple increasing exponential curve (73) or the model can be made more complex to fit the anatomy of the micro-vasculature better (74). In the simple approach the signal-time intensity,  $S(t)$ , can be fitted to a mono-exponential function

$$S(t) = \alpha(1 - e^{\beta t}) \quad (6)$$

Where  $t$  is time in seconds,  $\alpha$  is the relative blood volume within the ROI and  $\beta$  the mean flow velocity and  $\alpha\beta$ =mean relative flow (73). The parameters derived from such a model is however only *proportional* to the real perfusion parameters.

Continuous infusion is also a complicated method for clinical use since it requires the use of an infusion pump specifically designed for the infusion of microbubbles.

With the bolus tracking technique, the microbubbles are given as an intravenous bolus injection. The injection is commonly performed through a decubital vein and followed by a flush of saline. The examination is recorded from the time of injection and should include the arterial phase and parts of the venous phase. This means that the recording times will differ somewhat according to the organ which is examined. The time-intensity data from a bolus injection can be used to calculate several semi-quantitative parameters (Figure 5) (75).

The problem with this approach is that the intensity related variables are still only relative to the ultrasound equipment and the single contrast vial being used. Also the time variables such as time of arrival, time to peak and mean transit time are not comparable between patients since they do not take the injections speed, patient size and vascular tree into account. These factors are described by the arterial input function (AIF).

There are different approaches for solving this problem. The AIF could be measured or estimated. To measure the AIF, the intensity in a single artery must be analysed over time. In US images this can be extremely difficult and normal contrast doses can cause attenuation in the arteries leading to an underestimation of the AIF. A better approach might be to estimate the AIF in a pharmacokinetic model (76).

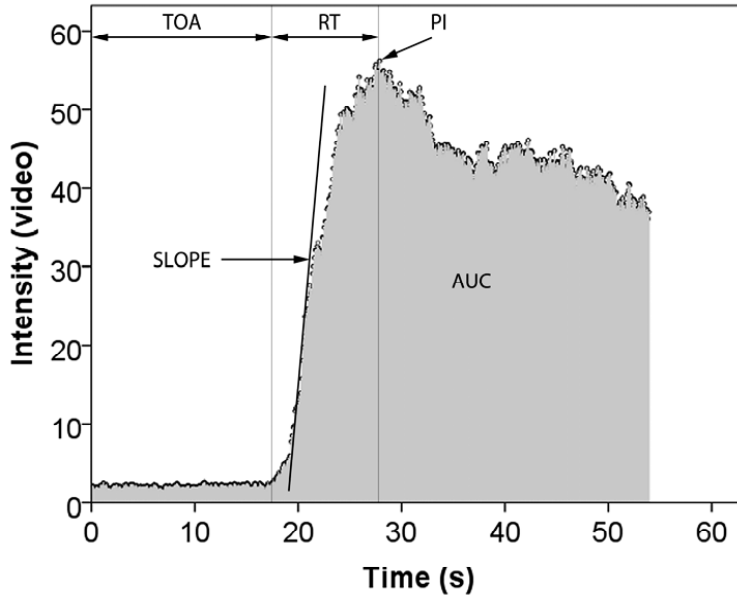


Figure 5: Video-intensity values plotted against time (seconds). From this curve several parameters can be derived such as time of arrival (TOA), rise time (RT), peak intensity (PI), slope and area under the curve (AUC). (Video-intensity is used for illustration purposes since the linearized intensity has such a large range.)

Since microbubbles are purely intravascular agents and assuming a linear relationship between US intensity and microbubble concentration (71), they are perfect tracers for the analysis of perfusion using a single compartment model on an intravenous bolus injection.

Assuming an infinitely short injection time and application directly to the analysed tissue, a pharmacokinetic model can be formulated as follows:

$$C_t(t) = \text{Blood flow} \times C_a \times R(t) \quad (6)$$

Where  $C_t(t)$  is the contrast concentration in tissue at given time  $t$ ,  $C_a$  is the arterial concentration at time 0 and  $R(t)$  is the tissue residue function which is the fraction of contrast remaining in the tissue vasculature at time ( $t$ ) after the infinitely short bolus, a function between 1 and 0. Blood flow has the unit ml/min/100ml tissue.

Since the injection cannot be infinitely short in real life the equation must be reformulated as

$$C_t(t) = \text{Blood flow} \times AIF(t) * R(t) \quad (7)$$

where the concentration of contrast in the arteries also is a function of time, the arterial input function or AIF(t). The equation states that the tissue concentration equals the convolution of the tissue residue function and the arterial input function. To derive blood flow from this equation the R(t) must be calculated using deconvolution which removes the dependency of the AIF. This approach is commonly used in MRI perfusion imaging of the brain where the MRI contrast does not leak over the blood-brain barrier and thus behaves in much the same way as ultrasound contrast (76).

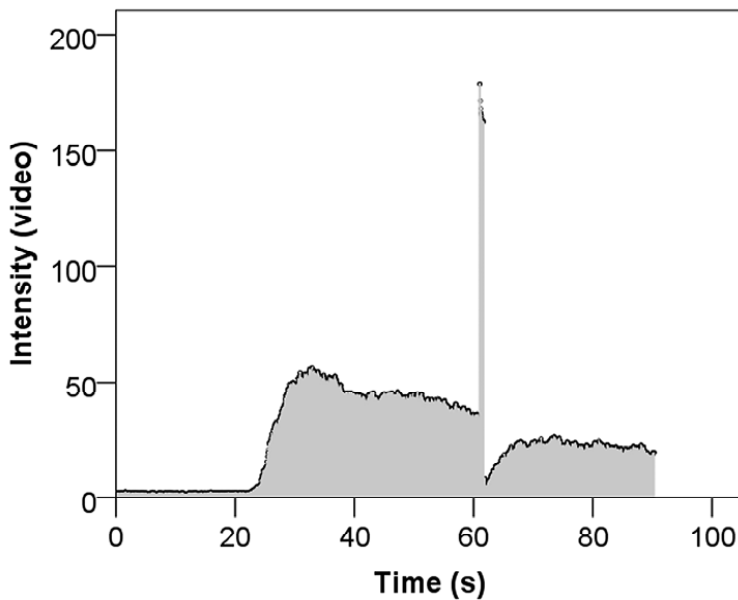


Figure 6: Video-intensity data for the bolus and burst method plotted against time (seconds). The curve includes a bolus phase followed by a burst and a replenishment phase. (Video-intensity is used for illustration purposes since the linearized intensity has such a large range.)

A similar approach has been applied using CEUS (77;78), but only recently Jirik et al. presented a possible solution (79;80). This requires another way of acquiring the CEUS data which consists of injecting a contrast bolus followed by bursting the microbubbles when the arterial phase has passed and the contrast enhancement has reached a pseudo steady-state. This method is called bolus and burst since both the bolus passage and the burst replenishment is recorded in the same cine loop (Figure 6).

---

This enables the calculation of the mean transit time. The integral of the estimated AIF is scaled to the integral of an AIF measured in a local artery or from a separate recording. Finally, the blood flow is calculated according to equation (5).

In summary, the burst-replenishment technique is practical in the sense that only the local perfusion in the GI wall is analysed and the AIF is not a concern. On the other hand it requires expensive equipment and a cumbersome set up and does not offer possibilities for absolute perfusion measurements. Bolus tracking can be used for the calculation of absolute perfusion, but issues concerning the correction for the AIF need to be resolved. The bolus and burst technique offers both the simplicity of a bolus injection with the possibility of estimating the arterial input function and thus enables the calculation of absolute perfusion parameters.





---

## 2. AIMS OF THE STUDY

The main aim of the thesis was to identify ultrasound findings that could be used to separate inflammatory from fibrotic stenosis in patients with Crohn's disease. Three papers are included in this thesis. The specific aims of these papers were as follows

I: To examine the echo properties of typical histological features for Crohn's disease

II: To establish reference values for the GI wall thickness and individual wall layers as measured by ultrasound and examine how they were affected by fasting state, US probe frequency and demographic factors.

III: To examine if it was feasible to perform absolute perfusion measurements in CD patients fitting the time intensity data to a pharmacokinetic model and if there were differences in perfusion parameters, typical ultrasound findings and thickness of the GI wall and wall layers between patients with mainly fibro-stenotic disease and patients with mainly inflammatory disease using high frequency ultrasound and CEUS.



---

## 3. MATERIALS AND METHODS

### 3.1 Study population

All patients in papers I and III were recruited at Haukeland University Hospital. The patients were either admitted to the bed wards, examined at the ultrasound and endoscopy unit or at the outpatient clinic at the time of recruitment. The patients were referred by the treating gastroenterologist or the gastroenterological surgeon contributing to the study. In paper I we included patients scheduled for bowel resection. In paper III we compared one group receiving medical treatment with another group receiving surgical treatment.

The main investigator informed the patients and obtained written consent.

All the patients undergoing surgery were examined with US within one week prior to surgery, but most of them the day before surgery. All the patients receiving medical treatment were examined within one week before start of treatment, the majority of them the same day as starting treatment and never later than three days after starting treatment. All patients were given the same surgical or medical treatment regardless of entering in the studies or not.

In paper II healthy volunteers were recruited among the staff at Haukeland University Hospital through local adverts and a general e-mail invitation to all employees.

Retirees were recruited by adverts through local organizations. In paper III 30 healthy volunteers were recruited through local adverts at Haukeland University Hospital and the University Campus.

Paper I (n=14) and III (n=39) were explorative, pilot studies and for this purpose the number of patients included were considered sufficient. In paper II (n=122) a power analysis was done with regards to detecting possible demographic differences.

Details on inclusion and exclusion criteria are further described in the corresponding papers.

### **3.2 Clinical scores**

Crohn's disease activity index (CDAI) was developed and validated by Best et al. (81) It consists of a questionnaire registering disease specific symptoms the last 7 days before recording the data, findings and extra-intestinal features and a measurement of the erythrocyte volume fraction (EVF). The simple index or Harvey-Bradshaw index is a simplified version of CDAI only registering symptoms from the last two days (82). It has the advantage of being faster to record and not require actual weight measurements and blood sampling.

### **3.3 Biochemical analysis**

Blood samples for patients in paper III were taken the same day as the US examination while stool samples were collected within a week or before surgery. In blood Haemoglobin (g/dl), erythrocyte volume fraction, leucocyte count ( $\times 10^9/L$ ), platelet count ( $\times 10^9/L$ ), C-reactive protein (mg/L) and albumin (mg/L) was analysed in the hospital laboratory facility as a part of the regular work up. The patients collected and delivered the stool samples themselves at first opportunity after the exam. Calprotectin (mg/kg) was analysed using an ELISA-kit.

### **3.4 Macroscopic and histological examination**

In paper I the resected GI specimens were collected and inspected immediately after devitalization. The US setup is described in more detail in section 3.5.2. The sectioning was done by an experienced pathologist with the main investigator present. The sections corresponding to the US imaging planes were removed in one piece meaning that large whole mount slices had to be made since the width of the imaging plane was 40 mm. Then 2 mm thick sections were embedded in paraffin, cut into 5  $\mu$ m thick slices and coloured according to standard procedures. Haematoxylin-eosin was used for standard histological evaluation and Masson-trichrome for the evaluation of fibrosis.

---

The histological findings were defined as follows: The muscularis mucosa was thickened if  $\geq 0.3$  mm and Crohn's rosary was considered present if there were lymphocyte aggregates along the serosal border  $\geq 0.3$  mm. The cut-off was set to 0.3 mm as this was just higher than axial resolution of the US probe. Fibrosis in the submucosa and muscularis propria were graded using a Likert scale from 0 to 2 where 0= normal, 1=slight to moderate fibrosis and 2=severe fibrosis. Further details on the categorization are described in paper I. The histological examination was performed by the main investigator and an experienced pathologist.

### **3.5 Ultrasound methods**

#### **3.5.1 Ultrasound scanners and transducers**

Several different US scanners and probes were used throughout the study period. In paper I the US images were obtained with a 10 MHz linear array US probe and a SystemFive US scanner (GE Vingmed Ultrasound, Horten, Norway). In paper II all of the healthy subjects were examined with a Logiq 9 US scanner (GE Healthcare, Milwaukee, USA) while only some of the patients in study III were examined with this scanner. The Logiq 9 scanner was used with a curvilinear US probe (4C) and two linear US probes (9L and 12L). The rest of the patients in study III were examined with a Logiq E9 US scanner with a C1-5 curvilinear US probe and two linear probes (9L and ML6-15). Further details on the US equipment are described in the corresponding papers.

#### **3.5.2 In vitro ultrasound**

In paper I the US findings were compared directly to the findings in the resection specimens as this is considered as the gold standard for diagnosing and describing Crohn's disease. The specimens were prepared by cutting them open in the longitudinal direction, cleaned with water and pinned in a specimen container filled with saline before being examined with US. The mucosal side of the intestine was facing up towards the US probe fixed in a purpose made holder attached to a micro-positioner. To avoid reverberations and delineate the outer border of the specimen the

---

container was filled with an echo poor agar. The probe holder was equipped with needle channels on each side of the scanning plane, enabling precise marking of the scanning plane in the specimen with colour-coded needles. The in vitro set up was based on a study by Kimmey et al.(83) and details concerning the equipment and consumables are described in more detail in paper I.

The muscular mucosa was considered thickened if there were two extra echo layers between the layers corresponding to the mucosa and submucosa. Lymphocyte aggregates along the outer border of muscularis propria were considered present if there were echo poor extensions from the muscularis propria layer into the serosa and subserosa. The echogenicity of the submucosal layer was categorised on a Likert scale ranging from 0 to 2. For the submucosa 0=echo rich (normal), 1= echo rich with sporadic echo poor elements, 2= echo rich with diffuse echo poor elements. For the muscularis propria layer 0= echo poor (normal), 1= echo poor with sporadic echo rich elements, 2= echo poor with diffuse echo rich elements.

### 3.5.3 B-mode

In paper II the healthy subjects were initially scanned with the curvilinear probe 4C for the measurement of wall thickness in the gastric antrum and duodenum since these areas sometimes are so deeply located that they cannot be imaged with high frequency US probes. For the same reason the rectum was only examined with the 4C. All locations except for the rectum were scanned with the 9L set to 8 MHz and the 12L set to 12 MHz. Starting from proximally in the GI tract the measurements were done in the gastric antrum, duodenal bulb, jejunum located in the upper left quadrant, jejunum located in the lower left quadrant, terminal ileum, ascending, transverse, descending and sigmoid colon. The wall thickness was measured in the anterior wall of the bowel from the start of the echo poor layer corresponding to the muscularis propria to the end of the echo poor layer corresponding to the mucosa (See figure 1 in paper II). The thickness of the echo layers corresponding to the mucosa, submucosa and muscularis propria for the same location were also measured in the ileum and sigmoid colon. Two measurements were made in each location and averaged. Details on how the measurements were optimized to avoid overestimation of wall thickness are further

---

described in paper II. In eight randomly selected healthy subjects measurements of the ileum and sigmoid colon were repeated by a second observer blinded to the measurements from the main investigator for estimating interobserver variability.

In paper III the patients were first scanned with the curvilinear abdominal probe to look for areas with affected intestine and to get an overview. Then the scan was repeated with the linear probe. The US probe with the highest frequency range was used if possible. The scanning was performed systematically starting in the right iliac fossa. First the colon was followed from the ileocecal valve to the rectum, and then the small intestine was scanned from the right iliac fossa towards the upper left quadrant. Every time a pathological area was found its location was noted and measurements performed. The affected or stenotic area with the thickest GI wall was chosen for examination with CEUS.

The location and length of each affected segment was noted as well the presence or absence of complications such as abscesses, stenosis or fistulas in association with the affected segment. The measurements of GI wall thickness and layer thickness were performed as in paper II except that the average of three measurements for each location was used.

#### **3.5.4 Doppler techniques**

In paper III colour Doppler was performed with the 12L (Logiq 9) and the ML6-15 (Logiq E9). Both probes were set with a velocity scale of  $\pm 2$  cm/s for detection of blood flow in arteries within the GI wall. Gain was increased to flash artefacts occurred and then reduced to the artefacts subsided. Colour Doppler was scored using a Likert scale from 0-2 where 0=0-2, 1=3-5 and 2= $\geq$ 5 colour Doppler signals per square centimetre (58). Pulse wave Doppler of an artery in the submucosa was performed in triplex mode when possible and the resistive index of three cycles were measured and averaged.

#### **3.5.5 Contrast enhanced ultrasound**

In paper III CEUS was performed in contrast mode on the US scanner, using the general setting and an MI of 0.10-0.12. The bolus injection of 4.4 ml ultrasound contrast

(Sonovue, Bracco, Milan, Italy) was chosen after pilot examinations indicating that this was the best dose for detecting intensity changes in the GI wall. The contrast was injected over 2 seconds through a 20 gauge venflon in a decubital vein followed by a flush of 10 ml 0.9% NaCl over 4 seconds. Approximately 55 seconds after injection the bubbles in the imaging plane were burst using a high MI flash and the observation continued for further 30 seconds. A continuous video recording including a short prebolus phase, bolus and replenishment phases was stored as a single 90 second loop. The same procedure was performed in the healthy volunteers except attempts were made to include both a part of the terminal ileum and the ascending colon in the frame. If both could not be included either due to excessive peristalsis in the terminal ileum or if the cecum covered the ileum, the ascending colon was the preferred target for observation.

### **3.6 Software for perfusion analysis**

In co-operation with Radovan Jirik and colleagues a software for the analysis of CEUS data for the extraction of perfusion information was developed (<http://www.isibrno.cz/perfusion/>). The software offers the possibility to upload video files in DICOM -format, down-sample the cine loops to a more convenient size by reducing frame rate, automatic and manual motion correction, conversion of log-converted video data to acoustical units approximately linear to the radio-frequency data, selection of several regions of interest, selection of arterial input function for scaling and two new pharmacokinetic models for the calculation of absolute perfusion.

### **3.7 Post-processing of exported video-loops**

The video data from the contrast recordings were exported as DICOM files. These were imported into the DCE-US software. To reduce the computational load the videos were down-sampled from 4-11 frames/second to about 2 frames per second leaving a maximum of 180 frames per video. Several methods using automatic and manual motion correction were tested (84;85), but in the end the fastest and most robust method available was a manual correction which could correct for translational displacement, but not rotation or deformation. Off plane frames were excluded from the analysis. As



---

the intensity information in the video data consists of log-converted data this had to be re-linearized using a conversion module in the software. The conversion was done with respect to the dynamic range of the video. Then a region of interest was chosen in the anterior wall of the affected intestine and the time intensity data were analysed using the modified bolus and burst algorithm (79;80). Finally, the results from this analysis were scaled. This was done by scaling the estimated AIF to the AIF measured in an artery in the same recording. While the end product of the perfusion analysis was the mean transit time, the scaling procedure gave the blood volume. From these two parameters blood flow was calculated.

### **3.8 Ethics**

All studies were approved by the Regional Ethics Committee for western Norway and conducted according to the Helsinki Declaration. All patients and healthy volunteers gave their informed consent before participating in the studies.

### **3.9 Statistics**

Paper I was descriptive and only the absolute number of the different variables were presented. In paper II SPSS version 15.0 and in paper III IBM SPSS statistics 19.0 was used. The details of the analysis performed are presented in the different papers.



---

## 4. SUMMARY OF PAPERS

Paper I and III included patients operated for CD. In the first the intestine was examined with US in vitro while in the third they were examined prior to surgery. A group of patients treated medically for an exacerbation of CD were also included in paper III. Healthy volunteers were included as a reference material in paper II and as a control group in paper III.

### 4.1 Paper I:

The purpose of this study was to compare histological findings in resected bowel from patients with CD with US images to investigate if findings typical for CD had corresponding US features. Specimens were examined with a 10 MHz linear US probe in an in vitro set up ensuring an accurate marking of the imaging planes. Several sections (3-9) from each specimen were made according to the markings and from each section several regions of interest (ROI) (1-3) were chosen for comparison. There were altogether fourteen patients, 58 sections and 123 ROIs. Thickened muscularis mucosa ( $\geq 0.3$  mm) was found in 48 of 69 ROIs. Submucosa with slight to moderate fibrosis was found in 36 of 56 ROIs, while severe fibrosis was seen in 40 of 55 ROIs. Slight to moderate fibrosis of muscularis propria was seen in 49 of 66 ROIs and severe fibrosis was seen in 17 of 22 ROIs. Crohn's rosary was seen in 31 out of 50 ROIs. We concluded that typical changes in CD did have US characteristics that could be detected and that increasing fibrosis seemed to cause an increase of echogenicity in the muscularis propria and a decrease of echogenicity in the submucosa.

### 4.2 Paper II:

The aim of this study was to establish reference values for GI wall thickness and thickness of individual wall layers in the GI tract as well as determining if these parameters are dependent on demographic factors, transducer frequency and fasting state. We examined 122 healthy subjects aged 23 – 79 with both 8 and 12-MHz transducers. Twenty-three subjects were given a test meal and re-examined after 30

minutes. The mean wall thickness was less than 2 millimetres including two standard deviations in all sections of the GI tract except the antrum, duodenum and rectum. The overall wall thickness was dependent on weight, age and probe frequency used in the study. The wall thickness also increased in the ileum and sigmoideum after the test meal. The differences were not large enough to require a correction of the reference values.

### **4.3 Paper III:**

The purpose of this study was to investigate the feasibility of absolute perfusion measurements with CEUS in Crohn's patients and examine if there were differences in bowel wall perfusion between patients with mainly inflammation and patients with mainly fibrosis. For this reason we chose to compare patients scheduled for surgical treatment (n=20) with patients receiving medical treatment for a flare up (n=19). The patients were examined with transabdominal US including CEUS close to the start of treatment as well as clinical and biochemical indices of disease activity and inflammation.

We found that absolute perfusion estimation was feasible in 90% of the patients. Furthermore, there was a significantly lower blood volume in patients receiving surgery for CD compared to those with an acute flare up ( $p=0.001$ ) and healthy subjects ( $p=0.005$ ). Blood flow was also lower in the surgery group when compared to the medical group ( $p=0.006$ ). As expected the GI wall was thicker in the surgery group ( $p<0.001$ ), and this seemed to be reflected in a significantly thicker mucosa ( $p=0.005$ ) and muscularis propria ( $p<0.001$ ) while the submucosal thickness was not different between the two groups.

---

## 5. RESULTS AND DISCUSSION

### 5.1 Normal findings with ultrasound in the GI tract

In paper II, we found that the average wall thickness for both the small and large bowel was below 1.2 mm. This is comparable to the study by Haber et al. (32) using a linear 7 MHz probe which is the only other study looking at comparatively large number of subjects. Older studies (34;86) report considerably higher values.

The differences in results might be attributed to the equipment, higher frequency probes with potentially better resolution and better post-processing of images. This is supported by the result showing that the GI wall is measured as thicker using 8 versus 12 MHz frequency. This is also a paradoxical finding as a lower resolution probe actually should make the anterior GI wall appear thinner since it will cause thicker interface echoes and thus less of the actual muscularis propria will be included in the measurement. We believe this is due to a selection bias. US probes with a low resolution will produce images where parts of the GI tract simply cannot be discerned. The operator will then perform the measurements in areas which on average have a greater wall thickness. In our study, the difference between the two probes was statistically significant, but so small that it probably does not have any diagnostic implications. One could speculate that this has higher impact when using probes with lower frequencies. The limit of the lateral resolution is half the spatial pulse length of the US beam given by equation (2). Since both the wavelength is longer and the number of pulses per cycle commonly higher in a 3-5 MHz probe compared to a high frequency probe (>7.5MHz) the combined effect will cause large differences in axial resolution.

While we found that the mean and 2SD was less than 2 mm for all locations in the GI tract but the antrum, duodenum and rectum, many recent studies used 3 or 4 mm as a cut off between healthy and pathological bowel (36-39;87;88). This will reduce false positive findings, but also compromises sensitivity. In our institution experienced colleagues performing bowel sonography of patients with IBD often notice a “marked

bowel wall” when they find a wall between 2 and 3 mm. This finding sometimes corresponds with pathological findings on ileocolonoscopy. Lowering the cut off to 2 mm would mean that these patients would be considered as having bowel wall affection.

Finally, we found that the overall wall thickness in the GI tract was dependent on both weight and age and that this effect was more pronounced in parts of the GI tract. We also found that the ileum and sigmoid colon becomes thicker after a meal. While the postprandial thickening can be explained by the gastro-ileal and gastro-colic reflexes, we have no clear explanation for the weight and age dependency (89). The most important conclusion that can be drawn from these data is that even though weight, age, fasting state and probe frequency does influence the wall thickness measurements, the effect on the reference values seems to be of no clinical importance

## **5.2 Pathological ultrasound findings in patients with CD**

In paper I the US characteristics of histological findings typical for CD such as fibrosis of the submucosa and muscularis propria, thickening of the muscularis mucosa and Crohn’s rosary (14;15;19) were identified and categorised. In paper III it was demonstrated that some of these findings seem to occur more frequently in patients operated for CD which corresponds to previous studies indicating that these histological findings appear to be typical in chronic inflammation and fibrosis (15;19;90;91). There were no significant differences in the echogenicity of muscularis propria between the two groups in paper III, but fibrosis of the muscularis propria is more rare (15) and was clearly less frequent in the areas examined in paper I (Severe submucosal fibrosis 54/123. Severe fibrosis of muscularis propria: 22/123).

In paper III, the thickest GI wall was found in the patients operated for CD. This corresponds with previous studies showing that a thickened GI wall increases the risk for surgery (37;92;93). Since the indication for surgery in most instances is stenotic obstruction, this is to be expected. A more interesting finding was that the mucosa and muscularis propria was significantly thicker in patients operated for CD than compared with those receiving medical treatment. In contrast Fritscher-Ravens found that

---

thickening of the submucosa is a typical feature in acute CD (94). Pathological examination of resected specimens typically show that the submucosa is thickened in the acute stages of the disease due to oedema (15). The thickening persists due to collagen depositions and the collagen gradually causes a loss of compliance between the submucosa and the muscularis propria and in turn a thickening of all wall layers (90). Accordingly, the US finding of a relatively thick submucosal layer in a thickened GI wall could be a sign of acute disease while a thickened GI wall with general thickening of all wall layers could be a sign of chronic fibrotic disease.

### **5.3 CEUS perfusion measurements of bowel**

In paper III the feasibility of absolute perfusion measurement of the bowel wall was demonstrated. Although, technically challenging the examination and post-examination analysis could be performed in most of the patients and the results had a fair degree of intraobserver reproducibility. The most technically difficult part was the examination of the healthy bowel and the scaling procedure. Erroneous scaling will cause faulty blood volumes which again will cause errors in the blood flow estimate. The small ROIS in the thin healthy intestinal wall causes noisy time-intensity data which in turn can cause a large variation in the mean transit time estimate. This was probably reflected in the large range of perfusion parameters that we found, particularly in the healthy subjects

Several authors have attempted to measure the local perfusion in the GI wall with various methods either with imaging methods such as CT, MRI and US (95-100) or more invasive methodology such as per-operative laser Doppler or isotope wash out techniques (101-103). However, very few studies report absolute values of perfusion and none recently. Those that do have correlated their relative values to the actual blood flow measurements in segments of the bowel during open abdominal surgery and subsequently derived absolute values.

Hulten et al. using a wash-out technique with a radioactive isotope of Krypton found that blood flow in the small bowel was 38 (17-75) ml/min/100g and the colon 18 (8-35) ml/min/100g tissue in healthy volunteers (104;105). Ahn et al. found similar results with per-operative laser Doppler (Jejunum  $38 \pm 15$  ml/min/100g and ileum 30

$\pm 13$  ml ml/min/100g tissue), but when measuring through an endoscope in patients not under general anaesthesia, he found significantly higher flow results in the colon:  $37 \pm 10.4$  ml/min/100 ml tissue (101;102). Studies of patients with CD indicate that there is increased flow in the colon in the acute phase and reduced in more chronic disease.

The same studies show no increase of flow in the small intestine in the acute phase, but a decrease in chronic disease (103;106). However, laser-Doppler measurements may underestimate high flow and is also affected by wall thickness (102). This could partly explain the reduced perfusion observed in CD by Tateishi (106).

Although our method needs improvement to increase reproducibility, the average values of blood flow are fairly consistent with the values found in previous studies (101-106). As previously mentioned, perfusion modelling also offers more variables than the actual blood flow which could be important for diagnostic differentiation. For instance, neo-vascularisation is a feature of inflammation in CD (107-109) and reduced capillary density is a feature of fibrosis (103;110). These are factors which could be reflected in increased and reduced blood volume, respectively. Increased vascular resistance is another finding in acute CD (111-113) which in turn could affect mean transit time. Interestingly, we found reduced blood volume in the surgical group where more fibrotic disease should be expected as compared to the medical group. However, there were no significant differences between any of the groups with regards to mean transit time. This could be caused by a large variability due to heterogeneous groups or inaccuracy of the current method. A study comparing the micro-vessel density in the resection specimens with the blood volume and the degree of histological inflammation with the mean transit time may further enhance our understanding.

#### **5.4 Fibrosis and inflammation**

As stated previously there are some US findings which could be useful in the differentiation of fibrotic and inflammatory disease in CD. Factors indicating inflammation are a thickened GI wall with loss of stratification, increased Doppler signals from the GI wall and a thickened submucosa. Preserved stratification in a thickened GI segment suggests fibrosis (52). CEUS can also be used to detect



---

increased vascularity or blood flow within the GI wall thus indicating an area of inflammation (38;62;63) although there is conflicting evidence (98).

The papers presented in this thesis show that US findings indicating a mainly fibrotic CD lesion are the thickening of the muscularis mucosa, hypo-echoic elements in the submucosal layer, a combination of GI wall thickening and overall thickening of all US layers, as well as reduced blood volume and flow. US findings supporting the presence of a mainly inflammatory CD lesion are overall thickening of the bowel wall and thickening of the submucosa together with a normal blood volume and flow. We did not find significant differences in stratification between the patients receiving medical or surgical treatment. In paper I some or all of the US wall layers could be detected in all sections, while in paper III, total loss of stratification was present in only 4 patients. This suggests that loss of stratification might not be a promising marker of acute inflammation.

## **5.5 Other limitations:**

In this thesis various US techniques have been used. With the introduction of a new technique the examiner's learning curve might affect reproducibility. The primary investigator performed the examination and inclusion in paper I under close supervision with experienced investigators. Before inclusion in paper II and III the primary investigator had altogether two years' experience of clinical US and 6 months of intensified training focused on bowel US.

When introducing a new method it should be compared to a reference standard. For CD this is the resection specimen examined by the pathologist. For most patients this is not available and those who are operated have more serious and long standing disease than others. Typical histological findings for the whole GI wall in people receiving only medical therapy such as in paper III are therefore not known.

In paper I, the findings were evaluated by several investigators, but not blinded and decision was reached by consensus. In paper II a randomly selected subgroup was examined by another operator to investigate interobserver variability. Only some of the

measurements were repeated, however, and theoretically the variability could be larger in other locations. The results from paper III should be viewed with some caution as the perfusion method has not been validated.

## **5.6 Conclusions and future perspectives**

In summary, the normal GI wall thickness is generally below 2 mm regardless of fasting state or other demographic factors. In CD the GI wall is thickened and while the submucosa is thickened in acute disease the development of fibrosis seems to cause a thickening of all wall layers that can be discerned with US. There are typical histological findings in CD representing chronic inflammation and fibrosis which can be recognised with US. There were no differences in perfusion between healthy volunteers and patients with an acute flare up, but patients with chronic disease needing surgery had lower blood volume and flow.

Future work should involve a comparison of the perfusion parameters with histological findings, particularly micro-vessel density. Also the usefulness of these parameters in predicting prognosis and treatment effect should be tested in prospective studies. The perfusion model must be validated using a gold standard and the analysis simplified before implementation in clinical work. The challenges with absolute perfusion analysis of the GI wall can be partially overcome by improving microbubble and US technology. 3D contrast ultrasound will improve motion correction as there will be no out-of-plane motion and also reduce the problem of sampling error. Furthermore, more stable microbubbles will allow multiple injections from the same vial allowing the scaling to be done using a second low-dose injection when looking at a large artery. CD is a debilitating disease concerning a relatively large population of young people. The development and improvement of simple, objective and non-harmful diagnostic tools is one way of making it easier for these patients to live with the disease.

---

---

## REFERENCES

- (1) Crohn BB, Ginzburg L, Oppenheimer GD. Regional ileitis: a pathologic and clinical entity. 1932. *Mt Sinai J Med* 2000 May;67(3):263-8.
- (2) Fazio VW, Aufses AH, Jr. Evolution of surgery for Crohn's disease: a century of progress. *Dis Colon Rectum* 1999 Aug;42(8):979-88.
- (3) Molodecky NA, Soon IS, Rabi DM, Ghali WA, Ferris M, Chernoff G, et al. Increasing incidence and prevalence of the inflammatory bowel diseases with time, based on systematic review. *Gastroenterology* 2012 Jan;142(1):46-54.
- (4) Perminow G, Frigessi A, Rydning A, Nakstad B, Vatn MH. Incidence and clinical presentation of IBD in children: comparison between prospective and retrospective data in a selected Norwegian population. *Scand J Gastroenterol* 2006 Dec;41(12):1433-9.
- (5) Perminow G, Brackmann S, Lyckander LG, Franke A, Borthne A, Rydning A, et al. A characterization in childhood inflammatory bowel disease, a new population-based inception cohort from South-Eastern Norway, 2005-07, showing increased incidence in Crohn's disease. *Scand J Gastroenterol* 2009;44(4):446-56.
- (6) Moum B, Vatn MH, Ekbohm A, Aadland E, Fausa O, Lygren I, et al. Incidence of Crohn's disease in four counties in southeastern Norway, 1990-93. A prospective population-based study. The Inflammatory Bowel South-Eastern Norway (IBSEN) Study Group of Gastroenterologists. *Scand J Gastroenterol* 1996 Apr;31(4):355-61.
- (7) Benevento G, Avellini C, Terrosu G, Geraci M, Lodolo I, Sorrentino D. Diagnosis and assessment of Crohn's disease: the present and the future. *Expert Rev Gastroenterol Hepatol* 2010 Dec;4(6):757-66.
- (8) Nikolaus S, Schreiber S. Diagnostics of inflammatory bowel disease. *Gastroenterology* 2007 Nov;133(5):1670-89.
- (9) Ingle SB, Loftus EV, Jr. The natural history of perianal Crohn's disease. *Dig Liver Dis* 2007 Oct;39(10):963-9.
- (10) Kaplan GG, Jackson T, Sands BE, Frisch M, Andersson RE, Korzenik J. The risk of developing Crohn's disease after an appendectomy: a meta-analysis. *Am J Gastroenterol* 2008 Nov;103(11):2925-31.
- (11) Bergamaschi G, Di SA, Albertini R, Ardizzone S, Biancheri P, Bonetti E, et al. Prevalence and pathogenesis of anemia in inflammatory bowel disease.

---

Influence of anti-tumor necrosis factor-alpha treatment. *Haematologica* 2010 Feb;95(2):199-205.

- (12) Vilela EG, Torres HO, Martins FP, Ferrari ML, Andrade MM, Cunha AS. Evaluation of inflammatory activity in Crohn's disease and ulcerative colitis. *World J Gastroenterol* 2012 Mar 7;18(9):872-81.
- (13) Jahnsen J, Roseth AG, Aadland E. [Measurement of calprotectin in faeces]. *Tidsskr Nor Laegeforen* 2009 Apr 16;129(8):743-5.
- (14) Meadows TR, Batsakis JG. Histopathological spectrum of regional enteritis. *Arch Surg* 1963 Dec;87:976-82.
- (15) Morson BC. Histopathology of Crohn's disease. *Scand J Gastroenterol* 1971;6(7):573-5.
- (16) Odze R. Diagnostic problems and advances in inflammatory bowel disease. *Modern pathology* 2003;16(4):347-58.
- (17) Price AB, Morson BC. Inflammatory bowel disease: the surgical pathology of Crohn's disease and ulcerative colitis. *Hum Pathol* 1975 Jan;6(1):7-29.
- (18) Rubio CA, Orrego A, Nesi G, Finkel Y. Frequency of epithelioid granulomas in colonoscopic biopsy specimens from paediatric and adult patients with Crohn's colitis. *J Clin Pathol* 2007 Nov;60(11):1268-72.
- (19) Lee EY, Stenson WF, DeSchryver-Keckskemeti K. Thickening of muscularis mucosae in Crohn's disease. *Mod Pathol* 1991 Jan;4(1):87-90.
- (20) Gramlich T, Petras RE. Pathology of inflammatory bowel disease. *Semin Pediatr Surg* 2007 Aug;16(3):154-63.
- (21) Daperno M, D'Haens G, Van AG, Baert F, Bulois P, Maunoury V, et al. Development and validation of a new, simplified endoscopic activity score for Crohn's disease: the SES-CD. *Gastrointest Endosc* 2004 Oct;60(4):505-12.
- (22) Saibeni S, Rondonotti E, Iozzelli A, Spina L, Tontini GE, Cavallaro F, et al. Imaging of the small bowel in Crohn's disease: a review of old and new techniques. *World J Gastroenterol* 2007 Jun 28;13(24):3279-87.
- (23) Panes J, Bouzas R, Chaparro M, Garcia-Sanchez V, Gisbert JP, Martinez de GB, et al. Systematic review: the use of ultrasonography, computed tomography and magnetic resonance imaging for the diagnosis, assessment of activity and abdominal complications of Crohn's disease. *Aliment Pharmacol Ther* 2011 Jul;34(2):125-45.
- (24) Pariente B, Peyrin-Biroulet L, Cohen L, Zagdanski AM, Colombel JF. Gastroenterology review and perspective: the role of cross-sectional imaging in

- 
- evaluating bowel damage in Crohn disease. *AJR Am J Roentgenol* 2011 Jul;197(1):42-9.
- (25) Ødegaard S, Gilja OH, Matre K. *Innføring i abdominal ultrasonografi*. Bergen: Fagbokforlaget; 2009.
- (26) Kimmey MB, Martin RW, Haggitt RC, Wang KY, Franklin DW, Silverstein FE. Histologic correlates of gastrointestinal ultrasound images. *Gastroenterology* 1989 Feb;96(2 Pt 1):433-41.
- (27) Odegaard S, Kimmey MB, Martin RW, Yee HC, Cheung AH, Silverstein FE. The effects of applied pressure on the thickness, layers, and echogenicity of gastrointestinal wall ultrasound images. *Gastrointest Endosc* 1992 May;38(3):351-6.
- (28) Odegaard S, Kimmey MB. Location of the muscularis mucosae on high frequency gastrointestinal ultrasound images. *European journal of ultrasound* 1994;1:39-50.
- (29) Odegaard S, Kimmey MB, Cheung AHS, Nesje LB, Morild I, Silverstein FE, et al. High frequency endosonography of gastrointestinal arteries: potential and limitations in vitro. *European journal of ultrasound* 1995;2:313-9.
- (30) Wiersema MJ, Wiersema LM. High-resolution 25-megahertz ultrasonography of the gastrointestinal wall: histologic correlates. *Gastrointest Endosc* 1993 Jul;39(4):499-504.
- (31) Njemanze PC, Njemanze J, Skelton A, Akudo A, Akagha O, Chukwu AA, et al. High-frequency ultrasound imaging of the duodenum and colon in patients with symptomatic giardiasis in comparison to amebiasis and healthy subjects. *J Gastroenterol Hepatol* 2008 Jul;23(7 Pt 2):e34-e42.
- (32) Haber HP, Stern M. Intestinal ultrasonography in children and young adults: bowel wall thickness is age dependent. *J Ultrasound Med* 2000 May;19(5):315-21.
- (33) Huh CH, Bhutani MS, Farfan EB, Bolch WE. Individual variations in mucosa and total wall thickness in the stomach and rectum assessed via endoscopic ultrasound. *Physiol Meas* 2003 Nov;24(4):N15-N22.
- (34) Pallotta N, Baccini F, Corazziari E. Contrast ultrasonography of the normal small bowel. *Ultrasound Med Biol* 1999 Nov;25(9):1335-40.
- (35) Sandek A, Bauditz J, Swidsinski A, Buhner S, Weber-Eibel J, von HS, et al. Altered intestinal function in patients with chronic heart failure. *J Am Coll Cardiol* 2007 Oct 16;50(16):1561-9.

- 
- (36) Castiglione F, Bucci L, Pesce G, De Palma GD, Camera L, Cipolletta F, et al. Oral contrast-enhanced sonography for the diagnosis and grading of postsurgical recurrence of Crohn's disease. *Inflamm Bowel Dis* 2008 Apr 8.
- (37) Kunihiro K, Hata J, Manabe N, Mitsuoka Y, Tanaka S, Haruma K, et al. Predicting the need for surgery in Crohn's disease with contrast harmonic ultrasound. *Scand J Gastroenterol* 2007 May;42(5):577-85.
- (38) Migaleddu V, Scanu AM, Quaia E, Rocca PC, Dore MP, Scanu D, et al. Contrast-enhanced ultrasonographic evaluation of inflammatory activity in Crohn's disease. *Gastroenterology* 2009 Jul;137(1):43-52.
- (39) Pallotta N, Barberani F, Hassan NA, Guagnozzi D, Vincoli G, Corazziari E. Effect of infliximab on small bowel stenoses in patients with Crohn's disease. *World J Gastroenterol* 2008 Mar 28;14(12):1885-90.
- (40) Serra C, Menozzi G, Labate AM, Giangregorio F, Gionchetti P, Beltrami M, et al. Ultrasound assessment of vascularization of the thickened terminal ileum wall in Crohn's disease patients using a low-mechanical index real-time scanning technique with a second generation ultrasound contrast agent. *Eur J Radiol* 2007 Apr;62(1):114-21.
- (41) Nylund K, Odegaard S, Hausken T, Folvik G, Lied GA, Viola I, et al. Sonography of the small intestine. *World J Gastroenterol* 2009 Mar 21;15(11):1319-30.
- (42) Nylund K, Hausken T, Gilja OH. Ultrasound and inflammatory bowel disease. *Ultrasound Q* 2010 Mar;26(1):3-15.
- (43) Naevdal EF, Nylund K, Gilja OH. [Transabdominal ultrasonography inflammatory intestinal syndrome]. *Tidsskr Nor Laegeforen* 2010 Nov 18;130(22):2230-4.
- (44) Faure C, Belarbi N, Mougnot JF, Besnard M, Hugot JP, Cezard JP, et al. Ultrasonographic assessment of inflammatory bowel disease in children: comparison with ileocolonoscopy. *J Pediatr* 1997 Jan;130(1):147-51.
- (45) Hata J, Haruma K, Suenaga K, Yoshihara M, Yamamoto G, Tanaka S, et al. Ultrasonographic assessment of inflammatory bowel disease. *Am J Gastroenterol* 1992 Apr;87(4):443-7.
- (46) Solvig J, Ekberg O, Lindgren S, Floren CH, Nilsson P. Ultrasound examination of the small bowel: comparison with enteroclysis in patients with Crohn disease. *Abdom Imaging* 1995 Jul;20(4):323-6.
- (47) Gasche C, Moser G, Turetschek K, Schober E, Moeschl P, Oberhuber G. Transabdominal bowel sonography for the detection of intestinal complications in Crohn's disease. *Gut* 1999 Jan;44(1):112-7.

- 
- (48) Maconi G, Sampietro GM, Parente F, Pompili G, Russo A, Cristaldi M, et al. Contrast radiology, computed tomography and ultrasonography in detecting internal fistulas and intra-abdominal abscesses in Crohn's disease: a prospective comparative study. *Am J Gastroenterol* 2003 Jul;98(7):1545-55.
- (49) Maconi G, Bollani S, Bianchi PG. Ultrasonographic detection of intestinal complications in Crohn's disease. *Dig Dis Sci* 1996 Aug;41(8):1643-8.
- (50) Schreyer AG, Menzel C, Friedrich C, Poschenrieder F, Egger L, Dornia C, et al. Comparison of high-resolution ultrasound and MR-enterography in patients with inflammatory bowel disease. *World J Gastroenterol* 2011 Feb 28;17(8):1018-25.
- (51) Maconi G, Parente F, Bollani S, Cesana B, Bianchi PG. Abdominal ultrasound in the assessment of extent and activity of Crohn's disease: clinical significance and implication of bowel wall thickening. *Am J Gastroenterol* 1996 Aug;91(8):1604-9.
- (52) Maconi G, Carsana L, Fociani P, Sampietro GM, Ardizzone S, Cristaldi M, et al. Small bowel stenosis in Crohn's disease: clinical, biochemical and ultrasonographic evaluation of histological features. *Aliment Pharmacol Ther* 2003 Oct 1;18(7):749-56.
- (53) Dietrich CF, Jedrzejczyk M, Ignee A. Sonographic assessment of splanchnic arteries and the bowel wall. *Eur J Radiol* 2007 Nov;64(2):202-12.
- (54) Byrne MF, Farrell MA, Abass S, Fitzgerald A, Varghese JC, Thornton F, et al. Assessment of Crohn's disease activity by Doppler sonography of the superior mesenteric artery, clinical evaluation and the Crohn's disease activity index: a prospective study. *Clin Radiol* 2001 Dec;56(12):973-8.
- (55) Van Oostayen JA, Wasser MN, Griffioen G, van Hogezaand RA, Lamers CB, de Roos A. Diagnosis of Crohn's ileitis and monitoring of disease activity: value of Doppler ultrasound of superior mesenteric artery flow. *Am J Gastroenterol* 1998 Jan;93(1):88-91.
- (56) Maconi G, Parente F, Bollani S, Imbesi V, Ardizzone S, Russo A, et al. Factors affecting splanchnic haemodynamics in Crohn's disease: a prospective controlled study using Doppler ultrasound. *Gut* 1998 Nov;43(5):645-50.
- (57) Esteban JM, Maldonado L, Sanchiz V, Minguez M, Benages A. Activity of Crohn's disease assessed by colour Doppler ultrasound analysis of the affected loops. *Eur Radiol* 2001;11(8):1423-8.
- (58) Spalinger J, Patriquin H, Miron MC, Marx G, Herzog D, Dubois J, et al. Doppler US in patients with Crohn's disease: vessel density in the diseased bowel reflects disease activity. *Radiology* 2000 Dec;217(3):787-91.



- 
- (59) Scholbach T, Herrero I, Scholbach J. Dynamic color Doppler sonography of intestinal wall in patients with Crohn disease compared with healthy subjects. *J Pediatr Gastroenterol Nutr* 2004 Nov;39(5):524-8.
- (60) Sjekavica I, Barbaric-Babic V, Krznicaric Z, Molnar M, Cukovic-Cavka S, Stern-Padovan R. Assessment of Crohn's disease activity by doppler ultrasound of superior mesenteric artery and mural arteries in thickened bowel wall: cross-sectional study. *Croat Med J* 2007 Dec;48(6):822-30.
- (61) Yekeler E, Danalioglu A, Movasseghi B, Yilmaz S, Karaca C, Kaymakoglu S, et al. Crohn disease activity evaluated by Doppler ultrasonography of the superior mesenteric artery and the affected small-bowel segments. *J Ultrasound Med* 2005 Jan;24(1):59-65.
- (62) Girlich C, Jung EM, Huber E, Ott C, Iesalnieks I, Schreyer A, et al. Comparison between preoperative quantitative assessment of bowel wall vascularization by contrast-enhanced ultrasound and operative macroscopic findings and results of histopathological scoring in Crohn's disease. *Ultraschall Med* 2011 Apr;32(2):154-9.
- (63) Ripolles T, Rausell N, Paredes JM, Grau E, Martinez MJ, Vizuete J. Effectiveness of contrast-enhanced ultrasound for characterisation of intestinal inflammation in Crohn's disease: A comparison with surgical histopathology analysis. *J Crohns Colitis* 2012 Apr 4.
- (64) Quaia E, De PL, Stocca T, Cabibbo B, Casagrande F, Cova MA. The Value of Small Bowel Wall Contrast Enhancement After Sulfur Hexafluoride-Filled Microbubble Injection to Differentiate Inflammatory from Fibrotic Strictures in Patients with Crohn's Disease. *Ultrasound Med Biol* 2012 Aug;38(8):1324-32.
- (65) Cosgrove D, Eckersley R. Contrast-Enhanced Ultrasound: Basic Physics and Technology Overview. In: Lencioni R, editor. *Enhancing the Role of Ultrasound with Contrast Agents*. Milan: Springer Verlag; 2006. p. 3-14.
- (66) Postema M, Gilja OH. Contrast-enhanced and targeted ultrasound. *World J Gastroenterol* 2011 Jan 7;17(1):28-41.
- (67) Schneider M. SonoVue, a new ultrasound contrast agent. *Eur Radiol* 1999;9 Suppl 3:S347-S348.
- (68) de JN, Bouakaz A, Frinking P. Basic acoustic properties of microbubbles. *Echocardiography* 2002 Apr;19(3):229-40.
- (69) Simpson DH, Chin CT, Burns PN. Pulse inversion Doppler: a new method for detecting nonlinear echoes from microbubble contrast agents. *IEEE Trans Ultrason Ferroelectr Freq Control* 1999;46(2):372-82.

- 
- (70) Phillips P, Gardner E. Contrast-agent detection and quantification. *Eur Radiol* 2004 Oct;14 Suppl 8:4-10.
- (71) Lampaskis M, Averkiou M. Investigation of the relationship of nonlinear backscattered ultrasound intensity with microbubble concentration at low MI. *Ultrasound Med Biol* 2010 Feb;36(2):306-12.
- (72) Rognin NG, Frinking P, Costa M, Arditi M. In-vivo perfusion quantification by contrast ultrasound: Validation of the use of linearized video data vs. raw RF data. 2008 p. 1690-3.
- (73) Wei K, Jayaweera AR, Firoozan S, Linka A, Skyba DM, Kaul S. Quantification of myocardial blood flow with ultrasound-induced destruction of microbubbles administered as a constant venous infusion. *Circulation* 1998 Feb 10;97(5):473-83.
- (74) Hudson JM, Karshafian R, Burns PN. Quantification of flow using ultrasound and microbubbles: a disruption replenishment model based on physical principles. *Ultrasound Med Biol* 2009 Dec;35(12):2007-20.
- (75) Lassau N, Chebil M, Chami L, Bidault S, Girard E, Roche A. Dynamic contrast-enhanced ultrasonography (DCE-US): a new tool for the early evaluation of antiangiogenic treatment. *Target Oncol* 2010 Mar;5(1):53-8.
- (76) Ostergaard L. Principles of cerebral perfusion imaging by bolus tracking. *J Magn Reson Imaging* 2005 Dec;22(6):710-7.
- (77) Gauthier M, Tabarout F, Leguerney I, Polrot M, Pitre S, Peronneau P, et al. Assessment of quantitative perfusion parameters by dynamic contrast-enhanced sonography using a deconvolution method: an in vitro and in vivo study. *J Ultrasound Med* 2012 Apr;31(4):595-608.
- (78) Metzl M, Jirik R, Harabis V, Kolar R. Quantitative Ultrasound Perfusion Analysis In Vitro . *Proceedings of Biosignal 2010: Analysis of Biomedical Signals and Images* 2010;20:279-83.
- (79) Jirik R, Nylund K, Taxt T, Mezl M, Harabis V, Kolar R, et al. Ultrasound Perfusion Analysis Combining Bolus Tracking and Replenishment. 2012 IEEE International Ultrasonics Symposium, Dresden, Germany . 2012.

Ref Type: Unpublished Work

- (80) Jirik R, Nylund K, Gilja OH, Mezl M, Harabis V, Kolar R, et al. Multichannel Blind Ultrasound Perfusion Analysis Combining Bolus-Tracking and Burst-Replenishment. 2012.

Ref Type: Unpublished Work

- 
- (81) Best WR, Beckett JM, Singleton JW, Kern F, Jr. Development of a Crohn's disease activity index. National Cooperative Crohn's Disease Study. *Gastroenterology* 1976 Mar;70(3):439-44.
- (82) Harvey RF, Bradshaw JM. A simple index of Crohn's-disease activity. *Lancet* 1980 Mar 8;1(8167):514.
- (83) Kimmey MB, Silverstein FE, Haggitt RC, Shuman WP, Mack LA, Rohrmann CA, et al. Cross-sectional imaging method. A system to compare ultrasound, computed tomography, and magnetic resonance with histologic findings. *Invest Radiol* 1987 Mar;22(3):227-31.
- (84) Kolar R, Jirik R, Harabis V, Nylund K, Gilja OH. Registration of ultrasound contrast images for perfusion analysis. 2009 p. 1251-4.
- (85) Schafer S, Angelelli P, Nylund K, Gilja OH, Tonnie K. Registration of ultrasonography sequences based on temporal regions. 2011 p. 749-54.
- (86) Fleischer AC, Muhletaler CA, James AE, Jr. Sonographic assessment of the bowel wall. *AJR Am J Roentgenol* 1981 May;136(5):887-91.
- (87) Fraquelli M, Colli A, Casazza G, Paggi S, Colucci A, Massironi S, et al. Role of US in detection of Crohn disease: meta-analysis. *Radiology* 2005 Jul;236(1):95-101.
- (88) Calabrese E, Petruzzello C, Onali S, Condino G, Zorzi F, Pallone F, et al. Severity of postoperative recurrence in Crohn's disease: correlation between endoscopic and sonographic findings. *Inflamm Bowel Dis* 2009 Nov;15(11):1635-42.
- (89) Hertz AF. The ileo-caecal sphincter. *J Physiol* 1913 Oct 17;47(1-2):54-6.
- (90) Graham MF, Diegelmann RF, Elson CO, Lindblad WJ, Gotschalk N, Gay S, et al. Collagen content and types in the intestinal strictures of Crohn's disease. *Gastroenterology* 1988 Feb;94(2):257-65.
- (91) Dvorak AM, Osage JE, Monahan RA, Dickersin GR. Crohn's disease: transmission electron microscopic studies. III. Target tissues. Proliferation of and injury to smooth muscle and the autonomic nervous system. *Hum Pathol* 1980 Nov;11(6):620-34.
- (92) Castiglione F, de S, I, Cozzolino A, Rispo A, Manguso F, Del Vecchio BG, et al. Bowel wall thickness at abdominal ultrasound and the one-year-risk of surgery in patients with Crohn's disease. *Am J Gastroenterol* 2004 Oct;99(10):1977-83.
- (93) Rigazio C, Ercole E, Laudi C, Daperno M, Lavagna A, Crocella L, et al. Abdominal bowel ultrasound can predict the risk of surgery in Crohn's disease:

- 
- proposal of an ultrasonographic score. *Scand J Gastroenterol* 2009;44(5):585-93.
- (94) Fritscher-Ravens A, Ellrichmann M, Nikolaus S, Arlt A, Sergueev P, Kuehbacher T, et al. 463 Endoscopic Ultrasound of the Colon for the Differentiation of Crohn's Disease and Ulcerative Colitis in Comparison to Healthy Controls - A Prospective, Blinded, Comparative Study. *Gastrointestinal Endoscopy* 2011 Apr;73(4, Supplement):AB128.
- (95) Girlich C, Jung EM, Iesalnieks I, Schreyer AG, Zorger N, Strauch U, et al. Quantitative assessment of bowel wall vascularisation in Crohn's disease with contrast-enhanced ultrasound and perfusion analysis. *Clin Hemorheol Microcirc* 2009;43(1):141-8.
- (96) Khan S, Goh V, Tam E, Wellsted D, Halligan S. Perfusion CT assessment of the colon and rectum: feasibility of quantification of bowel wall perfusion and vascularization. *Eur J Radiol* 2012 May;81(5):821-4.
- (97) Rottgen R, Grandke T, Grieser C, Lehmkuhl L, Hamm B, Ludemann L. Measurement of MRI enhancement kinetics for evaluation of inflammatory activity in Crohn's disease. *Clin Imaging* 2010 Jan;34(1):29-35.
- (98) Schirin-Sokhan R, Winograd R, Tischendorf S, Wasmuth HE, Streetz K, Tacke F, et al. Assessment of inflammatory and fibrotic stenoses in patients with Crohn's disease using contrast-enhanced ultrasound and computerized algorithm: a pilot study. *Digestion* 2011;83(4):263-8.
- (99) Taylor SA, Punwani S, Rodriguez-Justo M, Bainbridge A, Greenhalgh R, De VE, et al. Mural Crohn disease: correlation of dynamic contrast-enhanced MR imaging findings with angiogenesis and inflammation at histologic examination--pilot study. *Radiology* 2009 May;251(2):369-79.
- (100) Wong D.D., Forbes G.M., Zelesco M., Mason R., Pawlik J., Mendelson RM. Crohn's disease activity: quantitative contrast-enhanced ultrasound assessment. *Abdominal Imaging* 2011 Aug 10.
- (101) Ahn H, Lindhagen J, Nilsson GE, Oberg PA, Lundgren O. Assessment of blood flow in the small intestine with laser Doppler flowmetry. *Scand J Gastroenterol* 1986 Sep;21(7):863-70.
- (102) Ahn H, Lindhagen J, Lundgren O. Measurement of colonic blood flow with laser Doppler flowmetry. *Scand J Gastroenterol* 1986 Sep;21(7):871-80.
- (103) Hulten L, Lindhagen J, Lundgren O, Fasth S, Ahren C. Regional intestinal blood flow in ulcerative colitis and Crohn's disease. *Gastroenterology* 1977 Mar;72(3):388-96.

- 
- (104) Hulten L, Jodal M, Lindhagen J, Lundgren O. Blood flow in the small intestine of cat and man as analyzed by an inert gas washout technique. *Gastroenterology* 1976 Jan;70(1):45-51.
- (105) Hulten L, Jodal M, Lindhagen J, Lundgren O. Colonic blood flow in cat and man as analyzed by an inert gas washout technique. *Gastroenterology* 1976 Jan;70(1):36-44.
- (106) Tateishi S, Arima S, Futami K. Assessment of blood flow in the small intestine by laser Doppler flowmetry: comparison of healthy small intestine and small intestine in Crohn's disease. *J Gastroenterol* 1997 Aug;32(4):457-63.
- (107) Alkim C, Savas B, Ensari A, Alkim H, Dagli U, Parlak E, et al. Expression of p53, VEGF, microvessel density, and cyclin-D1 in noncancerous tissue of inflammatory bowel disease. *Dig Dis Sci* 2009 Sep;54(9):1979-84.
- (108) Danese S, Sans M, de la MC, Graziani C, West G, Phillips MH, et al. Angiogenesis as a novel component of inflammatory bowel disease pathogenesis. *Gastroenterology* 2006 Jun;130(7):2060-73.
- (109) Konerding MA, Turhan A, Ravnic DJ, Lin M, Fuchs C, Secomb TW, et al. Inflammation-induced intussusceptive angiogenesis in murine colitis. *Anat Rec (Hoboken)* 2010 May;293(5):849-57.
- (110) Kruschewski M, Busch C, Dorner A, Lierse W. Angio-architecture of the colon in Crohn disease and ulcerative colitis. Light microscopy and scanning electron microscopy studies with reference to the morphology of the healthy large intestine. *Langenbecks Arch Chir* 1995;380(5):253-9.
- (111) Funayama Y, Sasaki I, Naito H, Fukushima K, Matsuno S, Masuda T. Remodeling of vascular wall in Crohn's disease. *Dig Dis Sci* 1999 Nov;44(11):2319-23.
- (112) Hatoum OA, Binion DG, Otterson MF, Gutterman DD. Acquired microvascular dysfunction in inflammatory bowel disease: Loss of nitric oxide-mediated vasodilation. *Gastroenterology* 2003 Jul;125(1):58-69.
- (113) Mori M, Stokes KY, Vowinkel T, Watanabe N, Elrod JW, Harris NR, et al. Colonic blood flow responses in experimental colitis: time course and underlying mechanisms. *Am J Physiol Gastrointest Liver Physiol* 2005 Dec;289(6):G1024-G1029.