

IMMUNOHISTOCHEMICAL DETECTION OF p53 IN NON-MALIGNANT AND MALIGNANT ORAL LESIONS ASSOCIATED WITH SNUFF DIPPING IN THE SUDAN AND SWEDEN

Salah O. IBRAHIM^{1,2,3,7}, Anne C. JOHANNESSEN¹, Ali M. IDRIS⁴, Jan M. HIRSCH⁵, Endre N. VASSTRAND², Bengt MAGNUSSON⁶ and Rune NILSEN³

Departments of ¹Oral Pathology and Forensic Odontology and ²Biochemistry and Molecular Biology; ³Center for International Health, University of Bergen, Norway; ⁴The Toombak Research Center and Oral Cancer Campaign, Khartoum, Sudan; Departments of ⁵Oral and Maxillofacial Surgery, The University Hospital of Uppsala and ⁶Oral Pathology, Faculty of Odontology, University of Göteborg, Sweden.

Immunohistochemistry was used to examine the expression of p53 in pre-malignant oral lesions and oral squamous-cell carcinomas (SCCs) from Swedish and Sudanese snuff-dippers, as well as in pre-malignant oral lesions and oral SCCs from non-snuff-dippers from the Sudan, Sweden and Norway. Of the 14 SCCs from Sudanese snuff-dippers, 21% (3/14) expressed p53. Of the 14, 60 and 41 SCCs from non-snuff-dippers from the Sudan, Sweden and Norway, 64% (9/14), 65% (39/60) and 68% (28/41) expressed p53, respectively. A statistically significant difference in expression of p53 was found in SCCs from Sudanese snuff-dippers compared to those from non-snuff-dippers from all/or any of the 3 countries. None of the suspected pre-malignant oral lesions from Sudanese snuff dippers or non-snuff-dippers expressed p53. Only 2 out of the 15 oral fibro-epithelial hyperplastic lesions from Swedish snuff-dippers expressed p53. Some of the oral epithelial dysplastic lesions, as well as the carcinoma *in situ* lesions from Norwegian non-snuff-dippers, expressed p53, while the oral fibro-epithelial hyperplastic lesions did not. The low relative frequency of p53 expression found in oral SCCs from snuff-dippers compared to those from non-snuff-dippers might suggest differences in mechanisms of oncogenic action induced by snuff. Alternatively, the pathogenesis of malignant oral lesions from snuff-dippers may follow a p53-independent pathway. In view of the unusually high levels of the tobacco-specific nitrosamines (TSNA) found in the type of snuff used in the Sudan, investigations of p53 mutations or oncogenes are needed.

© 1996 Wiley-Liss, Inc.

Squamous-cell carcinoma (SCC) of the head and neck ranks as the sixth most common malignant neoplasm world-wide (Parkin *et al.*, 1993). In the developing countries, oral cavity and pharynx combined represent the third most common site of cancer (Johnson, 1991). The number of cases of this type of cancer is particularly high in Asia (Parkin *et al.*, 1993) as well as in Africa (Idris *et al.*, 1995), and is now also increasing in the developed countries (Johnson, 1991). The etiology of oral SCCs has been associated with the use of various forms of tobacco and/or alcohol consumption (Binnie *et al.*, 1983; Johnson and Warnakulasuriya, 1993). In Norway, the use of snuff is relatively uncommon (Kraft and Svendsen, 1996) and oral-cancer incidence is also low (Hakulinen *et al.*, 1986). The prevalence of oral cancer is particularly high in the Sudan (16.58%; Idris *et al.*, 1995) compared to Sweden (2.1%; Östman *et al.*, 1995) and Norway (1.9% for males; 2.5% for females; Hakulinen *et al.*, 1986). Descriptive and case-control studies from the Sudan (Elbeshir *et al.*, 1989; Idris *et al.*, 1994, 1995) have documented an association between oral-cancer incidence and use of snuff (a mixture of tobacco and sodium bicarbonate). In Sweden, a possible link between oral-cancer incidence and snuff dipping has also been suggested (Hirsch and Johansson, 1983; Hirsch *et al.*, 1984).

The tumor-suppressor gene p53 encodes a nuclear phosphoprotein that plays an important role in cell proliferation and differentiation (Harlow *et al.*, 1985; Finlay *et al.*, 1989). A deregulation of cell growth and differentiation occurs when

this gene is deactivated by mutation or deletion, or by a virus (Harris, 1991). Several studies have reported the relationship between cigarette smoking, alcohol consumption (Field *et al.*, 1991; Brennan *et al.*, 1995; Lazarus *et al.*, 1996), betel and tobacco chewing (Kaur *et al.*, 1994) and expression of p53 in oral SCCs. However, some studies have shown a lower prevalence of p53 expression in oral SCCs in tobacco chewers (Ranasinghe *et al.*, 1993a, b; Thomas *et al.*, 1994).

The objective of the present study was to determine the relative frequency of p53 expression in suspected oral pre-malignant lesions and in oral SCCs in relation to use of snuff, as a marker for p53 mutation.

MATERIAL AND METHODS

During the period November 1993 to August 1995, 39 patients (29 males and 10 females, mean age 56.9 ± 2.44 SE, SD 15.28, range 18–94 years) with suspected pre-malignant or malignant oral lesions presented at the Oral Surgery Department of the Khartoum Teaching Dental Hospital, Khartoum, Sudan. The patients were interviewed (Idris *et al.*, 1994) on snuff use, years of usage, frequency of daily consumption, position of quid placement in the mouth and use of other tobacco products. Of these patients, 17 males (59%) were found to dip snuff with a mean dipping period of 32 years (Table I), while 5 females (50%) were found to dip snuff with a mean dipping period of 21 years (Table I). The remaining ($n = 17$) patients did not use snuff or any other form of tobacco. From each patient a surgical tissue sample was taken, fixed in 10% buffered formalin and dispatched to the Department of Oral Pathology and Forensic Odontology, University of Bergen, where it was embedded in paraffin.

From the period March 1992 to December 1993, 15 patients (all males, mean age 39.5 ± 1.03 SE, SD 12.5, range 23–74 years) suspected of having snuff-induced oral lesions, presented at the Department of Oral and Maxillofacial Surgery, Faculty of Odontology, Göteborg. The patients were interviewed on snuff use, years of usage, frequency of daily consumption, position of quid placement in the mouth and use of other tobacco products. All these patients were found to dip snuff with a mean dipping period of 11 years (Table I). After detailed history and clinical examination of the lesions, a surgical tissue sample was taken, fixed in 10% buffered formalin, and further embedded in paraffin. From the period March 1988 to December 1993, hospital records of 60 patients (27 males and 33 females, mean age 60.17 ± 1.11 SE, SD

⁷To whom correspondence and reprint requests should be addressed, at the Department of Oral Pathology and Forensic Odontology, Haukeland Hospital, 5021 Bergen-Norway. Fax: 47 55 97 31 58. E-mail: Sosman@gades.uib.no

TABLE I - SITE DISTRIBUTION OF THE ORAL LESIONS (FIBRO-EPITHELIAL HYPERPLASIA, EPITHELIAL DYSPLASIA, CARCINOMA *IN SITU* AND SQUAMOUS-CELL CARCINOMAS) SELECTED FROM THE THREE COUNTRIES

Site	Sudan	Sweden	Norway
Lip (upper or lower) (n = 82)	22	19	41
Intraoral ¹ (n = 92)	17	56	19
Total	39	75	60

¹Including gingiva, tongue, floor of mouth, buccal mucosa and palate.

TABLE II - AGE AND SNUFF EXPOSURE DATA (MEAN \pm SD) AMONG SNUFF DIPPERS FROM THE SUDAN AND SWEDEN

	Age (years)	Hours of daily snuff use	Grams of snuff used daily	Years of snuff use
Sudan (n = 22)				
Males	60 \pm 2.11	18 \pm 6.1	42 \pm 11.2	32 \pm 6.3
Females	52 \pm 1.13	7 \pm 13.2	19 \pm 11.1	21 \pm 2.1
Sweden (n = 15)				
Males	39.5 \pm 12.5	13.1 \pm 3.8	36.1 \pm 17.6	11 \pm 2.3

14.72, range 44–95 years) previously diagnosed with pre-malignant or malignant oral lesions at the Department of Oral and Maxillofacial Surgery, Faculty of Odontology, Göteborg, were randomly selected from the files of the Department of Oral Pathology, Faculty of Odontology, Göteborg. From the hospital records, only 8 patients (6 males and 2 females) reported cigarette smoking, with no further information on the amount smoked daily or weekly. However, no data on alcohol consumption were available. From the period January 1990 to November 1994, hospital records of 60 patients (30 males and 30 females, mean age 64.04 \pm 1.72 SE, SD 14.42, range 31–88 years), previously diagnosed with pre-malignant or malignant oral lesions, were randomly selected from the files of the Department of Pathology, Haukeland University Hospital, Bergen. There were 12 fibro-epithelial hyperplasias, 2 epithelial dysplasias, 5 carcinomas *in situ* and 41 oral SCCs. From the hospital records, only 11 patients (37%, all males) reported cigarette smoking, with no further information on the amount smoked daily or weekly. Similarly, no data on alcohol consumption were available.

The site distributions of the biopsy specimens (n = 174) selected from the Sudan, Sweden and Norway are shown in Table II. Data (except names and other identification numbers) including age, sex, site of the lesion and previous histopathological diagnosis, were made available to the investigators. As positive controls, sections of formalin-fixed, paraffin-embedded tissue specimens from 5 carcinomas of the cervix that were previously p53-positive were included from the Department of Pathology, Haukeland University Hospital, Bergen. As negative controls, formalin-fixed, paraffin-embedded tissue specimens of oral mucosa from 5 normal patients with no history of snuff dipping, cigarette smoking, use of any other form of tobacco and/or alcohol consumption were obtained from the same department.

Tissue preparation

From each biopsy specimen (n = 174), 5 sections (5 μ m) were prepared. One section was stained with hematoxylin and eosin (H. and E.) to evaluate the histopathological diagnosis. The remaining sections were used for immunohistochemistry.

Evaluation of the H. and E.-stained sections

The H. and E.-stained sections were examined with a light microscope. The diagnoses were then confirmed and the lesions were graded as fibro-epithelial hyperplasia, dysplasia (mild, moderate or severe), carcinoma *in situ*, or SCC. The

SCCs were classified as well, moderately or poorly differentiated according to Cawson and Eveson (1987).

Immunohistochemistry

Monoclonal antibodies (MAbs). As described (Ibrahim *et al.*, 1996), 2 MAbs (DO-7 and DO-1) were used for detection of p53.

DO-7 (DAKO-p53, DAKO, Copenhagen, Denmark) recognizes epitopes residing between amino acids (35–45) of human wild-type and mutant p53 (Vojtesek *et al.*, 1992). It was diluted at 1:100 in PBS, pH 7.2, containing 5% BSA. DO-1 (Santa Cruz Biotechnology, Santa Cruz, CA) reacts with an amino-acid terminal epitope (residues 37–45) of human wild-type and mutant p53 (Vojtesek *et al.*, 1992). It was diluted 1:1,000 in PBS/5% BSA.

For immunohistochemistry, a streptavidin-biotin complex protocol was employed. Briefly, tissue sections were deparaffinized in xylene and rehydrated through graded ethanol. Before incubation with the primary MAbs, sections were treated with 0.1% (mg/ml) Protease (bacteroid type xxiv, Sigma, St. Louis, MO) at 37°C for 10 min, and then heated in a microwave oven at a high power setting (700W) and at a lower power setting (425W) for 5 min, respectively. Endogenous peroxidase activity was blocked by using 1% hydrogen peroxide in methanol for 30 min, and the sections were thereafter washed in PBS. The sections were incubated for 30 min with normal rabbit serum (X902, DAKO) diluted 1:10 in PBS/5% BSA, then incubated overnight (18–20 hr) with the primary antibody at room temperature (20–22°C). After washing in PBS, the sections were incubated with biotinylated, rabbit anti-mouse IgG (E354, DAKO) used at a dilution of 1:200 in PBS/5% BSA, for 60 min. The sections were washed in PBS, then incubated for 30 min with an avidin biotin complex (ABC, K355, DAKO). The sections were developed in the peroxidase substrate 3-amino-9-ethylcarbazole (AEC, Vector, Burlingame, CA) for 30 min, washed and slightly counterstained with hematoxylin (20 sec) dissolved in water and mounted with a water-soluble mounting medium (Immu-mount, Shandon, Pittsburgh, PA). Control sections were incubated in duplicate with PBS or normal rabbit serum instead of the primary antibody.

Evaluation of the immunohistochemistry

Whole-tissue sections (including the epithelium subjacent to the non-malignant, pre-malignant and malignant areas when present in the specimens) were examined with a light microscope for p53-positive nuclear staining. The staining was recorded as positive (+; > 10% of all the tumor cells positive) for nuclear p53 staining and as negative (–; < 10% positive cells) for negative staining.

Statistical analysis

Using Chi-square statistical analyses at $p < 0.05$ significance level, the difference in the level of expression of p53 in the suspected pre-malignant and malignant oral SCCs from the Sudan, Sweden and Norway was investigated. p53 expression was also correlated with snuff dipping and/or cigarette smoking.

RESULTS

Light microscopic evaluation

Histopathological evaluation of the oral tissue specimens is shown in Tables III and IV. There were no differences in the histological pictures of the oral SCCs from snuff-dippers and non-snuff-dippers from the Sudan.

p53 expression

Descriptions of p53 expression (DO-7, DO-1), snuff dipping and sites of the oral lesions are shown in Tables III and IV. Of the 14 oral SCCs from Sudanese snuff dippers, 21% (3/14)

TABLE III - PROPORTION OF p53 EXPRESSION (DO-7, DO-1) IN ORAL SQUAMOUS-CELL CARCINOMAS (SCCs) AMONG SNUFF-DIPPERS FROM THE SUDAN AND NON-SNUFF-DIPPERS FROM THE SUDAN, SWEDEN AND NORWAY. DISTRIBUTION ACCORDING TO ANATOMICAL SITE

Lesion	Snuff dippers		Non-snuff-dippers	
	Sudanese (n = 14)	Sudanese (n = 14)	Swedish (n = 60)	Norwegian (n = 41)
Oral SCCs (n = 129)	3/14 (21%) ^{1,2}	9/14 (64%) ²	39/60 (65%) ²	28/41 (68%)
Lip	2/12 (17%) ³	2/4 (50%)	2/4 (50%)	18/28 (64%)
Intraoral	1/2 (50%)	7/10 (70%)	37/56 (66%)	10/13 (77%)

¹ $p = 0.013$, Chi-square test for oral SCCs from Sudanese snuff-dippers vs. oral SCCs from non-snuff-dippers from the 3 countries collectively. ² $p = 0.0244$; 0.0032 , 0.0024 , Chi-square test for oral SCCs from snuff dippers in the Sudan vs. oral SCCs from non-snuff-dippers from the Sudan, Sweden and Norway respectively. ³ $p = 0.035$, Chi-square test for lip SCCs from snuff dippers from the Sudan vs. lip SCCs from non-snuff-dippers from the 3 countries collectively.

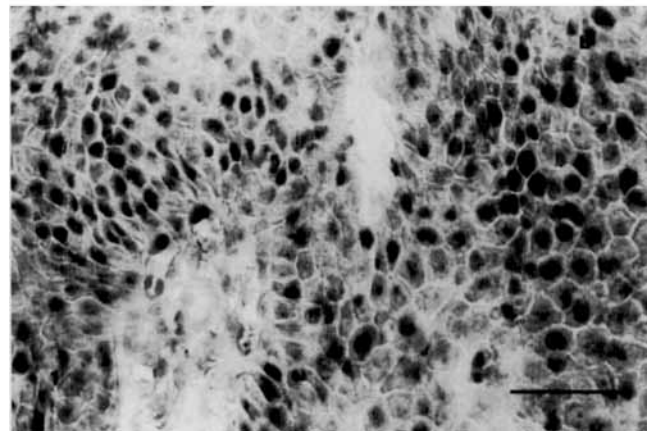
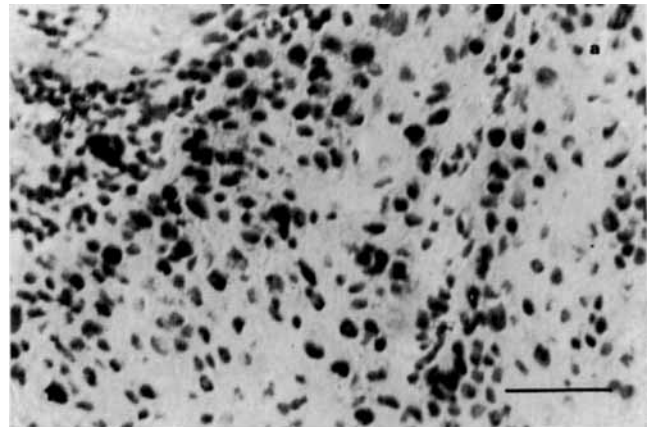
TABLE IV - HISTOLOGICAL EVALUATION AND p53 EXPRESSION IN FIBRO-EPITHELIAL HYPERPLASIAS AND PRE-MALIGNANT ORAL LESIONS AMONG SNUFF-DIPPERS FROM THE SUDAN AND SWEDEN, AND AMONG NON-SNUFF-DIPPERS FROM THE SUDAN AND NORWAY

Lesion	Snuff dippers		Non-snuff-dippers	
	Sudanese (n = 8)	Swedish (n = 15)	Sudanese (n = 3)	Norwegian (n = 19)
Fibro-epithelial hyperplasia (n = 27)	0	2/15	0	0/12
Epithelial dysplasia (n = 12)	0/7	0	0/3	1/2
Carcinoma <i>in situ</i> (n = 6)	0/1	0	0	4/5

expressed p53 (Table III; Fig. 1a, b). The ages of the 3 patients were 65, 70 and 75 years, and all had dipped snuff for 35–50 years. Of the 14 oral SCCs from Sudanese non-snuff-dippers, 64% (9/14) expressed p53 (Table III; Fig. 2a). Of the 60 oral SCCs from Swedish non-snuff-dippers, 65% (39/60) expressed p53 (Table III; Fig. 2b), while 5 out of the 8 cigarette smokers (63%) also expressed p53. Of the 41 oral SCCs from Norwegian non-snuff-dippers, 68% (28/41) expressed p53 (Table III; Fig. 2c), while 7 out of the 11 cigarette smokers (64%) expressed p53. p53 expressed (in the atypical surface epithelium as well as in the infiltrating malignant epithelial tissue) in the oral SCCs of Sudanese snuff dippers (Fig. 1a, b) and in those of non-snuff-dippers from the Sudan (Fig. 2a), Sweden (Fig. 2b) and Norway (Fig. 2c) was localized to the nuclei, and no cytoplasmic staining was seen.

Statistical analysis of the difference in expression of p53 in the oral SCCs from Sudanese snuff-dippers compared to those from non-snuff-dippers from all 3 countries was significant (Table III). The difference in expression of p53 was statistically significant in the oral SCCs from Sudanese snuff-dippers compared to those from non-snuff-dippers from the Sudan, Sweden and Norway, respectively (Table III). The difference in p53 expression in the oral SCCs from non-snuff-dippers from the 3 countries was not statistically significant (Chi square = 0.14, $p = 0.931$). In addition, there was a statistically significant difference between the anatomical site of the oral lesions and p53 expression in the oral SCCs from snuff dippers and those from non-snuff-dippers in the 3 countries (Table III). The difference in p53 expression in the oral SCCs from Norwegian and Swedish cigarette smokers was not significant (Chi square = 0.19, $p = 0.663$). The positive control sections from carcinoma of the cervix were positive for p53, while none of the negative control sections from normal oral mucosal lesions expressed p53.

All the suspected pre-malignant oral lesions from Sudanese snuff-dippers and non-snuff-dippers were negative for p53 (Table IV). Of the 15 oral fibro-epithelial hyperplasias from Swedish snuff-dippers, 13% (2/15) expressed p53 (Table IV), and the staining was confined to nuclei of the epithelial

**FIGURE 1** - Immunohistochemical staining of p53 in an oral squamous-cell carcinoma from a Sudanese snuff-dipper detected by monoclonal antibodies (a) DO-7, (b) DO-1. Scale bar = 50 μ m.

basal-cell layer. The ages of the 2 patients were 36 and 50 years, and both had dipped snuff for more than 15 years. Of the 5 carcinomas *in situ* and the 2 epithelial dysplasias from Norwegian non-snuff-dippers, 80% (4/5) and 50% (1/2) expressed p53, respectively, (Table IV) and the staining was localized to nuclei of the epithelial basal-cell layer. None of the 12 fibro-epithelial hyperplasias from Norwegian non-snuff-dippers expressed p53.

DISCUSSION

In the present study, a significantly lower relative frequency ($p = 0.013$) of p53 expression was found in oral SCCs of

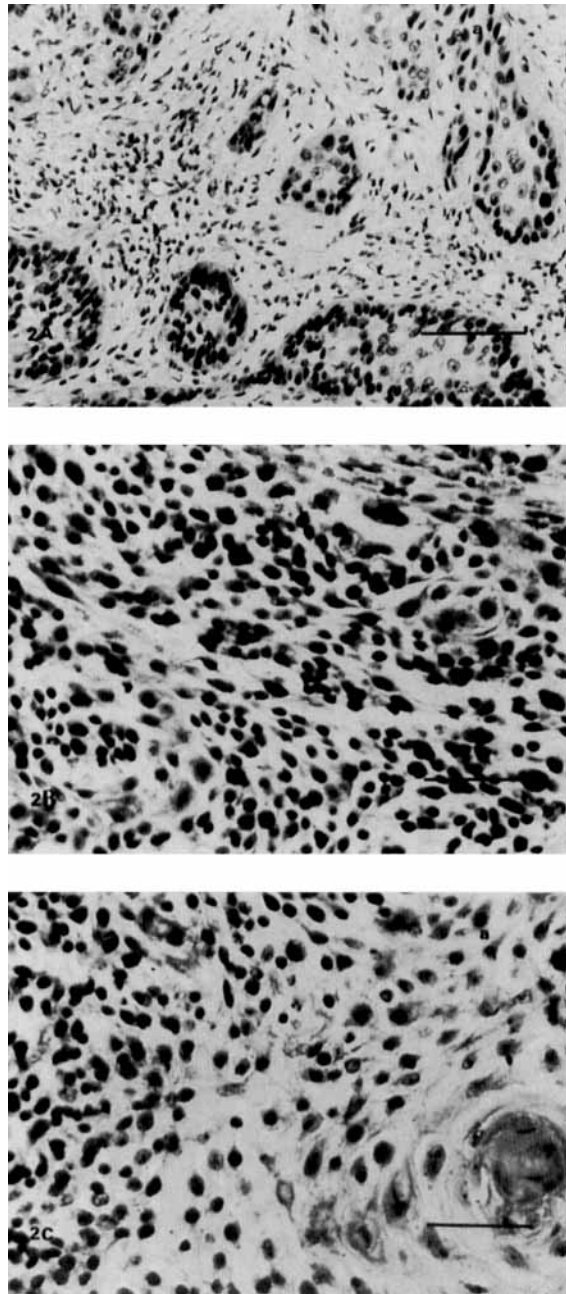


FIGURE 2 – Immunohistochemical staining of p53 in an oral squamous-cell carcinoma from (a) Sudanese, (b) Swedish and (c) Norwegian non-snuff-dippers detected by monoclonal antibodies DO-7 and/or DO-1. Scale bar = 50 μ m.

Sudanese snuff-dippers compared to those of non-snuff-dippers from the Sudan, Sweden and Norway. The 3 oral SCCs and the 2 oral fibro-epithelial hyperplasias from Sudanese and Swedish snuff-dippers, that expressed p53, showed nuclear staining. Eleven of the 14 carcinomas from Sudanese snuff-dippers did not express p53. The findings of a lower relative frequency of p53 expression in oral SCCs of snuff-dippers agree with results of other studies (Ranasinghe *et al.*, 1993b; Thomas *et al.*, 1994). In addition, the low relative frequency of p53 expression found in the oral fibro-epithelial hyperplasias of Swedish snuff-dippers correspond to the previous findings of Wedenberg *et al.* (1996) who also reported a low relative

frequency of p53 expression in the same lesions. Several mechanisms have been suggested to explain the findings of lower relative frequency or absence of p53 expression. Among these mechanisms are the occurrence of allelic deletions of the p53 locus (Blount *et al.*, 1991), non-sense mutations (Hollstein *et al.*, 1991), certain intronic mutations (Takahashi *et al.*, 1990), or p53 degradation by the human papilloma virus (HPV) E6 protein (Scheffner *et al.*, 1990). In addition, formation of p53 complexes with other cytoplasmic proteins has been suggested (Harlow *et al.*, 1985; Pinhasi-Kimhi *et al.*, 1986). The lower relative frequency of p53 expression found in oral SCCs from Sudanese snuff-dippers, in the presence of high levels of tobacco-specific nitrosamine (TSNA) found in snuff, supports the possible occurrence of one of these mechanisms. In non-tobacco-related neoplasms, however, over-expression of p53 has not been shown to be a marker for mutations (Thompson *et al.*, 1992; Barnes *et al.*, 1992).

The high relative frequency of p53 expression found in oral SCCs from non-snuff-dippers was also similar to that observed in other studies (Gusterson *et al.*, 1991; Schipper *et al.*, 1991). In addition, expression of p53 in the oral SCCs of cigarette smokers from Sweden and Norway was consistent with that reported in other studies (Brennan *et al.*, 1995; Lazarus *et al.*, 1996). These data suggest that a history of cigarette smoking is associated with high incidence of p53 expression, as reported by Lazarus *et al.* (1996). Nevertheless, no data on history of alcohol consumption were available from patients from the Sudan (a predominantly Muslim population), Sweden and Norway.

Epidemiological studies from the Sudan (Idris *et al.*, 1994, 1995, 1996) have suggested a causal relationship between snuff dipping and oral SCCs. Sudanese snuff has been reported to contain unusually high levels of TSNA, namely N'-nitrosornicotine (NNN) and 4-(methyl-nitrosamino)-1-(3-pyridyl)-1 butanone (NNK), exceeding the levels reported in any kind of smokeless tobacco including Swedish snuff (Hoffmann and Adams, 1981; Bhide *et al.*, 1987; Brunnemann *et al.*, 1987; Idris *et al.*, 1991). However, a study from the USA (Lazarus *et al.*, 1995), using polymerase chain reaction and single-stranded conformation polymorphism analysis, has reported p53 mutations in a patient with severe oral epithelial dysplasia who had dipped snuff for more than 60 years. The lower relative frequency of p53 expression found in oral SCCs from Sudanese snuff-dippers questions the role of TSNA in induction of oral SCCs through p53 inactivation.

In conclusion, the present study has shown a lower relative frequency of p53 expression in oral SCCs as well as in oral fibro-epithelial hyperplasias from Sudanese and Swedish snuff-dippers, respectively, compared to oral lesions from non-snuff-dippers. The validity of the immunohistochemical techniques for detection of p53 and/or other genetic lesions should be examined carefully to understand the pathogenesis of snuff-induced oral SCCs. Studies of p53 mutations within the coding sequence regions of the p53 protein are therefore needed. In addition, the role of other oncogenes and co-carcinogens has to be investigated in snuff-related hyperplastic and pre-malignant lesions, as well as in oral SCCs, to reveal the possible mechanisms of initiation and progression of snuff-induced oral lesions.

ACKNOWLEDGEMENTS

This study was supported by Colgates Forskningsfond, Colgate-Palmolive Norway A/S. We are grateful to the Toombak Research Center and Oral Cancer Campaign for providing the Sudanese material. We are also grateful to Ms. G. Albrechtsen for advice on statistical analysis and Ms. G. Øijordsbakken for skilled technical assistance.

REFERENCES

- BARNES, D.M. and 13 OTHERS, Abnormal expression of wild type p53 protein in normal cells of a cancer family patient. *Lancet*, **340**, 259–263 (1992).
- BHIDE, S.V., NAIR, U.J., SPIEGELHALDER, B. and PREUSSMANN, R., N-nitrosamines in the saliva of tobacco chewers or masheri users. *Food Chem. Toxicol.*, **24**, 293–297 (1987).
- BINNIE, W.H., RANKIN, K.V. and MACKENZIE, I.C., Etiology of oral squamous cell carcinoma. *J. oral Pathol.*, **12**, 11–29 (1983).
- BLOUNT, P.L., RAMEL, S., RASKIND, W.H., HAGGITT, R.C., SANCHEZ, C.A., DEAN, P.J., RABINOVITCH, P.S. and REID, B.J., 17p allelic deletions and p53 protein overexpression in Barrett's adenocarcinoma. *Cancer Res.*, **51**, 5482–5486 (1991).
- BRENNAN, J.A., BOYLE, J.O., KOCH, W.M., GOODMAN, S.N., HRUBAN, R.H., EBY, Y.J., COUGH, M.J., FORASTIERE, A.A. and SIDRANSKY, D., Association between cigarette smoking and mutation of the p53 gene in squamous cell carcinoma of the head and neck. *New Engl. J. Med.*, **332**, 712–717 (1995).
- BRUNNEMANN, K.D., HORNBY, A.P. and STICH, H.A., Tobacco-specific nitrosamines in the saliva of Inuit snuff dippers in the Northwest Territories of Canada. *Cancer Lett.*, **37**, 7–16 (1987).
- CAWSON, R.A. and EVESON, J., *Oral pathology and diagnosis*, Vol. 13, pp. 10–13, Gower, London (1987).
- ELBESHIR, E.I., ABDEEN, H.A., IDRIS, A.M. and ABBAS, K., Snuff dipping and oral cancer in Sudan, a retrospective study. *Brit. J. oral maxill. Surg.*, **27**, 243–248 (1989).
- FIELD, J.K., SPANDIDOS, D.A., MALLIRI, A., GOSNEY, J.R., YIAGNISIS, M. and STELL, P.M., Elevated p53 expression correlates with a history of heavy smoking in squamous cell carcinoma of the head and neck. *Brit. J. Cancer*, **64**, 573–577 (1991).
- FINLAY, C.A., HINDS, P.W. and LEVINE, A.J., The p53 proto-oncogene can act as a suppressor of transformation. *Cell*, **57**, 1083–1093 (1989).
- GUSTERSON, B.A., ANBAZHAGAN, R., WARREN, W., MIDGELY, C., LANE, D.B., O'HARE, M., STAMPS, A., CARTER, R. and JAYATILAKE, H., Expression of p53 in premalignant and malignant squamous epithelium. *Oncogene*, **6**, 1785–1789 (1991).
- HAKULINEN, T., ANDERSEN, A.A., MALKER, B., PUKKALA, E., SCHOU, G. and TULINIUS, H., Trends in cancer incidence in the Nordic countries. *Acta pathol. microbiol. immunol. scand. A*, Suppl. **288**, 1–151 (1986).
- HARLOW, E., WILLIAMSON, N.M., RALSTON, R., HELFMAN, D.M. and ADAMS, T.E., Molecular cloning and *in vitro* expression of a cDNA clone for human cellular tumour antigen p53. *Mol. cell. Biol.*, **5**, 1601–1610 (1985).
- HARRIS, C.C., Chemical and physical carcinogenesis. Advances and perspectives for the 1990's. *Cancer Res.*, **51**, 5023–5044 (1991).
- HIRSCH-J.M. and JOHANSSON, S.L., Effect of long-term application of snuff on the oral mucosa—an experimental study in the rat. *J. oral Pathol.*, **12**, 187–198 (1983).
- HIRSCH-J.M., JOHANSSON, S.L., THILANDER, H. and VAHLNE, A., Effect of long-term application of snuff and herpes simplex virus on rat oral mucosa. Possible association with development of oral cancer. *IARC Scientific Publication 57*, pp. 829–836, IARC Lyon (1984).
- HOFFMANN, D. and ADAMS, J.D., Carcinogenic tobacco-specific N-nitrosamines in snuff and in the saliva of snuff dippers. *Cancer Res.*, **41**, 4305–4308 (1981).
- HOLLSTEIN, M., SIDRANSKY, D., VOGELSTEIN, B. and HARRIS, C.C., p53 mutations in human cancers. *Science (Wash.)*, **253**, 49–53 (1991).
- IBRAHIM, S.O., JOHANNESSEN, A.C., VASSTRAND, E.N., LILLEHAUG, J.R., LIAVAUG, P.G. and NILSEN, R., Immunohistochemical detection of p53 in archival formalin-fixed tissues of lip and intraoral squamous-cell carcinomas from Norway. *Europ. J. oral Sci.*, (1996). (In press).
- IDRIS, A.M., AHMED, H.M. and MALIK, M.O.A., Toombak dipping and cancer of the oral cavity in the Sudan: case-control study. *Int. J. Cancer*, **63**, 477–480 (1995).
- IDRIS, A.M., NAIR, J., OHSHIMA, H., FRIESEN, M., BROUET, I., FAUSTMAN, E.M. and BARTSCH, H., Unusually high levels of carcinogenic tobacco-specific nitrosamines in Sudan snuff (Toombak). *Carcinogenesis*, **12**, 1115–1118 (1991).
- IDRIS, A.M., PROKOPCZYK, B. and HOFFMANN, D., Toombak: a major risk factor for cancer of the oral cavity in Sudan. *Prevent. Med.*, **23**, 832–839 (1994).
- IDRIS, A.M., WARNAKULASURIYA, K.A.S.S., IBRAHIM, Y.E., NILSEN, R., COOPER, D. and JOHNSON, N.W., Toombak-associated oral mucosal lesions in Sudanese show a low prevalence of epithelial dysplasia. *J. oral Pathol. Med.*, **25**, 239–244 (1996).
- JOHNSON, N.W., Orofacial neoplasms: global epidemiology, risk factors and recommendations for research. *Int. dent. J.*, **41**, 365–375 (1991).
- JOHNSON, N.W. and WARNAKULASURIYA, K.A.S.S., Epidemiology and aetiology of oral cancer in the United Kingdom. *Comm. dent. Hlth.*, **10**, 13–29 (1993).
- KAUR, J., SRIVASTAVA, A. and RALHAN, R., Overexpression of p53 protein in betel- and tobacco-related human oral dysplasia and squamous-cell carcinoma in India. *Int. J. Cancer*, **58**, 340–345 (1994).
- KRAFT, P. and SVENDSEN, T., Røykevaner og bruk av snus i Norge 1973–95. *Tidsskr nor. Lægeforen.*, **5**, 629–634 (1996).
- LAZARUS, P., GAREWAL, H.S., SCIUBBA, J., ZWIEBEL, N., CALCAGNOTTO, A., FAIR, A., SCHAEFER, S. and RITCHIE, J.P., JR., A low incidence of p53 mutations in pre-malignant lesions of the oral cavity from non-tobacco-users. *Int. J. Cancer*, **60**, 458–463 (1995).
- LAZARUS, P., STERN, J., ZWIEBEL, N., FAIR, A., RITCHIE, J.P., JR. and SCHANTZ, S., Relationship between p53 mutation incidence in oral cavity squamous cell carcinomas and patient tobacco use. *Carcinogenesis*, **17**, 733–739 (1996).
- ÖSTMAN, J., ANNEROTH, G., GUSTAFSSON, H. and TAVELIN, B., Malignant oral tumours in Sweden 1960–1989—an epidemiological study. *Oral Oncol. Europ. J. Cancer*, **31B**, 106–112 (1995).
- PARKIN, D.M., PISANI, P. and FERLAY, J., Estimates of the worldwide incidence of eighteen major cancers in 1985. *Int. J. Cancer*, **54**, 594–606 (1993).
- PINHASI-KIMHI, O., MICHALOVITZ, D., BEN-ZEEV, A. and OREN, M., Specific interaction between the p53 cellular tumour antigen and major heat shock proteins. *Nature (Lond.)*, **320**, 182–185 (1986).
- RANASINGHE, A.W., MACGEOCH, C., DYER, S., SPURR, N. and JOHNSON, N.W., Some oral carcinomas from Sri Lanka betel/tobacco chewers overexpress p53 oncoprotein but lack mutations in exons 5–9. *Anti-Cancer Res.*, **13**, 2065–2068 (1993a).
- RANASINGHE, A.W., WARNAKULASURIYA, K.A.A.S. and JOHNSON, N.W., Low prevalence of expression of p53 oncoprotein in oral carcinomas from Sri Lanka associated with betel and tobacco chewing. *Oral Oncol. Europ. J. Cancer*, **29b**, 147–150 (1993b).
- SCHIEFFNER, M., WERNES, B.A., HUIBREGTSE, J.M., LEVINE, A.J. and HOWLEY, P.M., The E6 oncoprotein encoded by human papillomavirus types 16 and 18 promotes the degradation of p53. *Cell*, **63**, 1129–1136 (1990).
- SCHIPPER, J.J., FRIXEN, U.H., BEHRENS, J., UNGER, A., JAHNKE, K. and BIRCHMEIER, W., E-cadherin expression in squamous-cell carcinomas of the head and neck: inverse correlation with tumour dedifferentiation and lymph-node metastasis. *Cancer Res.*, **51**, 6328–6337 (1991).
- TAKAHASHI, T., D'AMICO, D., CHIBA, I., BUCHHAGEN, D.L. and MINNA, J.D., Identification of intronic point mutations as an alternative mechanism for p53 inactivation in lung cancer. *J. clin. Invest.*, **86**, 363–369 (1990).
- THOMAS, S., BRENNAN, J., MARTEL, G., FRAZER, I., MONTESANO, R., SIDRANSKY, D. and HOLLSTEIN, M., Mutations in the conserved regions of p53 are infrequent in betel-associated cancers from Papua New Guinea. *Cancer Res.*, **54**, 3588–3593 (1994).
- THOMPSON, A.M., ANDERSON, T.J., CONDIE, A., PROSSER, J., CHETTY, U., CARTER, D.C., EVANS, H.J. and STEEL, C.M., p53 allele losses, mutations and expression in breast cancer and their relationship to clinicopathological parameters. *Int. J. Cancer*, **50**, 528–532 (1992).
- VOJTESEK, B., BARTEK, J., MIDGLEY, C.A. and LANE, D.P., An immunochemical analysis of the human nuclear phosphoprotein p53: new monoclonal antibodies and epitope mapping using recombinant p53. *J. immunol. Meth.*, **151**, 237–244 (1992).
- WEDENBERG, C., JÖNSSON, A., and HIRSCH, J.M., Assessment of p53 and Ki-67 expression in snuff-induced lesions. *J. oral maxill. Surg.*, (1996). (In press).