

Paper I

High wear rates and extensive osteolysis in 3 types of uncemented total hip arthroplasty

A review of the PCA, the Harris Galante and the Profile/Tri-Lock Plus arthroplasties with a minimum of 12 years median follow-up in 96 hips

Geir Hallan¹, Stein A Lie¹ and Leif I Havelin^{1,2}

¹Department of Orthopaedic Surgery, Haukeland University Hospital, Bergen, ²Institute of Surgical Sciences, University of Bergen, Bergen, Norway

Correspondance GH: geir.hallan@helse-bergen.no

Submitted 04-12-06. Accepted 06-02-11

Background High wear rates and femoral and acetabular osteolysis have been—and still are—the main problems in uncemented total hip replacement. We reviewed 96 consecutive cementless total hip replacements of 4 different designs.

Patients and methods 21 PCA, 25 Harris Galante Porous/Harris Galante I (stem/cup), 25 Profile pressfit/Tri-Lock Plus (stem/cup) and 25 Profile HA-coated/Tri-Lock Plus (stem/cup) prostheses were included. The operations were performed in the period 1984–1991. Median follow-up ranged from 12–16 years. Wear and osteolysis were measured.

Results Mean linear wear rates ranged from 0.17 to 0.21 mm/year in the 4 groups, and there were no statistically significant differences between the groups ($p = 0.9$, ANOVA). Moderate or extensive osteolysis was found in 46 of the 96 hips included. The association between high and low wear rates (more or less than 0.20 mm/year) and extent of osteolysis was statistically significant ($p < 0.001$, t-test). We found poor 12-year survival of the primary prostheses in all 4 groups (50–70%), mainly due to revisions because of wear of the polyethylene liner and/or osteolysis. The infrequently documented Profile/Tri-Lock Plus systems did not perform differently from the PCA and the HG.

Interpretation The poor long-term results with these uncemented total hip arthroplasties illustrate the necessity of regular radiographic evaluation in order to detect osteolysis and liner failure, which are both generally asymptomatic until catastrophic failure appears.

Cementless total hip arthroplasty was introduced partly in the belief that periprosthetic osteolysis could be eliminated by eliminating the need for cement (Willert et al. 1974, Jones and Hungerford 1987). However, numerous studies have reported alarming periprosthetic osteolysis in cementless total hip replacement (Tanzer et al. 1992, Xenos et al. 1995, Kim et al. 1999, Thanner et al. 1999, Crowther and Lachiewicz 2002). Polyethylene wear debris has been suggested by many authors as a major cause of osteolysis (Santavirta et al. 1990, Willert et al. 1990). Others believe that unstable components cause osteolysis by pumping joint fluid into the surrounding bone tissue at high pressure (Mjöberg 1994, Aspenberg and van der Vis 1998). The relationship between wear rate and extent of osteolysis (Dowd et al. 2000, Barrack et al. 2002, Orishimo et al. 2003b) has been established. The high wear rate and high incidence of osteolysis in some metal-backed uncemented acetabular cups (Harris 1994, Nashed et al. 1995, Sychterz et al. 1996) is a major concern in cementless total hip replacement, in addition to the mechanical problems of wear alone (instability and leg shortening). We compared the wear rates and incidence and patterns of osteolysis in 4 cementless total hip systems, 2 of which (the Profile/Tri-Lock Plus systems) have virtually no clinical documentation. Furthermore, we evaluated the influence of femoral head size, cup abduction, sex and body weight on wear rates, and the asso-

Table 1. Patient characteristics: age at surgery, gender, body weight, femoral head diameter, duration of follow-up, and diagnosis

	PCA (n = 21)	HG (n = 25)	Profile/Tri-Lock (n = 25)	Profile HA/Tri-Lock (n = 25)
Age at surgery, median (range)	43 (24–60)	47 (19–62)	56 (25–74)	56 (30–65)
Gender (F/M)	15/6	13/12	15/10	20/5
Body weight (kg), median (range)	65 (52–104)	72 (50–90)	63 (48–100)	70 (50–106)
28-mm femoral head (number of hips)	0	0	13	17
32-mm femoral head (number of hips)	21	25	12	8
Follow-up ^a (years), median (range)	16 (9–18)	15 (7–17)	12 (7–14)	12 (7–14)
Diagnosis				
Primary coxarthrosis	4	6	8	11
Sequel, hip fracture	10	2	6	–
Sequel, childhood hip disease	6	10	10	7
Rheumatoid arthritis	1	3	2	5
Others	1	5	3	2

^a Follow-up until first revision of any component, including exchange of liner and femoral head.

ciation between the rate of wear and the extent of osteolysis.

Material and methods

The 4 designs of prosthesis studied were the Porous-Coated Anatomic (P.C.A.; Howmedica, Rutherford, NJ), the Harris/Galante Porous stem/Harris Galante I cup (HG; Zimmer, Warsaw, IN), the Profile pressfit stem/Tri-Lock Plus cup and the Profile hydroxy-apatite coated stem/Tri-Lock Plus cup (Profile and Profile HA, respectively; DePuy, Warsaw, IN).

The PCA stem was made of cobalt-chrome, was relatively short, collarless, and anatomically shaped with a circumferential proximal porous coating. The cup used in the period 1984–1986 was single-assembly, cobalt-chrome, porous-coated and also fixed to bone by pegs. From August 1986, a two-piece cup with a hexagon locking mechanism was used (8 hips). The porous coating was Vitallium and applied by sintering. The liner was fixed to the shell by a central polyethylene locking peg. The UHMWPE liner was not heat-treated, but sterilized by gamma irradiation in air.

The HG (Harris/Galante Porous Hip Prostheses) stem was a straight titanium alloy (Titanium Ti-6Al-4V) stem with a collar and non-circumferential proximal fiber-mesh pads made of pure titanium. The acetabular component was a modular, hemispherical press-fit cup with a sintered titanium

fiber-mesh at the bone-implant interface and holes for transacetabular screws. 2 or 3 transacetabular screws were used in all hips. The liner was sterilized by gamma irradiation in air.

The Profile stem was a modular anatomic titanium alloy stem with two different surfaces. One had a gritted surface with proximal circumferential microtexture (hereafter referred to as Profile). The other had a proximal, circumferential microtexture finish made of hydroxy-apatite (hereafter referred to as Profile HA). The Tri-Lock Plus cup is a hemispherical titanium shell with porous coating and holes for peripheral screw fixation. The liner was sterilized by gamma irradiation in air.

In the PCA and HG groups, the femoral head was a 32-mm modular cobalt chromium head in all hips. In the Profile/Tri-Lock hips, both 28-mm and 32-mm heads were used; see Table 1.

Between 1984 and 1991, these components were used in our department in younger patients, most of them less than 60 years of age. The PCA was inserted in 26 hips. 2 of these were revision arthroplasties, 2 patients died within 7 years of surgery, and radiographs of 1 patient were missing. This left 21 hips in 18 patients in the PCA group. We then aimed for groups of similar sizes (25 patients) in the 3 other groups. The HG was used in 47 hips. We included the first (consecutive) 25 hips (20 patients) with available data and minimum follow-up of 7 years. Revision arthroplasties and former resurfaced hips were excluded. The Profile/Tri-Lock Plus and Profile HA/Tri-Lock

Plus were used in 191 hips in the period 1989–1994. In the same manner, we included the first 25 patients in each of these groups. Thus, we included 25 Profile/Tri-Lock Plus combinations in 23 patients and 25 Profile HA/Tri-Lock Plus in 21 patients. The total number of hips included was 96 (82 patients) (Table 1). A proportion of the patients in all 4 groups were referred from other regions for uncemented total hip arthroplasty, which, at that time, was done only at selected clinics. The follow-up, however, was often done at the patient's local hospital. According to Norwegian law, radiographs of patients not re-examined in our radiology department within 10 years of the index examination were destroyed. Thus, in these patients the postoperative radiographs were not available and the patients were therefore excluded.

The patients who received the PCA were followed radiographically for a median of 16 (9–18) years. Similarly, those who received the HG were followed for a median of 15 (7–18) years, the Profile/Tri-Lock Plus for a median of 12 (7–14) years, and the Profile HA/Tri-Lock Plus for a median of 12 (7–14) years. The median follow-up was longer in the PCA and HG groups. In the PCA group, sequel after hip fracture was the most common diagnosis whereas sequel after childhood hip disease (developmental dysplasia of the hip, Legg-Perthes disease, slipped capital epiphysis) and primary osteoarthritis predominated in the other groups. The average age of patients in the PCA and HG groups was lower than in the Profile/Tri-Lock Plus groups (ANOVA, $p = 0.03$). Otherwise, the 4 groups were reasonably well matched. All the operations were performed in the lateral decubitus position using a direct lateral Hardinge approach without trochanteric osteotomy, by three experienced surgeons. Postoperatively, the patients were allowed partial weight bearing from day 2 and full weight bearing after 3 months.

Standard radiographs, including an AP pelvic view, and AP and lateral views of the hip within three months of surgery, and the films from the latest follow-up or the latest films prior to revision were evaluated by one of the authors (GH). GH did not operate any of the patients.

Linear wear was measured on AP pelvic views using the method described by Livermore et al.

(1990). The direction of linear polyethylene wear in the frontal plane was measured referenced to a line through the center of the femoral head that was perpendicular to the inter-teardrop line. A manual caliper was used, measuring to the nearest 0.05 mm, and the known diameter of the femoral head was used to correct for magnification. Rather than measuring the thickness of the polyethylene directly, we measured the distance from the center of the femoral head to the outer surface of the metal backing, assuming negligible wear of the head and backing. Assuming a cylindrical wear track, volumetric wear was calculated from the formula $v = r^2w$, in which v is the change of volume of the polyethylene, r is the radius of the head, and w is the linear wear. The average volumetric wear rate (in mm^3/year) was then calculated based on the follow-up time of the liner.

The angle of abduction of the cup was the angle measured between a line drawn along the opening of the cup and the inter-teardrop line on the postoperative AP pelvic radiograph. The influence of femoral head size on wear rate and extent of osteolysis was evaluated in the Profile/Tri-Lock Plus groups only, in which both 28- and 32-mm heads were used.

Presence and extent of osteolysis was recorded on the AP and pelvic films since the quality of the lateral views was poor in many cases. Any punched-out area of reduced bone density that was not present on the initial radiographs was interpreted as osteolysis. The area of osteolysis was measured by multiplying the length by the width of the lesions. Osteolysis was labeled extensive when the area was 10 cm^2 or more, intermediate when between 2.5 and 10 cm^2 , and mild when less than 2.5 cm^2 (Hubble et al. 1997). The distribution in femoral and acetabular regions was recorded according to Gruen et al. (1979) and Charnley (1976).

Statistics

Statistical evaluation was performed using SPSS version 10.0 software. We used the Student t-test and ANOVA (analysis of variance) to compare means. Survival analysis was performed by the Kaplan-Meier method and by Cox regression analyses. Survival rates for the primary prostheses were calculated based on revision as end-point. Revision was defined as removal or exchange of any part of

Table 2. Wear characteristics and extent of osteolysis

	PCA (n = 21)	HG (n = 25)	Profile/Tri-Lock (n = 25)	Profile HA/Tri-Lock (n = 25)
Linear wear rate (mm/year), mean	0.20	0.20	0.21	0.17
Linear wear (mm), mean	2.2	2.3	1.81	1.75
Volumetric wear (mm ³), mean	1,817	1,841	1,286	1,297
Volumetric wear rate (mm ³ /year), mean	159	159	144	117
Number of hips with osteolysis	13	16	12	12
Osteolysis, mean total area (cm ²)	15	10	7	8
Osteolysis, severity (n)				
Mild (< 2.5 cm ²)	0	1	3	3
Intermediate (2.5–10 cm ²)	4	12	5	5
Extensive (> 10 cm ²)	9	3	4	4

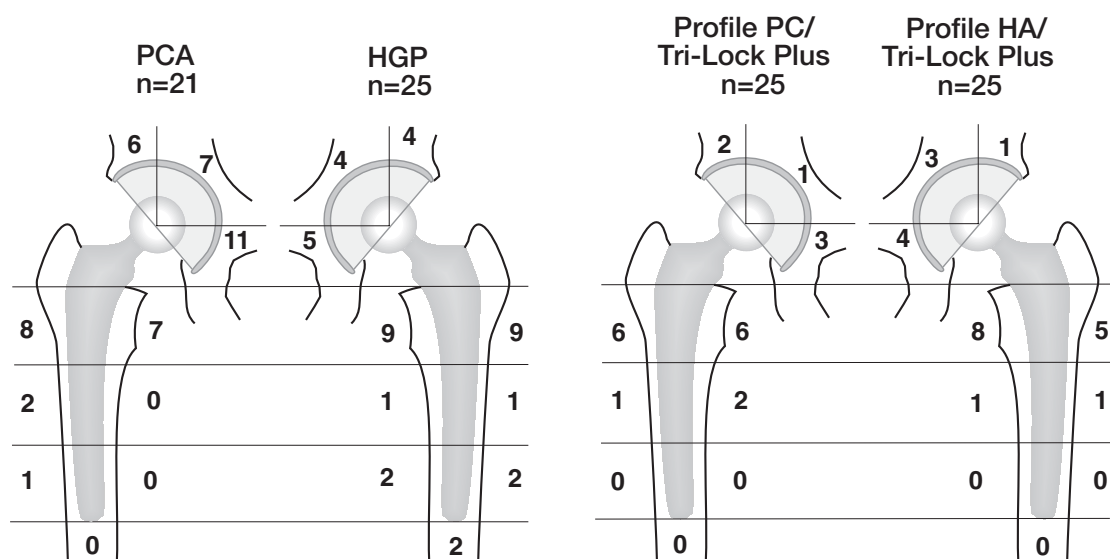


Figure 1. Distribution of osteolysis. Distribution of osteolytic lesions in regions according to Gruen, and Charnley and DeLee. Figures in each region show the number of hips in which osteolytic lesions were found in that specific region. Lesions spanning more than one region have been registered in all regions involved.

the total hip, including liner and head exchange. We also did separate survival analyses with aseptic loosening as the endpoint. The survival data were collected from the patient files. For calculation of the survival of the prostheses, we used date of revision for any cause as the failure date and date of last control as the censoring date.

Results

The mean rate of linear wear ranged from 0.17 to 0.21 mm/year in the 4 groups (Table 2). There were no statistically significant differences between the groups regarding linear or volumetric wear rates ($p = 0.9$ and 0.7 , ANOVA).

In the 2 Profile/Tri-Lock Plus groups, there were 30 hips with a 28-mm femoral head and 20 with a 32-mm head. The volumetric wear rates were 124 mm³/year and 140 mm³/year, respectively, and the difference was not significant ($p = 0.7$, t-test). Gender and body weight had no statistically significant influence on wear rates ($p = 0.3$ and $p = 0.3$, t-test).

Extensive osteolysis occurred in all 4 groups (Table 2, Figure 1). Femoral osteolysis was found primarily in the proximal regions (regions 1 and 7). Distal femoral osteolysis (regions 3, 4 and/or 5) was found in 3 HG hips and in 1 PCA hip (Figures 2 and 3). In the latter, clinical signs of loosening preceded osteolysis by several years, and during revision the stem was found to be loose (Figure 2).

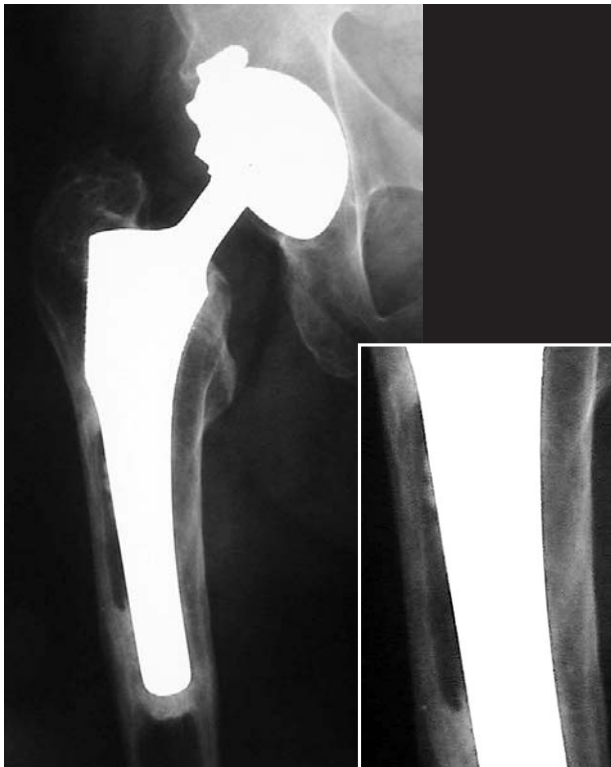

Figure 2. PCA with distal osteolysis. The patient had clinical signs of aseptic stem loosening, starting several years before the osteolytic lesion developed.

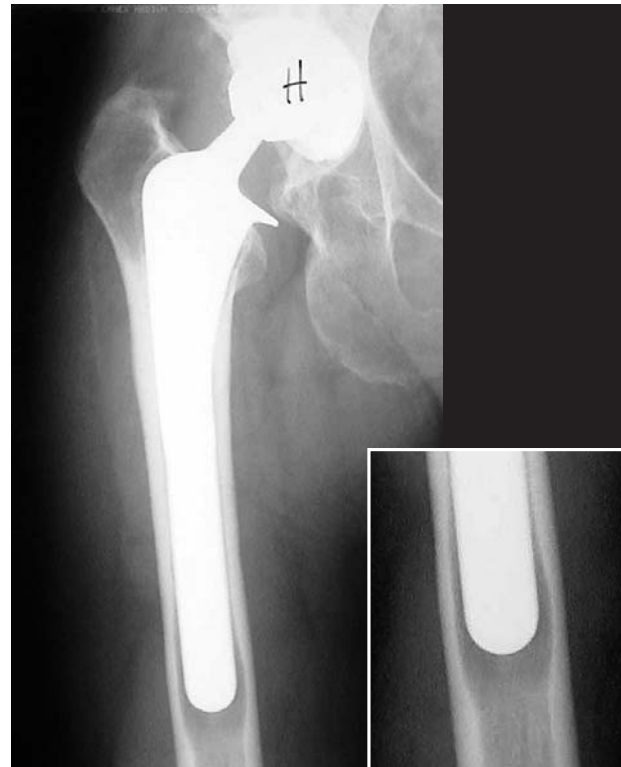

Figure 3. Harris-Galante stem showing moderate distal osteolysis. Radiographically, the stem is otherwise well fixed.

Table 3. Revisions and survival rates

	PCA (n = 21)	HG (n = 25)	Profile/Tri-Lock (n = 25)	Profile HA/Tri-Lock (n = 25)
All revisions	12	13	10	11
Liner/head exchange	6	9	7	9
Metal shell exchange	6	–	1 ^a	2
Stem exchange	5	4	3	1
12-year survival, any revision (%)	70 (50–90)	58 (38–78)	56 (20–77)	50 (26–73)

^a Well-fixed metal shell revised because of wear in a highly abducted cup (70°).

Thus, in this case, the osteolysis was possibly secondary to instability. In the acetabulum, the lesions were equally distributed in the three regions.

The cup inclination was median 48° (32–56) in the PCA, median 44° (33–73) in the HG, median 45° (35–64) in the Profile/Tri-Lock Plus, and median 49° (35–70) in the Profile HA/Tri-Lock Plus. There were no statistically significant differences between the groups (all $p > 0.05$, ANOVA). There was no statistically significant association between cup abduction and linear or volumetric wear rate ($p = 0.1$ and $p = 0.2$, ANOVA).

The association between wear rates—both linear and volumetric—and osteolysis was statistically

significant in Cox regression analyses ($p = 0.004$ and $p = 0.001$). Dividing the whole material into 2 groups defined by linear wear rate greater or less than 0.20 mm/year, we found statistically significantly more osteolysis in the high-wear group ($p = 0.006$, t-test). In hips with a wear rate of > 0.20 mm/year, the mean area of osteolysis was 9.5 cm² (95% CI 6.4–13) as compared to 3.1 cm² (95% CI 1.7–4.5) in the low-wear group.

The 12-year survival of the prostheses ranged from 50% to 70% (Table 3), but there were no statistically significant differences (all $p > 0.05$, log rank test). 31 of 46 revisions were liner and head exchange procedures because of wear and

Table 4. Reasons for revision

	PCA (n = 21)	HG (n = 25)	Profile/Tri-Lock (n = 25)	Profile HA/Tri-Lock (n = 25)
Wear	9	6	7	9
Osteolysis	10	4	4	5
Aseptic loosening, cup	6	–	–	2
Aseptic loosening, stem	5	3	3	1
Others ^a	–	1	–	1

^a Others: pain, instability

liner failure. In more than half of these revisions (n = 18), we performed autologous bone impaction grafting for osteolysis in the femur, the acetabulum or both. Revision for aseptic loosening of the cup was done in 6 PCA hips, in 2 Tri-Lock Plus hips (n = 50) but in no HG hips. Stem revision for aseptic loosening was done in 5 PCA hips, in 4 HG hips, in 3 Profile hips and in 1 Profile HA hip (Table 4).

Discussion

We found high wear rates, extensive osteolysis, and poor long-term survival in all 4 groups. Furthermore, we found a statistically significant association between wear and osteolysis. The poor performance of the PCA and the HG prostheses is well documented (Tanzer et al. 1992, Kim et al. 1993, Xenos et al. 1995, Kim et al. 1999, Tanner et al. 1999, Bojeskul et al. 2003). The Profile stems and the Tri-Lock Plus cup have very little clinical documentation (Kim et al. 2003). The second generation Profile/Tri-Lock Plus THAs did not perform statistically significantly different from the first-generation PCA and HG prostheses. The extent of osteolysis was less, however, in the Profile groups. Whether this was implant-related or due to a shorter time of follow-up, we do not know.

Conventional radiographic measurement of wear in acetabular components has limited reproducibility and precision. The intraobserver variability of Livermore's method is reported by the author to be 0.075 mm (Livermore et al. 1990). On the other hand, other studies have reported the variability to be from 0.3 mm (Callaghan et al. 1995) to as high as 0.6 mm (Ebramzadeh et al. 2003). Moreover, the metal backing of the acetabular components made

visualization of the femoral head difficult in some cases, especially in the PCA group. This may be a source of variability in the wear measurements. The wear rate of metal-backed uncemented cups has been shown in numerous studies to be higher than in cemented all-polyethylene cups (Harris 1994, Nashed et al. 1995, Sychterz et al. 1996). The mean linear wear rates spanning from 0.17 to 0.21 mm/year found in the current study are similar to those reported in other studies (Hernandez et al. 1994, Røkkum and Reigstad 1998, Dowd et al. 2000). They are higher than the 0.08–0.1 mm/year reported for the cemented Ogee UHMWPE sterilized in air with the Charnley 22.2-mm stainless steel head (Halley and Glassman 2003, Wroblewski et al. 2004).

This patient material was made up of 4 relatively small groups. Thus, the power to detect differences between groups was low. We could not confirm the relationship between large femoral heads and volumetric wear, as reported previously (Livermore et al. 1990, Kesteris et al. 1996, Oparaugo et al. 2001). Even so, we believe—based on broad documentation—that the use of large femoral heads with conventional polyethylene liners is not advisable. When performing liner exchange revisions, we used thicker inlays and smaller heads to reduce wear and postpone future liner exchange. Until further long-term documentation of low-wear articulations using metal-on-metal, highly cross-linked polyethylene and/or ceramic bearings, large-diameter heads should be avoided unless the risk of dislocation outweighs the risk of excessive wear, as in older patients with low compliance and/or fracture sequels (Furnes et al. 2001, Byström et al. 2003).

The relationship between wear rates and occurrence of osteolysis reported by others (Shih et al. 1997, Dowd et al. 2000, Barrack et al. 2002) was

confirmed in our study. Also, revision rates have been shown to correlate strongly with volumetric wear rates of polyethylene (Oparaugo et al. 2001). In 18 of the 31 liner-exchange revisions, we also performed autologous bone impaction grafting of osteolytic lesions. The identification of osteolytic lesions and the differentiation towards stress shielding and osteoporosis is crude in conventional X-rays. The extent of osteolysis as judged by routine radiographic evaluation is generally underestimated, especially on the acetabular side (Claus et al. 2003). Preoperative computerized tomographic scans help delineate pelvic osteolytic lesions (Puri et al. 2002, Stulberg et al. 2002) and are useful in deciding the need for grafting, and whether or not to exchange the metal shell.

According to Schmalzried and others (Schmalzried et al. 1992, Emerson et al. 1999), the effect of circumferential proximal coating of the stem is important in reducing the effective joint space and hence distal femoral osteolysis. The HG stem lacks such a coating, and has been shown to display distal osteolysis (Kim and Kim 1992, Hubble et al. 1997). In our material of 25 HG, we found distal femoral osteolysis (regions 3–5) in 3. These findings support the belief that uncemented stems should have circumferential coating. The other designs in this study all feature proximal circumferential coatings of different kinds. With the exception of 1 PCA stem, we did not find distal femoral osteolysis in the Profile stems or in the PCA stems. In the PCA-case, we suspect that osteolysis is secondary to loosening, as clinical signs of loosening preceded radiographic osteolysis by several years (Figure 2).

5 patients in our material had identical bilateral hip replacements. In 3 of these, sudden accelerating wear appeared after 7–12 years in one hip whilst the other had a linear wear pattern. The reason for this sudden acceleration is poorly understood. Third body wear and increasing roughness of the femoral head are probably important cofactors. Orishimo et al. (2003a) demonstrated that 40% of wear variance in total hip replacement is dependent on factors other than those related to the patient, such as sex, weight, age and activity level. Furthermore, the association between early and late wear rates in the individual case has been shown to be low (Hopper et al. 2003). Thus, the rate of wear

in an individual patient cannot be predicted and cannot be expected to be linear. Patients are usually asymptomatic unless synovitis or instability develops. All patients with these uncemented total hip arthroplasties should thus be frequently and systematically evaluated radiographically to assess wear and to avoid severe bone loss that would complicate later revisions.

The association between wear and osteolysis shown in our study and others gives no answer to the fundamental question of what causes osteolysis. The findings may imply a simple coexistence rather than a causative relationship between the two. It seems that the orthopedic community has accepted the theory of wear-induced osteolysis, and contemporary research on hip implant technology regards wear particles as the major problem to be solved. Some authors have advocated the theory of early loosening, according to which osteolysis is caused by unstable components pumping joint fluid under high pressure into the surroundings (Mjöberg 1994, Aspenberg and van der Vis 1998). It has been shown by use of radiostereometric analysis that early micromotion of implants predicts loosening several years later (Kärrholm et al. 1994, Ryd et al. 1995). Experiments have shown polyethylene particles to be rather incapable of causing bone resorption, whereas osteolysis in the same set-up was easily induced by mechanical instability (Aspenberg and Herbertsson 1996). The findings in our study neither support nor contradict any of these theories; they simply underscore the magnitude of wear and osteolysis as clinical problems. We believe more research is needed regarding our fundamental understanding of osteolysis, in order to accurately address the clinical problems of bone loss and loosening. The apparent consensus on the theory of wear-induced osteolysis may suppress further knowledge in this field, and may even misguide the orthopedic research community in its effort to improve clinical results of hip arthroplasty.

Liner exchange procedures are usually not presented in the literature when reporting survival of primary hip replacements. We believe that survival of metal-backed uncemented cups should be reported with exchange of liner or shell as an endpoint. In our view, a liner exchange procedure is not a minor procedure. Although it is technically

simple, the implications for the patient regarding pain and rehabilitation, the cost of the procedure, the risk of infection, soft tissue complications and the substantial risk of postoperative dislocation (Huo and Brown 2003) make the procedure a considerable burden to the patient and to society. Furthermore, the association between wear and osteolysis means that bone impaction grafting is frequently indicated when performing liner exchange, as was the case in 18 of 31 liner exchange revisions in the current study. We definitely consider this procedure to be major surgery. It should be regarded a revision when reporting survival of total hip replacements.

Our department used the PCA, the HG and the Profile/Tri-Lock Plus hip prostheses in young patients in the eighties and early nineties in the belief that they would provide better long-term results than cemented hips used at that time. Poor clinical results based on high wear rates and osteolysis were the reason for these prostheses being abandoned.

The Scandinavian joint replacement registries have shown 95% 10-year survival of the best performing cemented total hip replacement (Havelin et al. 2000, Malchau et al. 2002). 10-year survival of cemented total hips, in patients less than 60 years of age, also exceed 90% with third-generation cementing technique and high-viscosity, well-documented bone-cements (Havelin et al. 2000, Furnes et al. 2001). These results are superior to those of contemporary uncemented prostheses (Havelin et al. 2002, Malchau et al. 2002).

Several modern uncemented stems do very well, with medium-term survival rates higher than 95% (Havelin et al. 2000, Garcia-Cimbrelo et al. 2003). It seems that the problems to be addressed in uncemented hip replacement surgery are the acetabular component and the bearing surfaces. Wear and osteolysis, and subsequent aseptic loosening of the cup constitute the major challenges in uncemented total hip replacements. Nearly half of the hips in our study had been revised one or more times. New articulations with improved materials will hopefully show better long-term clinical results in contemporary uncemented total hip arthroplasty. Until then, we will continue to use cemented total hip arthroplasties for primary hip replacements in all patients, regardless of age.

Contributions of authors

GH planning, conducting and first writer. SAL planning (statistics), writing (statistics), reviewing the writing process. LIH idea, planning, writing.

No competing interests declared.

Aspenberg P, Herbertsson P. Periprosthetic bone resorption: particles vs movement. *J Bone Joint Surg (Br)* 1996; 78: 641-6.

Aspenberg P, van der Vis H. Fluid pressure may cause periprosthetic osteolysis. Particles are not the only thing. *Acta Orthop Scand* 1998; 69 (1): 1-4.

Barrack R L, Castro F P Jr, Szuszczewicz E S, Schmalzried T P. Analysis of retrieved uncemented porous-coated acetabular components in patients with and without pelvic osteolysis. *Orthopedics* 2002; 25 (12): 1373-8.

Bojescul J A, Xenos J S, Callaghan J J, Savory C G. Results of porous-coated anatomic total hip arthroplasty without cement at fifteen years. *J Bone Joint Surg (Am)* 2003; 85: 1079-83.

Byström S, Espehaug B, Furnes O, Havelin L I. Femoral head size is a risk factor for total hip luxation: a study of 42 987 primary hip arthroplasties from the Norwegian Arthroplasty Register. *Acta Orthop Scand* 2003; 74 (5): 514-24.

Callaghan J J, Pedersen D R, Olejniczak J P, Goetz D D, Johnson R C. Radiographic measurement of wear in 5 cohorts of patients observed for 5-22 years. *Clin Orthop* 1995; (317): 14-8

Claus A M, Engh C A Jr, Sychterz C J, Xenos J S, Orishimo K F, Engh C A Sr. Radiographic definition of pelvic osteolysis following total hip arthroplasty. *J Bone Joint Surg (Am)* 2003; 85: 1519-26.

Crowther J D, Lachiewicz P F. Survival and polyethylene wear of porous-coated acetabular components in patients less than fifty years old. *J Bone Joint Surg (Am)* 2002; 84: 729-35.

DeLee J G, Charnley J. Radiological demarcation of cemented sockets in total hip replacement. *Clin Orthop* 1976; (121): 20-32.

Dowd E D, Sychterz C J, Young A M, Engh C A. Characterization of long-term femoral-head-penetration. *J Bone Joint Surg (Am)* 2000; 82: 1102-7.

Ebramzadeh E, Sangiorgio S N, Lattuada F, Kang J-S, Chiesa R, McKellop H A, Dorr L D. Accuracy of measurement of polyethylene wear with use of radiographs of total hip replacements. *J Bone Joint Surg (Am)* 2003; 85: 2378-84.

Emerson R H Jr, Sanders S B, Head W C, Higgins L. Effect of circumferential plasma-spray porous-coating on the rate of femoral osteolysis after total hip arthroplasty. *J Bone Joint Surg (Am)* 1999; 81: 1291-8.

- Furnes O, Lie S A, Espehaug B, Vollset S E, Engesaeter L B, Havelin L I. Hip disease and the prognosis of total hip replacements. A review of 53 698 primary total hip replacements reported to the Norwegian Arthroplasty Register 1987-99. *J Bone Joint Surg (Br)* 2001; 83 (4): 579-86.
- Garcia-Cembrello E, Cruz-Pardos A, Madero R, Ortega-Andreu M. Total hip arthroplasty with use of the cementless Zweymuller Alloclassic system. A ten to thirteen-year follow-up study. *J Bone Joint Surg (Am)* 2003; 85: 296-303.
- Gruen T A, McNeice G M, Amstutz H C. "Modes of failure" of cemented stem-type femoral components. *Clin Orthop* 1979; (141): 17-27.
- Halley D K, Glassman A H. Twenty- to twenty-six-year radiographic review in patients 50 years of age or younger with cemented Charnley low-friction arthroplasty. *J Arthroplasty (Suppl 1)* 2003; 18 (7): 79-85.
- Harris W H. Osteolysis and particle disease in hip replacement. A review. *Acta Orthop Scand* 1994; 65 (1): 113-23.
- Havelin L I, Engesaeter L B, Espehaug B, Furnes O, Lie S A, Vollset S E. The Norwegian Arthroplasty Register: 11 years and 73,000 arthroplasties. *Acta Orthop Scand* 2000; 71 (4): 337-53.
- Havelin L I, Engesaeter L B, Furnes O, Espehaug B, Vollset S E, Lie S A. 5,300 uncemented acetabular cups in young patients. Abstract AAOS, Dallas, USA, 2002.
- Hernandez J R, Keating E M, Faris P M, Meding J B, Ritter M A. Polyethylene wear in uncemented acetabular components. *J Bone Joint Surg (Br)* 1994; 76: 263-6.
- Hopper, R H, Young A M, Orishimo K F, McAuley J P. Correlation between early and late wear rates in total hip arthroplasty with application to the performance of the marathon cross-linked polyethylene liners. *J Arthroplasty (Suppl1)* 2003; 18: 60-7.
- Hubble M J, Eldridge J D, Smith E J, Learmonth I D, Harris W H. Patterns of osteolysis in two different cementless total hip arthroplasties. *Hip Int* 1997; 6: 65-9.
- Huo M H, Brown B S. What's new in hip arthroplasty. *J Bone Joint Surg (Am)* 2003; 85: 1852-64.
- Jones L C, Hungerford D S. Cement disease. *Clin Orthop* 1987; (225): 192-206.
- Kärholm J, Borssen B, Lowenhielm G, Snorrasson F. Does early micromotion of femoral stem prostheses matter? 4-7-year stereoradiographic follow-up of 84 cemented prostheses. *J Bone Joint Surg (Br)* 1994; 76 (6): 912-7.
- Kesteris U, Ilchmann T, Wingstrand H, Önnarfält R. Polyethylene wear in Scanhip arthroplasty with a 22 or 32 mm head. *Acta Orthop Scand* 1996; 67 (2): 125-7.
- Kim Y E, Kim V E. Results of the Harris Galante cementless hip prostheses. *J Bone Joint Surg (Br)* 1992; 74 (1): 83-7.
- Kim Y H, Kim V E M. Uncemented porous-coated anatomic total hip replacement. *J Bone Joint Surg (Br)* 1993; 75: 6-14.
- Kim Y H, Kim J S, Cho S H. Primary total hip arthroplasty with a cementless porous-coated anatomic total hip prostheses: 10-12 year results of prospective and consecutive series. *J Arthroplasty* 1999; 14 (5): 538-48.
- Kim Y H, Oh S-H, Kim J-S. Primary total hip arthroplasty with a second generation cementless total hip prosthesis in patients younger than fifty years of age. *J Bone Joint Surg (Am)* 2003; 85: 109-14.
- Livernore J, Ilstrup D, Morrey B. Effect of femoral head size on wear of the polyethylene acetabular component. *J Bone Joint Surg (Am)* 1990; 72: 518-28.
- Malchau H, Herberts P, Eisler T, Garellick G, Soderman P. The Swedish Hip Replacement Register. *J Bone Joint Surg (Am)* (Suppl 2) 2002; 84: 2-20.
- Mjöberg B. Theories of wear and loosening in hip prosthesis. Wear induced loosening vs loosening-induced wear—a review. *Acta Orthop Scand* 1994; 65 (3): 361-71.
- Nashed R S, Becker D A, Gustilo R B. Are cementless acetabular components the cause of excess wear and osteolysis in total hip arthroplasty? *Clin Orthop* 1995; (317): 19-28.
- Oparaugo P C, Clarke I C, Malchau H, Herberts P. Correlation of wear debris-induced osteolysis and revision with volumetric wear-rates of polyethylene. *Acta Orthop Scand* 2001; 72 (1): 22-8.
- Orishimo K F, Sychterz C J, Hopper R H Jr, Engh C A. Can component and patient factors account for the variance in wear rates among bilateral total hip arthroplasty patients? *J Arthroplasty* 2003a; 18: 154-60.
- Orishimo K F, Claus A M, Sychterz C J, Engh C A. Relationship between polyethylene wear and osteolysis in hips with a second-generation porous-coated cementless cup after seven years of follow-up. *J Bone Joint Surg (Am)* 2003b; 85: 1095-9.
- Puri L, Wixson R L, Stem S H, Kohli J, Hendrix R W, Stulberg S D. Use of helical computed tomography for the assessment of acetabular osteolysis after total hip arthroplasty. *J Bone Joint Surg Am* 2002; 84 (4): 609-14.
- Røkkum M, Reigstad A. Polyethylene wear with an entirely HA-coated total hip replacement. *Acta Orthop Scand* 1998; 69 (3): 253-8.
- Ryd L, Albrektsson B E, Carlsson L, Dansgaard F, Herberts P, Lindstrand A, Regner L, Toksvig-Larsen S. Roentgen stereophotogrammetric analysis as a predictor of mechanical loosening of knee prostheses. *J Bone Joint Surg (Br)* 1995; 77 (3): 377-83.
- Santavirta S, Hoikka V, Eskola A, Konttinen Y T, Paavilainen T, Tallroth K. Aggressive granulomatous lesions in cementless total hip arthroplasty. *J Bone Joint Surg (Br)* 1990; 72: 980-4.
- Schmalzried T P, Jasty M, Harris W H. Periprosthetic bone loss in total hip arthroplasty. Polyethylene wear debris and the concept of the effective joint space. *J Bone Joint Surg (Am)* 1992; 74: 849-63.
- Shih C H, Lee P C, Chen J H, Tai C L, Chen L F, Wu J S, Chang W H. Measurement of polyethylene wear in cementless total hip arthroplasty. *J Bone Joint Surg (Br)* 1997; 79 (3): 361-5.
- Stulberg S D, Wixson R L, Adams A D, Hendrix R W, Bernfield J B. Monitoring pelvic osteolysis following total hip replacement surgery: An algorithm for surveillance. *J Bone Joint Surg (Am)* 2002; 84: 116-22.

- Sychterz C J, Moon K H, Hashimoto Y, Terefenko K M, Engh C A Jr, Bauer T W. Wear of polyethylene cups in total hip arthroplasty. *J Bone Joint Surg (Am)* 1996; 78: 1193-200.
- Tanzer M, Maloney W J, Jasty M, Harris W H. The progression of femoral cortical osteolysis in association with total hip arthroplasty without cement. *J Bone Joint Surg (Am)* 1992; 3: 404-10.
- Thanner J, Kärrholm J, Malchau H, Herberts P. Poor outcome of the PCA and Harris-Galante hip prostheses. *Acta Orthop Scand* 1999; 70 (2): 155-62.
- Willert H G, Ludwig J, Semlitsch M. Reaction of bone to methacrylate after hip arthroplasty: a long-term gross, light microscopic, and scanning electron microscopic study. *J Bone Joint Surg (Am)* 1974; 56 (7): 1368-82.
- Willert H G, Bertram H, Buchhorn G H. Osteolysis in alloarthroplasty of the hip. *Clin Orthop* 1990; (258): 95-107.
- Wroblewski B M, Siney P D, Fleming P A. Wear of the cup in the Charnley LFA in the young patient. *J Bone Joint Surg (Br)* 2004; 86 (4): 498-503.
- Xenos J S, Hopkinson W J, Callaghan J J, Heekin R D, Savory C G. Osteolysis around an uncemented cobalt chrome total hip arthroplasty. *Clin Orthop* 1995; (317): 29-36.