

PART II – NEUROLOGICAL DISORDERS

CHAPTER 12  
CRANIAL NERVE DISORDERS

**Dr William P. Howlett**  
2012

Kilimanjaro Christian Medical Centre,  
Moshi,  
Kilimanjaro,  
Tanzania

BRIC 2012 

University of Bergen  
PO Box 7800  
NO-5020 Bergen  
Norway

NEUROLOGY IN AFRICA

William Howlett

Illustrations: Ellinor Moldeklev Hoff, Department of Photos and Drawings, UiB

Cover: Tor Vegard Tobiassen

Layout: Christian Bakke, Division of Communication, University of Bergen

Printed by Bodoni, Bergen, Norway 

Copyright © 2012 William Howlett

NEUROLOGY IN AFRICA is freely available to download at  
[www.uib.no/cih/en/resources/neurology-in-africa](http://www.uib.no/cih/en/resources/neurology-in-africa)

ISBN 978-82-7453-085-0

#### Notice/Disclaimer

This publication is intended to give accurate information with regard to the subject matter covered. However medical knowledge is constantly changing and information may alter. It is the responsibility of the practitioner to determine the best treatment for the patient and readers are therefore obliged to check and verify information contained within the book. This recommendation is most important with regard to drugs used, their dose, route and duration of administration, indications and contraindications and side effects. The author and the publisher waive any and all liability for damages, injury or death to persons or property incurred, directly or indirectly by this publication.

# CONTENTS

<b>CRANIAL NERVE DISORDERS</b>	<b>287</b>
OLFACTORY NERVE . . . . .	287
PUPILLARY RESPONSES . . . . .	287
THE LIGHT REFLEX . . . . .	288
THE ACCOMMODATION REFLEX . . . . .	289
PUPILLARY DISORDERS . . . . .	289
VISUAL ACUITY (VA) . . . . .	291
VISUAL FIELDS . . . . .	292
FUNDOSCOPY . . . . .	293
OCULOMOTOR, TROCHLEAR AND ABDUCENS: EYE MOVEMENTS . . . . .	295
SQUINT. . . . .	298
NYSTAGMUS . . . . .	299
TRIGEMINAL NERVE . . . . .	300
FACIAL NERVE . . . . .	301
BELL'S PALSY . . . . .	301
ACOUSTIC NERVE . . . . .	303
HEARING. . . . .	303
VERTIGO/DIZZINESS . . . . .	304
BENIGN PAROXYSMAL POSITIONAL VERTIGO (BPPV) . . . . .	304
ACCESSORY NERVE . . . . .	305
GLOSSOPHARYNGEAL, VAGUS AND HYPOGLOSSAL NERVES. . . . .	305

# CHAPTER 12

---

## CRANIAL NERVE DISORDERS

Cranial nerve disorders are common neurological disorders. The clinical skills needed to examine the individual cranial nerves are presented in chapter 1. The overall aim of this chapter is to present the main cranial nerve disorders and to integrate examination and localization in their diagnosis. After reading the chapter the student should be able to localize and diagnose main disorders affecting pupils, vision, eye movements, facial sensation and movements, hearing, speech and swallowing.

### OLFACTORY NERVE

#### Smell

Neurological disorders involving the olfactory nerve are uncommon and the olfactory nerve is rarely tested in day to day clinical practice. During a routine neurological examination it is sufficient to ask the patient if there is a loss or decrease in the sense of smell (anosmia). Frequently patients are unaware of a loss of smell or may only complain of losing their sense of taste. This is because both smell and taste are used together to appreciate the flavors of food and drink. If there is a loss or deterioration in smell, then each nostril should be tested separately as outlined in chapter 1. The most common cause of transient loss of smell is mucosal swelling in the nose or sinuses as a result of local infection e.g. head cold, allergy or smoking. Anosmia may occur after a head injury when there is a shearing injury to the olfactory bulb and its central connections through the cribriform plate. A rare cause of unilateral anosmia is a meningioma in the olfactory groove. Olfactory hallucinations are a feature of temporal lobe epilepsy.

#### Optic nerve

Disorders affecting the optic nerve are common and clinical assessment involves a history and examination. The history involves asking about a loss or decrease in vision, double vision, pain and headache and their mode of onset, progression and time course. The examination of the optic nerve includes testing the *pupillary responses*, *visual acuity*, *visual fields* and *fundoscopy*. Details concerning the technique of examination have already been set out in chapter 1.

### PUPILLARY RESPONSES

#### Pupillary size and reactions

Both pupils should be normal in size (2-6 mm), equal, central and circular (ECC). The iris controls the size of the pupil. It does this by means of two groups of muscle fibres supplied by

the autonomic nervous system. The sphincter pupillae is a circular constrictor smooth muscle supplied by the parasympathetic and the dilator pupillae is a radial smooth muscle supplied by the sympathetic nervous system. The balance between these accounts for normal pupil size. The important aspects in their examination are summarized below.

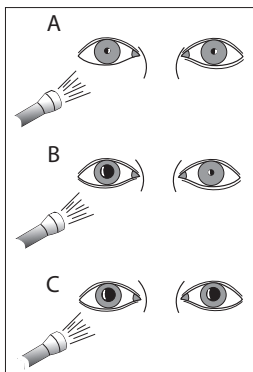
### Key points

- look at the pupils and note their size & whether they are equal or not
- shine a bright light into one eye and look at pupil reaction in that eye (direct light reflex)
- repeat and look at the pupillary reaction in the other eye (consensual reflex)
- do the same for the other eye

## THE LIGHT REFLEX

### Pathway for pupillary constriction (parasympathetic)

A light (torch) is shone in each eye separately whilst asking the patient to fix on an object at least 3m away. The light in one eye sends an *afferent* impulse along the optic nerve to the midbrain. The afferent anatomical pathway to the midbrain involves the retina, optic nerve, chiasm and optic tract. From the midbrain, a second order neurone travels to the Edinger-Westphal nucleus on both the same and opposite side of the midbrain. From there, *efferent* parasympathetic fibres travel back to the eyes, via the outside of the oculomotor nerve to the ciliary ganglion and to the constrictor sphincter pupillae. If all pathways are working normally, then the pupils in both eyes constrict equally and at the same time in response to light shone in one eye (Fig 12.1A). This represents the normal *light reflex* in the light stimulated eye and the *consensual reflex* (response) in the other eye. A lesion anywhere along that pathway results in a dilated pupil (mydriasis) on the affected side. The resulting defect is called an *afferent pupil defect* if it affects the optic pathway (Fig 12.1C) and an *efferent pupil defect* if it affects the parasympathetic pathway (Fig 12.1 B).



- A. **normal:** both pupils constricted
- B. **efferent defect:** shine torch in affected eye (dilated pupil): light is perceived but affected pupil is unable to react because of a defect in the efferent pathway. Because the afferent pathway is unaffected, there is a normal consensual response in the other eye
- C. **afferent defect:** shine torch in affected eye (dilated pupil); light is not perceived and affected pupil is unable to react because of a defect in the afferent pathway. Because the afferent pathway is affected, there is no consensual response in the other eye

Figure 12.1 Testing for afferent and efferent pupillary disorders

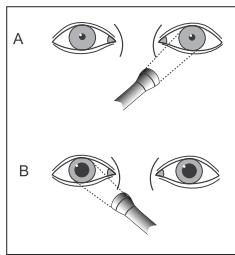
### Pathway for pupillary dilatation (sympathetic)

The sympathetic fibres descend on the same side from the hypothalamus via the lateral brain stem to the cervical spinal cord leaving the cord anteriorly at C8, T1. The fibres then ascend on

the same side in the sympathetic chain to the superior cervical ganglion and from there on the outside of the wall of the internal carotid artery to the ciliary ganglion and the dilator pupillae in the iris. A lesion anywhere along its path results in a constricted, small pupil (*miosis*). Because sympathetic nerves also supply fibres to the ipsilateral eyelid (levator palpebrae superioris), the orbit and adjacent skin, a lesion in the sympathetic chain also results in *ptosis, enophthalmos and anhydrosis*. The presence of all four signs together is called *Horner's syndrome*, (Table 12.1).

### Swinging torch test

A *relative afferent pupil defect* is a sign of optic neuritis in the eye being examined. It can be demonstrated by the swinging torch test, during which light is repeatedly shone alternatively into the good eye and the affected eye. When light is shone on the non affected good eye, both pupils constrict normally, however, when the light is transferred briskly to the affected or bad eye both pupils dilate (Fig. 12.2). The explanation for this is that the weak direct effect on the bad eye is counterbalanced by the withdrawal of the stimulus from the good eye and the loss of the consensual response. This is a sign of incomplete optic neuropathy and is most commonly seen in optic neuritis.



- A. Both pupils constrict on shining light in unaffected left eye  
 B. Both pupils dilate on shining light in affected right eye (relative afferent pupillary defect)

**Figure 12.2** Testing for a relative afferent pupillary defect.

## THE ACCOMMODATION REFLEX

When using near vision the eyes converge and pupils constrict, this is the *accommodation reflex*. The afferent component of the accommodation reflex is conveyed in the optic nerve and the efferent pathway is less certain but does involve the visual cortex and some of the same pathways as the efferent light reflex. Testing for the presence of the accommodation reflex has become less useful in clinical practice especially with the decrease in the frequency of neurosyphilis worldwide (Chapter 6).

## PUPILLARY DISORDERS

Disorders affecting pupils occur at four main sites; *the eye, the afferent or optic pathway*, the efferent or *parasympathetic* pathway and the *sympathetic* pathway (Table 12.1). The main disorders affecting the eye include infection, inflammation and trauma.

Neurological disorders affecting the *afferent pathway* are relatively common in Africa. These are termed optic neuropathies and result in *loss of vision* and *afferent pupil defects* (Fig 12.1C). The main causes are inflammatory (optic neuritis), nutritional and toxic. However, in many cases their cause is unknown.

Disorders affecting the *efferent pathway* (Fig 12.1 B) also occur. If the oculomotor (3<sup>rd</sup> nerve) is compressed on its path from the brain stem to the eye, then damage to the parasympathetic

fibres which travel on the outside will result in a *fixed, dilated pupil* on that side. There may also be features of 3rd nerve palsy depending on the extent of the compression. Important neurological causes include raised intracranial pressure above the tentorium and an aneurysm compressing the nerve.

Disorders affecting the sympathetic pathway can occur anywhere along its pathway from the lateral brainstem to the eye, resulting in *Horner's syndrome*. A *small constricted pupil* and slight ptosis are characteristic. Neurological causes are uncommon and mainly involve lesions in its central pathway. Primary lung cancer involving the apex of the lung is an important cause, although this disorder is still relatively uncommon in Africa.

Other disorders affecting pupils include the *Holmes Adie pupil* which is a benign condition usually affecting one side which is found in women in their 20-40s. The affected pupil is dilated with an impaired response to light but also accommodates slowly. It may be or becomes bilateral and is also associated with absent ankle reflexes (Table 12.1). The *Argyll-Robertson pupil* is a small and irregular pupil that accommodates to near vision but has a reduced or absent light reflex (Table 12.1). It was a well known sign of neurosyphilis but is very uncommon in clinical practice nowadays.

Table 12.1 Characteristics of main pupillary disorders

Disorder/site	Neurological findings	Main Causes
<b>Optic neuritis</b> (optic nerve, afferent)	<b>pupils dilated,</b> (afferent pupil defect)	inflammatory, infections, nutritional (vit B def), konzo, TAN* toxic (alcohol, drugs)
<b>Third nerve palsy</b> (parasympathetic, efferent)		
<b>compression</b>	<b>pupil dilated,</b> (efferent pupil defect) ptosis (partial or full), eye in down and out position, paralysis of adduction & up/down movements	↑ICP, SOL, aneurysm, cavernous sinus thrombosis
<b>non compression</b>	<b>pupil not dilated,</b> otherwise the same as in <b>compressive lesions</b>	diabetes, meningitis
<b>Horner's syndrome</b> (sympathetic fibres)	<b>ptosis</b> (mild), <b>miosis</b> (pupil < other pupil), <b>enophthalmos</b> (eye less protruding), <b>loss of sweating</b> (may be absent)	cluster headache, apical lung tumours, cervical cord/brain stem lesions, dissecting aneurysms of carotid arteries
<b>Holmes-Adie pupil</b> (iris)	pupil(s) dilated, impaired to light (reacts slowly to near light)	variant of normal, autoimmune
<b>Argyll-Robertson pupil</b> (frontal lobe)	<b>both pupils small &amp; irregular,</b> accommodate but no reaction to light	syphilis & diabetes

\* tropical ataxic neuropathy

## Key points

- pupillary disorders can arise from disorders of the eye, optic, parasympathetic & sympathetic nerves
- commonly found in association with disorders of eyelid (Horner's) and eye movements (3rd N. palsy)
- afferent disorders (optic nerve) are mainly caused by inflammation & toxicity
- efferent disorder (parasympathetic) is mainly caused by pressure from the outside on the 3rd nerve
- Horner's syndrome is caused by local compression along the sympathetic nerve pathway

## VISUAL ACUITY (VA)

VA is tested using a Snellen chart and the result is expressed as a fraction; the numerator being the distance between the chart and the patient (usually 6 metres depending on the size of the chart) divided by the denominator which is the smallest full line of letters identified correctly by the patient (Chapter 1). 6/6 is normal vision whereas 6/60 represents poor VA, meaning the patient can only read the largest letter on the chart. If the largest letter cannot be read from a distance of 6 metres, then the chart should be brought closer to the patient and VA rechecked. If this still fails, then the patient's ability to correctly count fingers, identify hand movements or perceive light should be checked in each eye respectively. Remember to check patients VA wearing glasses (if the patient uses them) and recheck decreased VA with a pin hole to exclude cataracts and refractive errors as a likely cause. Illustrative charts are available for illiterate patients and hand held reading charts can be used to formally test near vision. Identifying the various sizes of letters from a local newspaper can suffice for a general impression of VA. The main causes of decreased VA are ocular. These include refractive errors in the lens, cataracts and retinal diseases, particularly of the macula. The main neurological causes are disorders affecting the *optic nerve*.

## Key points

- first ask if the patient can see, using both eyes or with glasses
- test VA in each eye separately using a Snellen chart or a hand held chart or a newspaper
- if pt is still unable to read large letters check VA by counting fingers, hand movements & light perception
- commonest causes of decreased VA are refractive lens errors & cataracts
- most frequent neurological cause of decreased VA is optic neuropathy

## Colour vision

Colour vision is not routinely tested but can be tested using a set of *Ishihara colour plates*. These consist of a series of plates of coloured dots arranged so that persons with normal colour vision can see and identify correctly, a hidden set of numbers or trails arranged in different colours on each plate of dots. The patient must be able to read the first (control) plate before proceeding and each eye should be tested separately. Defective colour vision may be inherited and is a feature of diseases involving the optic nerve in particular optic neuritis.



## VISUAL FIELDS

Patient's visual fields are tested by confrontation. The confrontation method is useful for detecting large visual field defects in the visual pathway. In order to interpret and localize the main findings correctly it is important to remember the following three points. The *nasal side of each eye* picks up the *opposite* or *temporal half* of the visual field whilst *the temporal side of the eye* picks up the *opposite* or *nasal half* of the visual field (Fig. 12.3). The optic nerve fibres serving *the nasal sides* of the retina *decussate* to the *opposite side* at the level of the *optic chiasm* (Fig. 12.3). Finally by convention the patient's visual fields are always *described and illustrated* from the *patient's own perspective i.e. as if the patient were looking outwards* (Fig. 12.4). The main visual defects, their sites of origin and causes are outlined below (Table 12.2).

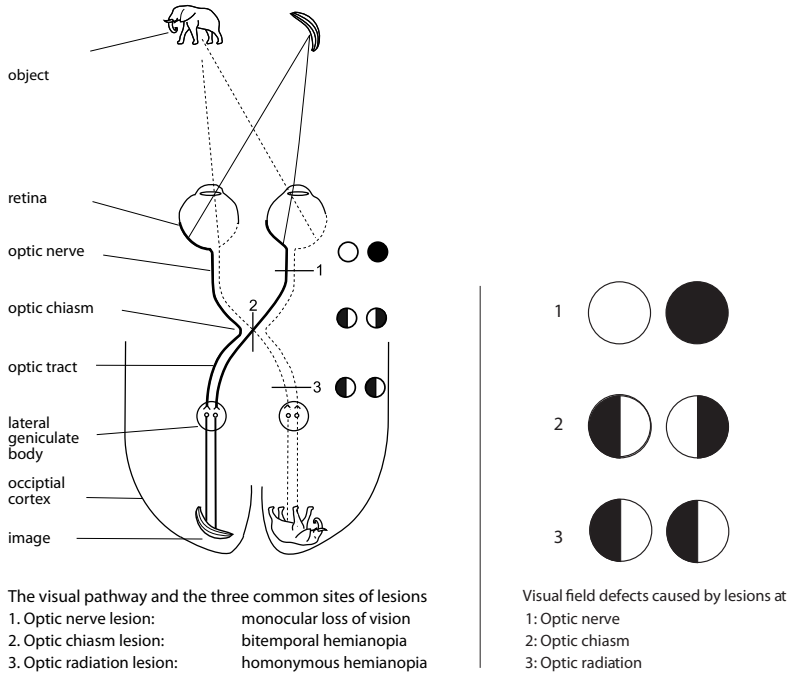


Figure 12.3 & 4 The three most common sites of visual field defects

Table 12.2 Visual field defects, sites & causes

Field defect	Site	Main causes
1. monocular	optic nerve	neuritis, vasculitis, <b>compressive: aneurysm, meningioma</b>
2. bitemporal hemianopia	optic chiasm	pituitary adenoma, craniopharyngioma
3. homonymous hemianopia	optic tract/occipital lobe	stroke, SOL, tumour

## Key points

- check for visual field defects in both eyes by confrontation
- if defect is suspected, then test each eye individually
- define the limits or extent of any field defect found
- main sites of origin of visual field defects are optic nerve, chiasm & optic tract/radiation
- most common defect is homonymous hemianopia secondary to a stroke/SOL

## FUNDOSCOPY

The technique and details of fundoscopy are described in chapter 1. In summary, it is important to look at and inspect the optic disc, blood vessels and retinal background. An example of a normal fundus is shown in fig 12.5. Disorders affecting the optic nerves may result in swelling of the optic disc, called *papilloedema* or wasting of the optic nerve called *optic atrophy*. Both of these disorders can be easily seen and identified by fundoscopy and are illustrated below (Figs 12.5 & 6). Examples of retinopathy in hypertension and diabetes are included for comparison (Fig 12.7).

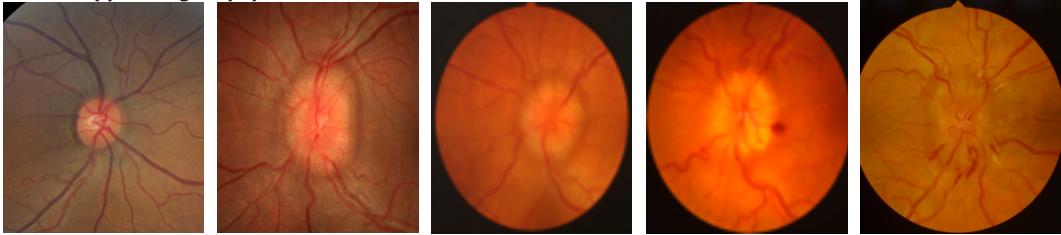
### Papilloedema

Papilloedema is swelling of the optic disc sometimes with surrounding retinal haemorrhages and exudates. It is nearly always caused by raised intracranial pressure but it may also be due to inflammation of the optic nerves when it is termed *optic neuritis* or *papillitis*. Papilloedema is nearly always bilateral and occurs mostly without visual symptoms. On examination VA is typically normal but the blind spot may be enlarged and the peripheral visual fields constricted. Fundoscopy confirms features of papilloedema, a swollen and sometimes haemorrhagic disc (Fig. 12.5). If the papilloedema is long standing, then VA is lost due to increased pressure around the optic nerve and the optic disc becomes atrophied and pale. The main cause of papilloedema in Africa is raised intracranial pressure secondary to either infections, (cryptococcal and TB meningitis), space occupying lesions (SOL) or malignant hypertension (Table 12.3).

### Optic neuritis

Optic neuritis is inflammation of the optic nerve or nerve head. It is usually bilateral but may occasionally be unilateral. It presents with loss of vision and occasionally a dull ache behind the eyes. On examination, VA is decreased or lost and there may be afferent pupil defects, if both eyes are involved. Fundoscopy may show *papilloedema* in the acute stage; however the accompanying loss of VA suggests optic neuritis rather than papilloedema as the true cause. In long standing cases there is *optic atrophy* (Fig. 12.6). The main disorders causing optic neuritis are inflammatory, toxic, nutritional and infections (Table 12.4).

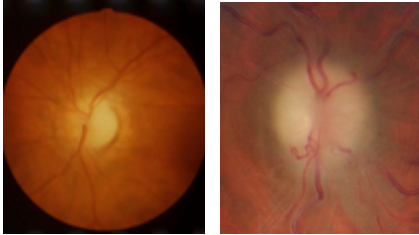
**Fundoscopy findings in papilloedema**



Normal fundus

Loss of optic cup, disc swelling, indistinct & elevated disc margins, haemorrhages & exudates around the disc

**Fundoscopy findings in chronic papilloedema**



Pallor, loss of optic cup & disc swelling

**Figure 12.5** Fundoscopy findings in papilloedema

**Table 12.3** Main causes of papilloedema

Disorder	Disease
<b>raised intracranial pressure</b>	cryptococcus/TB, malignant hypertension, SOL
<b>optic nerve lesions</b>	tumours, leukaemia, Drusen
<b>inflammatory</b>	Devic's disease

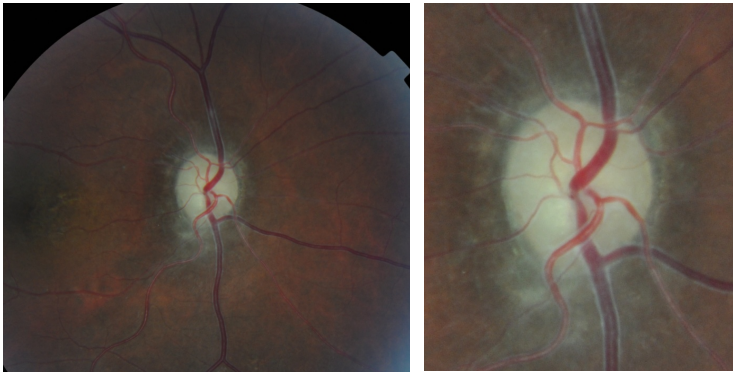**Optic atrophy**

Optic atrophy can be caused by any chronic optic nerve disease process (Table 12.4). The nerve which was swollen acutely in inflammatory optic neuritis and in cases of long standing papilloedema later when chronic becomes *pale* and *atrophic*. Optic atrophy is characterized clinically by a loss of visual acuity coupled with a clearly visible pale/white optic disc with clear margins on fundoscopy (Fig 12.6). The treatment is directed at the underlying disorder. It is important to exclude chronic glaucoma which may present with optic atrophy and painless loss of vision, however it is usually monocular.

**Table 12.4** Main causes of optic atrophy

Disorder	Disease
<b>chronic raised intracranial pressure</b>	any cause
<b>post infectious</b>	TB, syphilis, viral
<b>post inflammatory</b>	Devic's disease, autoimmune disorders
<b>toxic</b>	alcohol, methanol, isoniazid, ethambutol, quinine
<b>nutritional</b>	Konzo, TAN*, Vitamin B deficiency
<b>vascular</b>	ischaemia
<b>hereditary</b>	Leber's optic neuropathy

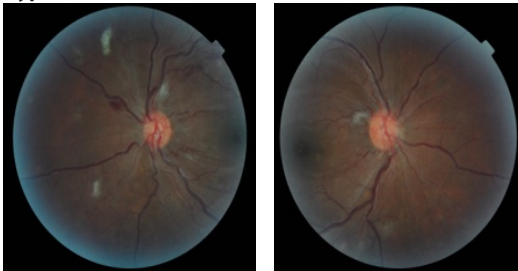
\* *tropical ataxic neuropathy*



Pale white & atrophic optic disc

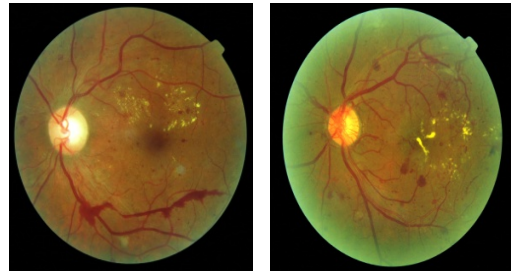
Figure 12.6 Fundoscopy findings in optic atrophy

**Hypertension**



Haemorrhages & cotton wool exudates

**Diabetes**



Haemorrhages, perimacular exudates & new vessel formation

Figure 12.7 Fundoscopy findings in hypertension and diabetes

**Key points**

- is essential to be able to use the ophthalmoscope
- main disorders are papilloedema & optic atrophy
- in papilloedema the patient sees well but the doctor can't see the disc well
- in optic neuritis the patient can't see well but the doctor can see the disc well
- it is important to be able to distinguish the other main causes of retinopathy

**OCULOMOTOR, TROCHLEAR AND ABDUCENS: EYE MOVEMENTS**

Disorders affecting eye movements are common. The third, fourth and sixth nerves working together are responsible for normal eye movements. A lesion in any one of these nerves results in a loss of movement in the direction of action of the paralyzed muscles and double vision (diplopia), which is most marked when looking in the direction of action of the paralysed muscles. Eye movements are controlled by two mechanisms: *tracking* and by *voluntary saccades (jumps)*. Tracking or pursuit occurs when we look at and follow a moving object without thinking. This smooth action is controlled automatically in the occipital lobe and brain stem where all eye movements are joined up together into what are termed *conjugate eye* movements. Tracking is tested by asking the patient to follow your finger moving in both vertical and horizontal planes just as you would do when testing for normal eye movements (Chapter 1).

Observe carefully for any impairment, jerkiness (nystagmus) or loss of eye movement (paralysis) in one or more directions and enquire if there is any double vision. *Voluntary saccadic eye movements* originate in the frontal lobe and are tested by asking the patient to look at or fixate between two alternating targets e.g. right fist to left index finger and vice versa. This is an uncommon source of disordered eye movements.

**Diplopia**

Diplopia or double vision can be either binocular or monocular in origin. Monocular diplopia is distinctly uncommon and is nearly always optical in origin. The majority of *diplopia* occurs when the eyes fail to look together in the same direction and the resulting images no longer correspond with each other. This imbalance between the eyes may occur as a result of disorders at different sites. These sites are at the level of the brain stem, the individual 3<sup>rd</sup> 4<sup>th</sup> or 6<sup>th</sup> cranial nerves, the neuromuscular junction, and the eye muscles. Disorders affecting the individual cranial nerves account for most cases and are the most common cause of diplopia (Table 12.5).

**Table 12.5** Main sites & causes of diplopia

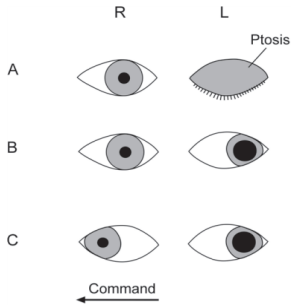
Sites	Causes
3 <sup>rd</sup> , 4 <sup>th</sup> & 6 <sup>th</sup> nerves	↑ICP, vascular, trauma, infections, diabetes
brain stem	stroke, inflammation, SOL
neuromuscular junction	myasthenia gravis
muscle	myopathy (thyroid disorders, hereditary)

With disorders affecting individual cranial nerves the double vision is nearly always described by the patient as sudden in onset. The separation of images is described as lying either side by side in the horizontal plane or on top of each other in the vertical plane. In most patients presenting with double vision, the muscle site of origin becomes apparent whilst observing the patient’s eyes either at rest or during normal eye movements. If the origin is not readily apparent, then it is necessary to find out the direction in which the diplopia is greatest and in which plane the images are maximally separated. In general the double vision is always maximal in the direction of action of the paralyzed muscle. The false image is always the outermost image, and arises from the affected eye. In order to test for this, each of the patient’s eyes is covered in turn and the eye from which the outer image disappears is noted and this is the affected eye. Horizontal diplopia (i.e. images side by side) is due to weakness of the medial rectus (3<sup>rd</sup> CN) or the lateral rectus (6<sup>th</sup> CN) and vertical or oblique diplopia (i.e. the images on top/side) is due to weakness of other muscles (3<sup>rd</sup> or 4<sup>th</sup> CNs).

**Third nerve palsy**

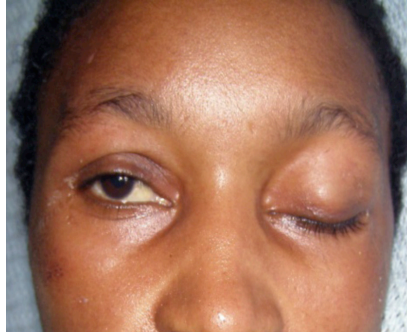In a complete 3<sup>rd</sup> *nerve palsy*, there is full ptosis and the eye (when it is uncovered), is seen to lie in the down and out position as a result of the unopposed action of the 4<sup>th</sup> and 6<sup>th</sup> CNs (Fig. 12.8). On attempting to test for normal eye movements, there is paralysis of adduction and up and down movements on the affected side (Figs. 12.8-9). If the parasympathetic fibres which lie on the outside of the 3<sup>rd</sup> CN (the efferent limb of the light reflex) are compressed, then the pupil on that side is dilated and fixed (non responsive to light). This is frequently termed surgical 3<sup>rd</sup> *nerve palsy* because it indicates mechanical compression from outside the nerve which may require urgent surgical attention. A common cause of painful unilateral 3<sup>rd</sup> nerve palsy is an aneurysm arising on the posterior communicating artery on the Circle of Willis. If the pupil is spared or is not dilated then this is often termed a medical 3<sup>rd</sup> *nerve palsy* and these may resolve spontaneously over the next 3-4 months. The most common causes of third

nerve palsy are tentorial herniation secondary to raised intracranial pressure, aneurysms, DM and infections. Less common causes include granuloma (Tolosa Hunt syndrome) and lesions in the cavernous sinus.

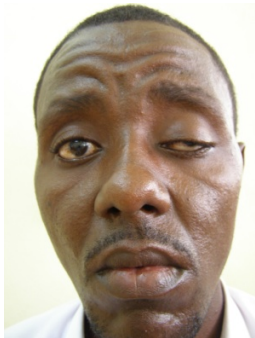

**Left oculomotor palsy (compressive type)**

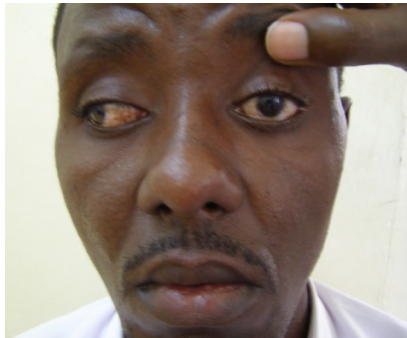- A Ptosis
- B Pupillary dilatation (with the eyelid held open)
- C Failure of adduction of the left eye on looking towards the right



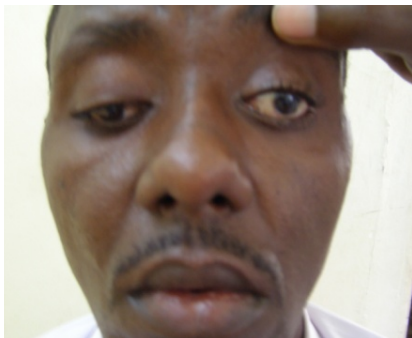
**Figure 12.8** Oculomotor palsy (left)



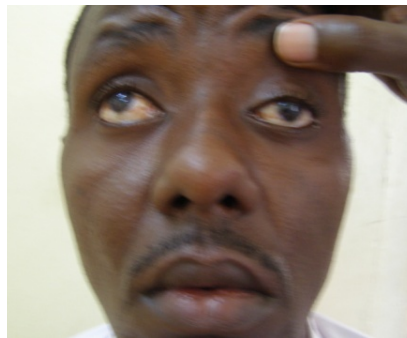
**Ptosis & left eye down & out (looking ahead)**



**Failure of adduction left eye (looking right)**



**Failure of down gaze left eye (looking down)**



**Failure of up gaze left eye (looking up)**

**Figure 12.9** Oculomotor palsy (left)

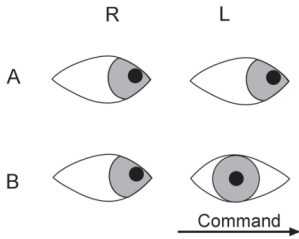


**Fourth nerve palsy**

In *4<sup>th</sup> nerve palsy*, there is failure to depress the adducted eye. The diplopia is most noticeable by the patient on walking down steps or stairs and he tries to compensate by tilting the head away from the paralysed eye. Isolated *4<sup>th</sup> nerve palsies* are uncommon but do occur in association with DM, head trauma and cavernous sinus lesions. Uncomplicated *4<sup>th</sup> nerve palsies* usually resolve with time.

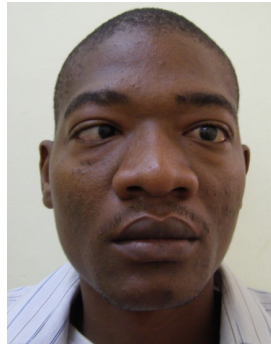**Sixth nerve palsy**

In *6<sup>th</sup> nerve palsy*, the patient is unable to abduct the affected eye and has diplopia. The diplopia is most noticeable by looking horizontally in the direction of action of the paralysed muscle (Fig. 12.10). The eye at rest is held in the adducted position because of unopposed action of the medial rectus (Fig. 12.10). It is a common cranial nerve palsy occurring in diabetes and hypertension and usually resolves spontaneously. However it may also be a false localizing sign in raised intracranial pressure, because during its long intracranial course it is vulnerable to increased pressure as it passes over the sphenoid ridge.



**Left sixth nerve palsy**

A Normal conjugate eye movement to the left  
 B Failure of abduction of left eye on looking to the left



**Figure 12.10** Sixth nerve palsy (left sided)

**Key points**

- diplopia arises from either CN disorders or diseases of neuromuscular junction or muscle
- most common cause are CN disorders, 3rd 4th & 6th
- double vision is maximal in the direction of gaze of the paralysed muscle
- false image is always the outer one
- false image arises in the affected eye

**SQUINT**

A squint occurs when the visual axes of both eyes are no longer together. It is a common disorder in children when it is usually termed a *non paralytic squint* (NPS). This is in contrast to *paralytic squint* (PS) which mostly affects adults. The main causes of squint in children are refractive lens problems. Diplopia does not occur in non paralytic squint whereas it does occur in paralytic squint. This is because in children the brain gets accustomed over years to false image and suppresses it. If the non paralytic squint continues beyond the age of 6 years, then a permanent lazy eye develops with poor or no vision in that eye.

The diagnostic feature of a *non paralytic squint* is that movements are full in each eye when tested separately. This is in contrast to *paralytic squint* where movement in the affected eye is usually not full. This can be easily demonstrated by testing movements in each eye individually in turn, whilst at the same time covering the other eye. This is termed *the cover test*. In *non paralytic squint* when conjugate eye movements are tested together, a weakness in one or both eyes may become apparent. To test for *non paralytic squint* first ask the patient to look with both eyes at your right eye and cover his left eye. Then uncover his left eye and cover his right eye and look to see if his left eye has to correct in order to look back at your right eye. Repeat the same sequence covering the right eye. The test is positive when the squinting eye immediately moves to fixate when attempting to look at an object, in this case your right eye. This is the basis for correction of a non paralytic squint in childhood. This is achieved by the wearing of a patch over the good eye thereby forcing the bad eye to work fully. If wearing a patch over the good eye fails then corrective surgery may be necessary. Squints are usually classified as non paralytic or paralytic. They may also be classified as congenital or acquired, as affecting one eye or both eyes and as convergent or divergent.

### Key points

- NPS is common in children whereas PS is common in adults
- in NPS full movement is preserved in each eye when examined individually
- in NPS the cover test reveals weakness in one or both eyes
- correction of NPS should take place before 6 yrs of age
- treatment includes wearing a patch over the good eye +/- corrective surgery

## NYSTAGMUS

*Nystagmus* is an abnormal rhythmic oscillatory or to and fro movement of the eyes. Characteristically it has a slow drift in one direction with a fast corrective phase in the other direction. By convention, nystagmus is described in the direction of the fast phase. Disorders causing nystagmus are classified as *peripheral* (arising from the vestibular system/nerve), *central* (arising from the brain stem/cerebellum) and *ocular* (arising from the eye, retina/lens). In order to check for the presence of nystagmus, you must first inspect the patient's eyes in the at rest or primary position with the eyes looking ahead and then ask the patient to follow your finger with both eyes, moving vertically and horizontally as if testing for normal eye movements. Be careful not to move the eyes too far laterally (<30 degrees from midline), otherwise a few beats of non sustained physiological nystagmus can occur normally. Note if any nystagmus occurs and whether it is symmetrical or jerky and the direction of the fast phase e.g. horizontal, vertical or rotary and the position of the eyes when the nystagmus occurs and is most marked.

The characteristics of the nystagmus help to localize its site of origin. If it is symmetrical with movements of the same speed in both directions this is called *pendular nystagmus*. Pendular nystagmus is nearly always *ocular* in origin and is seen in persons with longstanding blindness or impaired vision; a major cause is congenital cataracts. If the nystagmus is characterized by a slow phase in one direction followed by a fast corrective phase in the opposite direction this is called  *jerk nystagmus*. This is the most common type and is seen in both peripheral and central disorders. Jerk nystagmus occurs only on attempted gaze holding in any direction (up, down, left or right) and is not present in the primary position looking straight ahead. The



fast phase determines the direction of the nystagmus i.e. *upbeat or downbeat nystagmus*. Jerk nystagmus is commonly seen in cerebellar disease. The direction of the fast phase is towards the lesion in central disorders of the brain stem and cerebellum, and away from the lesion in peripheral disorders in the vestibular system. The commonest causes of jerk symmetrical horizontal nystagmus with the quick phase in the direction of gaze are drugs or medications e.g. phenytoin and alcohol. *Rotary nystagmus* can occur in both peripheral and central disorders, though mainly in disorders of the peripheral vestibular system. The main distinguishing clinical features between peripheral and central nystagmus are presented below in Table 12.6.

**Table 12.6** Key clinical features distinguishing peripheral and central nystagmus

Clinical features	Peripheral (vestibular nerve & labyrinth)	Central (brain stem and cerebellum)
<b>main causes</b>	neuronitis, BPPV* Ménière's disease	vascular, drugs, alcohol, structural
<b>duration of illness</b>	short (3-6 weeks)	long (often years)
<b>duration of nystagmus</b>	<60 secs	continuous
<b>direction</b>	away from lesion, horizontal, unilateral	towards lesion, multidirectional
<b>latency/vertigo/vomiting/worsened by position and fatigues</b>	yes	no
<b>associated neurological signs</b>	no	yes

\* *benign paroxysmal positional vertigo*

### Key points

- decide whether nystagmus is present
- describe the type, direction & position it occurs maximally
- determine whether it is peripheral or central
- persistent nystagmus suggests a central origin
- vertigo, vomiting & worsening with change in position suggests a peripheral origin

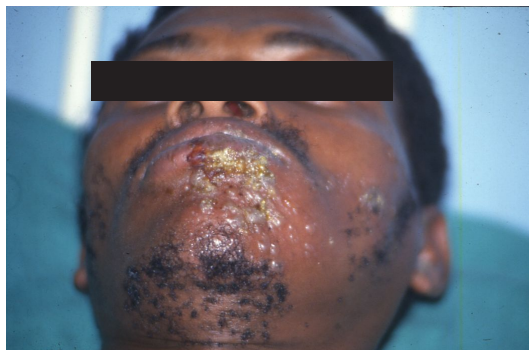## TRIGEMINAL NERVE

The *fifth nerve* has three branches, *ophthalmic V1, maxillary V2 and mandibular V3*. It is a mixed motor and sensory nerve (Chapter 1). Power is tested by measuring resistance to jaw opening, closure and side to side movement. *Motor involvement* is rare but occurs clinically in myasthenia gravis and muscular dystrophy (myotonic and fascioscapular). To test sensation touch the face lightly with cotton wool separately in all three divisions (V1-V3) comparing sides. Only very occasionally is it necessary to test for pain and temperature on the face. Disorders affecting the fifth nerve can arise either centrally in the brainstem or peripherally involving the whole nerve or more commonly in one of its main branches. Causes of central brain stem disorders include stroke and mass lesions. In healthy persons the *jaw jerk* is either minimally present or absent. The jaw jerk may be increased in upper motor neurone disorders affecting the upper brain stem and above e.g. motor neurone disease (MND) and stroke. Disorders affecting the peripheral nerve are mostly caused by *herpes zoster* (Fig. 12.11), trigeminal neuralgia and rarely compression by tumours compressing the nerve e.g. acoustic neuroma. The frequency of herpes zoster is increased in HIV disease (Chapter 8). An absent *corneal reflex* in the presence of normal facial movements (7<sup>th</sup> CN) is a sign of *sensory 5<sup>th</sup> CN (V1) neuropathy*. Patients with

trigeminal neuropathies present mostly with pain or impairment or loss of facial sensation, typically without any loss of power of mastication. Trigeminal neuralgia is the most common clinical disorder affecting the 5<sup>th</sup> CN or its branches (Chapter 15).

### Key points

- sensory involvement is more common than motor in 5th CN neuropathy
- jaw jerk is increased in some UMN lesions
- absent corneal reflex indicates a lesion in either the 5th or the 7th CN
- herpes zoster is the commonest cause of trigeminal neuropathy



**Figure 12.11** Herpes zoster in HIV. Vesicular eruption in V3 division of trigeminal nerve (left).

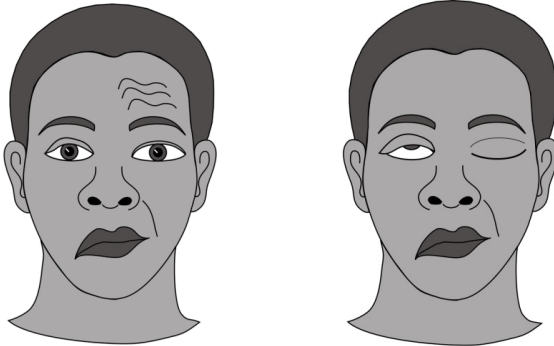## FACIAL NERVE

Facial nerve paralysis is one of the most common cranial nerve disorders. The examination has already been outlined in chapter 1. In brief first inspect the face for asymmetry, loss of normal wrinkling, eye closure, nasolabial fold and decreased facial movement. To demonstrate the facial nerve ask patient to smile (show teeth), close eyes tightly and look up. Facial nerve paralysis may either be central (upper motor neurone) in origin as occurs in *stroke* or peripheral (lower motor neurone) in origin as occurs in *Bell's palsy*. Peripheral facial nerve disorders arise mainly from inflammation, infiltration or compression of the nerve along its course. The main inflammatory causes are Bell's palsy and infections including herpes zoster i.e. Ramsay-Hunt syndrome. The main infiltrative and compression causes include acoustic neuroma, meningioma and diseases affecting the skull base or parotid gland.

## BELL'S PALSY

*Bell's palsy* is the most common disorder of the facial nerve. It is an acute lower motor neurone disorder (LMNL) which is associated with viral infection and facial nerve swelling within the facial canal although its precise cause is not known. It is associated with asymptomatic HIV infection (Chapter 8). It presents as a painless loss of power on one side of the face over 24 hours; there may be an associated ache around the ear at the start which typically clears. The patient becomes very aware of his facial appearance and may have difficulties smiling, speaking or initiating swallowing and closing the eye on the affected side (Fig. 12.12). It affects all the muscles on one side of the face (Fig. 12.13) which distinguishes it from central causes which affect only the lower half of the face. It may occasionally occur bilaterally when the correct

diagnosis can be easily missed (Fig. 12.14) unless it is tested. The main differences between a lower and upper motor neurone lesion are presented in Table 12.7. The weakness usually clears fully without any treatment in the majority >90% of patients within 6 to 12 weeks. However if at onset the paralysis is complete and there is involvement of taste and hearing (increased) then the outlook for a full recovery is worse.



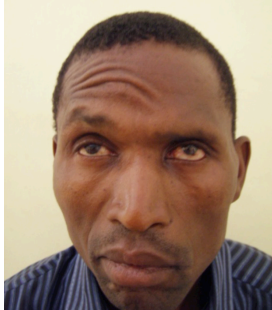Facial nerve palsy right lower motor neurone lesion

Loss of wrinkling of forehead  
Loss of nasolabial fold  
Drooping of the mouth

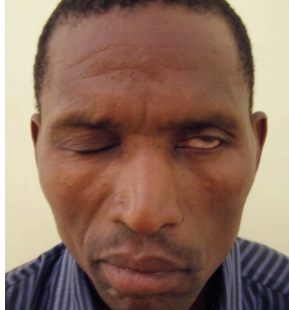Facial nerve palsy, right sided  
(lower motor neurone lesion)  
(during eye closure)  
Failure to close the eye  
Loss of nasolabial fold  
Drooping of the mouth.

Figure 12.12 Lower motor neurone facial nerve palsy (right sided)

Loss of wrinkling



Loss of eye closure

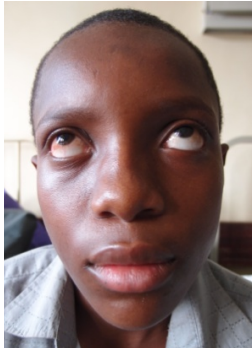


Loss of nasolabial fold & drooping mouth

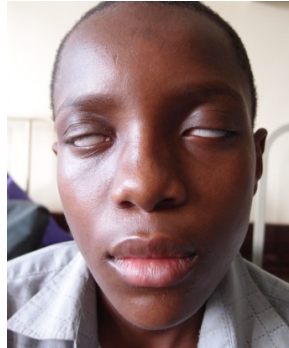

Figure 12.13 Lower motor neurone facial nerve palsy (left sided)

Loss of wrinkling



Loss of eye closure



Loss of smiling

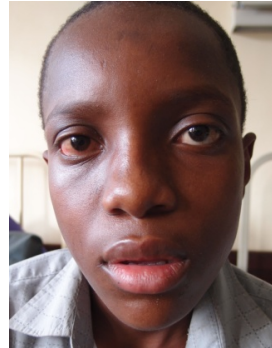

Figure 12.14 Lower motor neurone facial nerve palsies (bilateral)

**Table 12.7** Differences between lower and upper motor neurone facial nerve palsy

Main clinical features	Lower motor neurone lesion	Upper motor neurone lesion
<b>Main Cause</b>	Bell's palsy	stroke
<b>Clinical findings*</b> <i>forehead wrinkling</i>	absent	spared
<i>eye closure</i>	absent	partially spared
<i>movement lower face</i>	absent	absent/decreased
<b>Outcome</b>	90% recover fully	variable

\* may only be partially present in incomplete lesions

## Management

If the patient is seen within 48 to 72 hours of onset then a short course of steroids and antiviral drugs may help to improve outcome. This includes prednisolone 60 mg/po/daily and aciclovir 400 mg/po/tds for a total of 7 days. Prevention of corneal damage during recovery is important. The use of artificial tears and application of a cover patch particularly overnight may be sufficient to prevent the cornea from being damaged before recovery. Glasses with side protection and eye covers may help during the day. Severe cases may need a temporary tarsorrhaphy. Physiotherapy with facial exercises may be helpful to the patient.

### Key points

- Bell's palsy is the most common cause of LMN facial nerve paralysis
- signs are drooping of the corner of the mouth, loss of eye closure & absence of wrinkling
- loss of eye closure and wrinkling distinguish it from an UMN facial nerve lesion
- frequency of Bell's palsy is increased in HIV infection & patients should have a screening HIV test
- recovery occurs in most patients without treatment

## ACOUSTIC NERVE

The eighth nerve or acoustic has two divisions: *cochlear* and *vestibular*. Disorders affecting the *cochlear* division result in difficulties with *hearing* whereas disorders affecting the *vestibular* division result in difficulties with *balance*. The main symptoms of the cochlear division are deafness and tinnitus and the vestibular division are vertigo and loss of balance.

## HEARING

Details concerning the examination of the cochlear division of the acoustic nerve are presented in chapter 1. Bedside tests include asking and checking the patient's ability to hear by whispering about 1 metre away when the other ear is blocked. If hearing is found to be reduced then do the *Rinne* and *Weber* tests. In the Rinne test the beating tuning fork is held first on the mastoid (bone conduction, BC) and then placed just outside the ear (air conduction, AC). In the Weber test the beating tuning fork is placed on the vertex of the head. The possible results of the tuning fork tests are summarized in Table 12.8. The main causes of *deafness* alone are wax in the outer ear, otitis media in the middle ear, presbycusis in the cochlea and diseases affecting the cochlear nerve in the inner ear. Neurological causes of hearing loss include nerve deafness after meningitis, ototoxic drugs e.g. quinine and streptomycin and rare causes such as an acoustic

neuroma. Ménière’s disease is the most common cause of combined deafness and vestibular dysfunction.

**Table 12.8** Possible results of tuning fork tests in deafness

	Rinne (deaf ear)	Weber
<b>Conductive deafness</b>	BC > AC	best in the deaf ear
<b>Sensorineural deafness</b>	AC > BC	best in the non deaf ear

**VERTIGO/DIZZINESS**

Vertigo is an illusion of a sensation of giddiness or spinning during which the patient or more commonly the world outside the patient appears to move. Dizziness is commonly used to describe the unsteady feeling or sensation of vertigo and care must be taken to distinguish it from true vertigo. Vertigo can be caused by either peripheral or central disorders. Diseases affecting the *peripheral vestibular nerve* causing vertigo include viral infections causing acute labyrinthitis, benign paroxysmal positional vertigo (BPPV) and drugs e.g. quinine and streptomycin. *Centrally*, the main cause of *vestibular dysfunction* is ischaemic or vascular. Vertigo of vestibular origin is characteristically paroxysmal and brought on or aggravated by a change in position. This in contrast to vertigo of central origin which is more continuous and is not usually provoked by change in position. The Hallpike’s test (see below) can help to differentiate and distinguish between these two sites. The duration of symptoms depends on the cause and may last from weeks in labyrinthitis to less than a minute in BPPV. Drugs commonly used in the treatment of acute vertigo include betahistine 16 mg/po/tds or prochlorperazine 5 mg/po/tds.

**Ménière’s disease**

This is a disease characterized by intermittent attacks of severe vertigo, tinnitus and deafness. The deafness eventually becomes permanent and the vertigo eventually ceases after years. Management is by decreasing salt intake, thiazide diuretic, and using an antihistamine e.g. betahistine, cinnarizine, cyclizine or prochlorperazine.

**BENIGN PAROXYSMAL POSITIONAL VERTIGO (BPPV)**

*BPPV* is a benign condition characterized by transient vertigo brought on by head movements. The acute vertigo lasts less than a minute but symptoms may persist for weeks or months and may recur. There may be associated nausea and vomiting in severe persistent attacks. It arises mainly from dislocation of otoliths or debris blocking the posterior semicircular canals. Characteristically, a change of head position particularly rolling over in bed or rising suddenly from the lying or seated position provokes an attack. The diagnosis may be confirmed by bedside techniques including *Hallpike’s test*. *Epley’s manoeuvre* can help to disperse the debris.

**Hallpike’s test**

This is a bedside test of vestibular function which is used in patients suspected as having positional vertigo. The test begins with the patient seated upright on the examining couch and is positioned so that when he lies flat his head and neck will extend beyond the examining couch unsupported. Whilst seated the patient is first instructed to turn the head to one side with the eyes looking in the same direction as the head. Whilst maintaining that head position the patient is reassured and instructed to lie flat. The head should now lie about 30 degrees

below the horizontal and now be supported by the examiner's hands. In normal persons there is no nystagmus or vertigo. In vestibular disorders nystagmus and vertigo starts after a delay of a few seconds, and then fatigues and resolves after a number of seconds. This is a positive *Hallpike's test*. After sitting upright the test may be repeated on the other side. In central or brain stem disorders there is usually no delay in the onset of symptoms and signs which are not worsened by change in position and any nystagmus which is present persists.

### Epley's manoeuvre

This involves lying down sideways in the position in which the Hallpike test brings on the vertigo and then rolling over changing sides and remaining sideways there until symptoms subside followed by sitting upright for 30 seconds and then back to the first position. This manoeuvre should be repeated at least 3-4 times daily until symptoms persistently resolve.

### Key points

- disorders of the vestibular division of the 8<sup>th</sup> CN result in difficulties in balance
- symptoms include dizziness, vertigo, tinnitus, nausea, vomiting & ataxia
- main causes are BPPV, vestibular neuronitis & Ménière's disease
- nystagmus provoked by change in position is characteristic of vestibular origin
- relief with antiemetics, antihistamines & positional manoeuvres

## ACCESSORY NERVE

This nerve supplies the *sternomastoid* and *the trapezius muscles* and is responsible for turning and flexing the head and shrugging the shoulders. The clinical examination is done by inspection of the main neck and shoulder muscles for any obvious wasting, fasciculations or hypertrophy and then by opposing each of the main movements, in turn resisting elevation of the shoulders and turning the head (Chapter 1). The main neurological disorders affecting these movements are diseases of muscle and neuromuscular junction including myopathies, polymyositis, dystrophies and myasthenia gravis (Chapter 13). Management is by treatment of the underlying disorder.

## GLOSSOPHARYNGEAL, VAGUS AND HYPOGLOSSAL NERVES

These cranial nerves supply the mouth, throat and tongue for the main functions of speech and swallowing. The *glossopharyngeal* is sensory to the posterior one third of tongue and the pharynx and middle ear whereas the *vagus* is motor to the muscles of the palate, pharynx and larynx. Their joint function is tested by inspecting the uvula at rest, getting the patient to say "Aah" and testing the gag reflex. The *hypoglossal* nerve is motor to the muscles of the tongue and is examined by inspecting the tongue at rest, and on repeated protrusion in and out. If an abnormality is still suspected the movements and strength of the tongue can be further assessed by asking the patient to push his tongue into his inside cheek against your thumb outside opposing the movement. The pharynx and larynx can be assessed functionally by checking the patient's ability to generate a normal cough and swallow a cup of water normally. The larynx can be visualized by laryngoscope but this requires an ENT specialist.

The lower cranial nerves are commonly involved together in diseases and their joint impairment results in a significant loss of function in the mouth and bulbar area. If the site of the lesion is



a lower motor neurone, then the disorder is termed a bulbar palsy and if the site of the lesion is an upper motor neurone, it is termed a pseudobulbar palsy. The main symptoms common to both types of disorders are difficulty speaking (dysarthria) and swallowing (dysphagia) which is frequently progressive depending on the aetiology. A lower motor neurone lesion results in wasting and fasciculation of the tongue and a reduced or absent gag reflex. There is deviation of the tongue to affected side if it's unilateral. An upper motor neurone lesion results in spasticity with a contracted immobile tongue and an increased gag reflex. The main neurological causes of a bulbar palsy are motor neurone disease (MND) and myasthenia gravis and of pseudobulbar palsy are stroke and MND. The main non neurological cause is local malignancy. Emotional lability is a feature in patients with a pseudobulbar palsy. Management is the treatment of the underlying disorder.

### Key points

- disorders of the lower cranial nerves present with difficulties with speaking & swallowing
- they are classified as bulbar (LMNL) or a pseudo bulbar (UMNL)
- main neurological disorders causing these are stroke, MND & myasthenia gravis
- the differential diagnosis includes local malignancy

### Selected references

- Azonobi IR, Olatunji FO, Addo J. *Prevalence and pattern of strabismus in Ilorin*. West Afr J Med. 2009 Jul-Aug;28(4):253-6.
- Bourne RR, Dolin PJ, Mtanda AT, Plant GT, Mohamed AA. *Epidemic optic neuropathy in primary school children in Dar es Salaam, Tanzania*. Br J Ophthalmol. 1998 Mar;82(3):232-4.
- Bowman RJ, Wedner S, Bowman RF, Masanja H, Bunce C, Wood ML, et al. *Optic neuropathy endemic in secondary school children in Dar es Salaam, Tanzania*. Br J Ophthalmol. 2010 Feb;94(2):146-9.
- Dalmar AA, Hodson KE, Plant GT. *Epidemic optic neuropathy is evident in the Somalian population*. J Neuroophthalmol. 2011 Jun;31(2):127-30.
- Dolin PJ, Mohamed AA, Plant GT. *Epidemic of bilateral optic neuropathy in Dar es Salaam, Tanzania*. N Engl J Med. 1998 May 21;338(21):1547-8.
- Fuller Geraint, *Neurological examination made easy*, Churchill Livingstone, 3<sup>rd</sup> edition 2004.
- Ginsberg Lionel, *Neurology, Lecture Notes*, Blackwell Publishing 8<sup>th</sup> edition 2005.
- Harrison Michael, *Neurological Skills, A guide to examination and management in Neurology*, Butterworth's 1<sup>st</sup> edition 1987.
- Komolafe MA, Fatusi OA, Alatise OI, Komolafe EO, Amusa YB, Adeolu AA, et al. *The role of human immunodeficiency virus infection in infranuclear facial paralysis*. J Natl Med Assoc. 2009 Apr;101(4):361-6.
- Odebode TO, Ologe FE. *Facial nerve palsy after head injury: Case incidence, causes, clinical profile and outcome*. J Trauma. 2006 Aug;61(2):388-91.
- Omoti AE, Waziri-Erameh MJ. *Pattern of neuro-ophthalmic disorders in a tertiary eye centre in Nigeria*. Niger J Clin Pract. 2007 Jun;10(2):147-51.
- Pokroy R, Modi G, Saffer D. *Optic neuritis in an urban black African community*. Eye (Lond). 2001 Aug;15(Pt 4):469-73.
- Turner, Bahra, Cikurel, *Neurology, Crash Course*, Elsevier Mosby 2<sup>nd</sup> edition 2006.
- Tinley C, Grötte R. *Comitant horizontal strabismus in South African black and mixed race children--a clinic-based study*. Ophthalmic Epidemiol. 2012 Apr;19(2):89-94
- van Well GT, Paes BF, Terwee CB, Springer P, Roord JJ, Donald PR, et al. *Twenty years of pediatric tuberculous meningitis: a retrospective cohort study in the western cape of South Africa*. Pediatrics. 2009;123(1):e1-8.